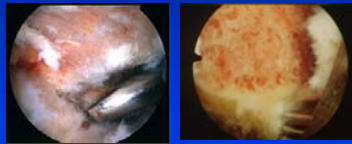


## TECHNIQUE OF ARTHROSCOPIC SUBACROMIAL DECOMPRESSION AND DISTAL CLAVICLE EXCISION




C.H.U. PARIS-OUEST



## INSTRUMENTATION

- CANNULAS
  - NOT NECESSARY
- CAMERA
- POWERED SYSTEM
- FLOW SYSTEM
  - SYSTOLIC BLOOD PRESSURE < 100
  - SALINE MEDIUM

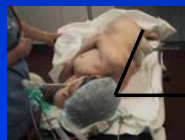
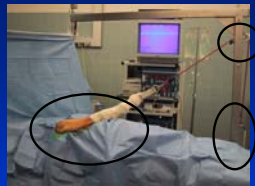
C.H.U. PARIS-OUEST



## PATIENT SETTING

- LATERAL DECUBITUS
- HORIZONTALIZATION OF THE GLENOID FOSSA
- ABDUCTION MINIMAL
- PULLEY
- TRACTION < 3 kg
- CONVERSION TO OPEN
  - THEORETICAL

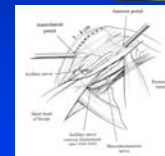
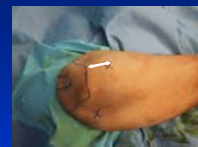

C.H.U. PARIS-OUEST



## SUBACROMIAL BURSOSCOPY

- SAME SKIN PORTAL
  - TWO IS ENOUGH
- BREAK ADHESIONS
- CREATE A SPACE
  - ROOM WITH A VIEW

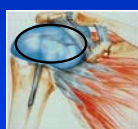
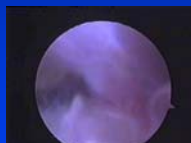
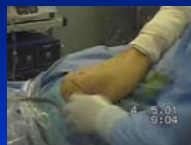

C.H.U. PARIS-OUEST



## SUBACROMIAL BURSOSCOPY

- AVOID ROTATOR CUFF
- HIT THE POSTERIOR ACROMION AND SLIDE UNDER
- FEEL THE CA LIGAMENT
- THE ROOM IS ANTERIOR

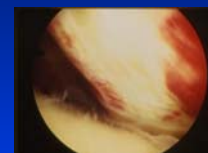
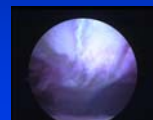

C.H.U. PARIS-OUEST



## SUBACROMIAL BURSOSCOPY

- SUBACROMIAL EXPLORATION
- PREOP INJECTIONS
- IMPINGEMENT SIGN
  - COPELAND



C.H.U. PARIS-OUEST



## SUBACROMIAL DECOMPRESSION

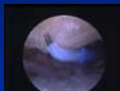
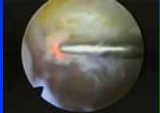

- CA LIGAMENT DETACHEMENT
- NEEDLES ELLMAN
- BEGINNING



C.H.U. PARIS-OUEST

## SUBACROMIAL BURSOSCOPY




- BLEEDING CONTROL
- BLOOD PRESSURE / PUMP
- CAUTERY
  - ARTHROSCOPIC BOVE
  - RF SYSTEM
  - LASER
- START BEFORE BLEEDING OCCURS

C.H.U. PARIS-OUEST

## SUBACROMIAL DECOMPRESSION




- AS DESCRIBED BY NEER
- CA LIGAMENT DETACHEMENT

C.H.U. PARIS-OUEST

## SUBACROMIAL DECOMPRESSION

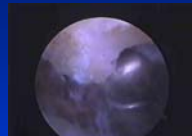

- CA LIGAMENT DETACHEMENT
- BLEEDING CONTROL
- CAUTERY
- COAGULATION MODE FOR RF

C.H.U. PARIS-OUEST

## SUBACROMIAL DECOMPRESSION

- ACROMIOPLASTY
- FLAT ACROMION

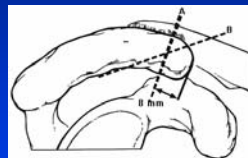




LEAVE THE ANTERIOR PERIOSTEUM INFERIOR AND ANTERIOR BONY RESECTION

C.H.U. PARIS-OUEST

## SUBACROMIAL DECOMPRESSION

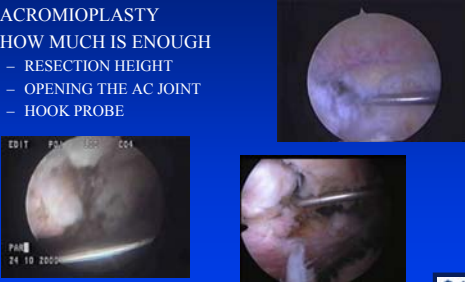
- FLAT ACROMION

C.H.U. PARIS-OUEST

### SUBACROMIAL DECOMPRESSION

- ACROMIOPLASTY
- HOW MUCH IS ENOUGH
  - RESECTION HEIGHT
  - OPENING THE AC JOINT
  - HOOK PROBE



CHU. PARIS-OUEST

### DISTAL CLAVICLE RESECTION

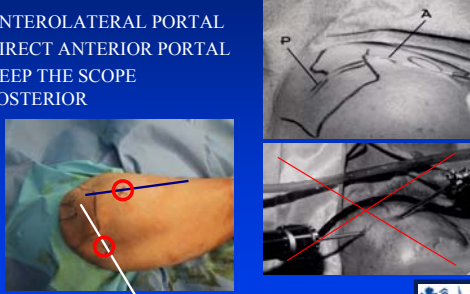
- ISOLATED OR ASSOCIATED TO ACROMIOPLASTY
- SAME POSTERIOR APPROACH FOR THE SCOPE
- SKIN LANDMARK
- NEEDLE



CHU. PARIS-OUEST

### DISTAL CLAVICLE RESECTION

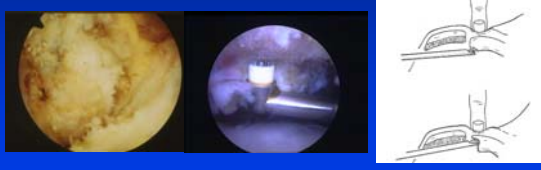
- ANTEROLATERAL PORTAL
- DIRECT ANTERIOR PORTAL
- KEEP THE SCOPE POSTERIOR



CHU. PARIS-OUEST

### DISTAL CLAVICLE RESECTION

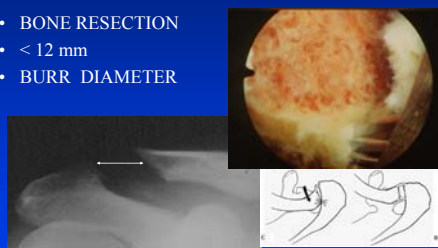
- PRESSURE ON THE DISTAL CLAVICLE
- PRESERVE THE UPPER PART OF THE CAPSULE
- RF DEVICE



CHU. PARIS-OUEST

### DISTAL CLAVICLE RESECTION

- BONE RESECTION
- < 12 mm
- BURR DIAMETER



CHU. PARIS-OUEST

### THANK YOU



CHU. PARIS-OUEST