

ARTHROSCOPIE DU POIGNET :

Intérêt thérapeutique à propos de 1000 cas

X.
Martinache
(Reims)



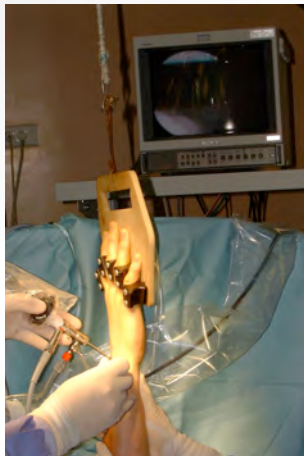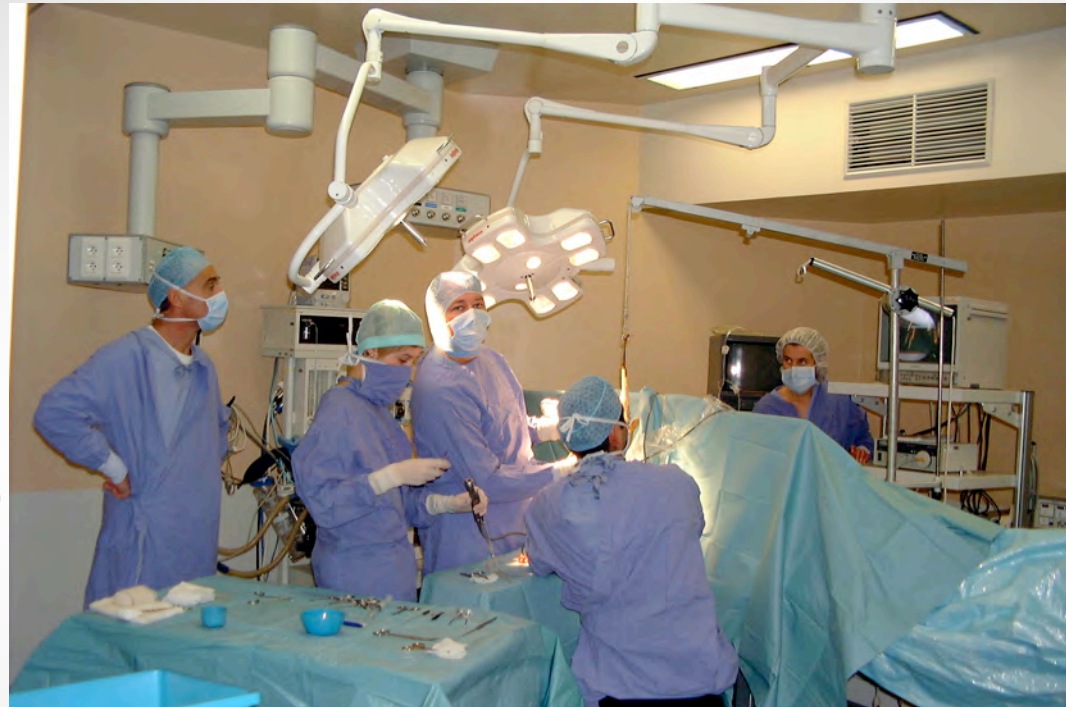HISTORIQUE

- Watanabe 1972 (japon)
- Hempfling 1983 (germany)
Whipple 1985 (USA)
- 1985-1990
Osterman (USA)
Bour (France)
Pederzini (Italie)
Saffar, Mathoulin (France)
- 1990 – 2000
Fontes (France), Doi (japon)
Luchetti (Italie), Geissler (USA)
Lindau (Suède), De Smet (Belgique)
Ho (Chine)
Dumontier Leclercq Mathoulin



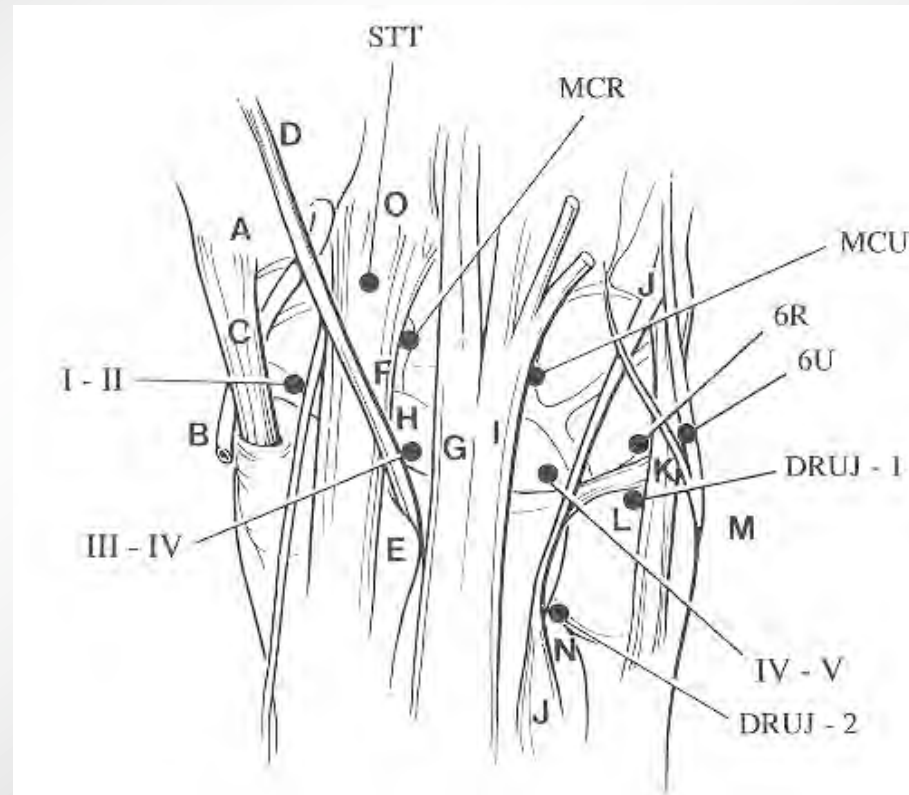
EQUIPEMENT

- Caméra
- Source lumineuse
- Moniteur vidéo
- Système de traction
- Optique
- Système d'irrigation
- Instruments adaptés

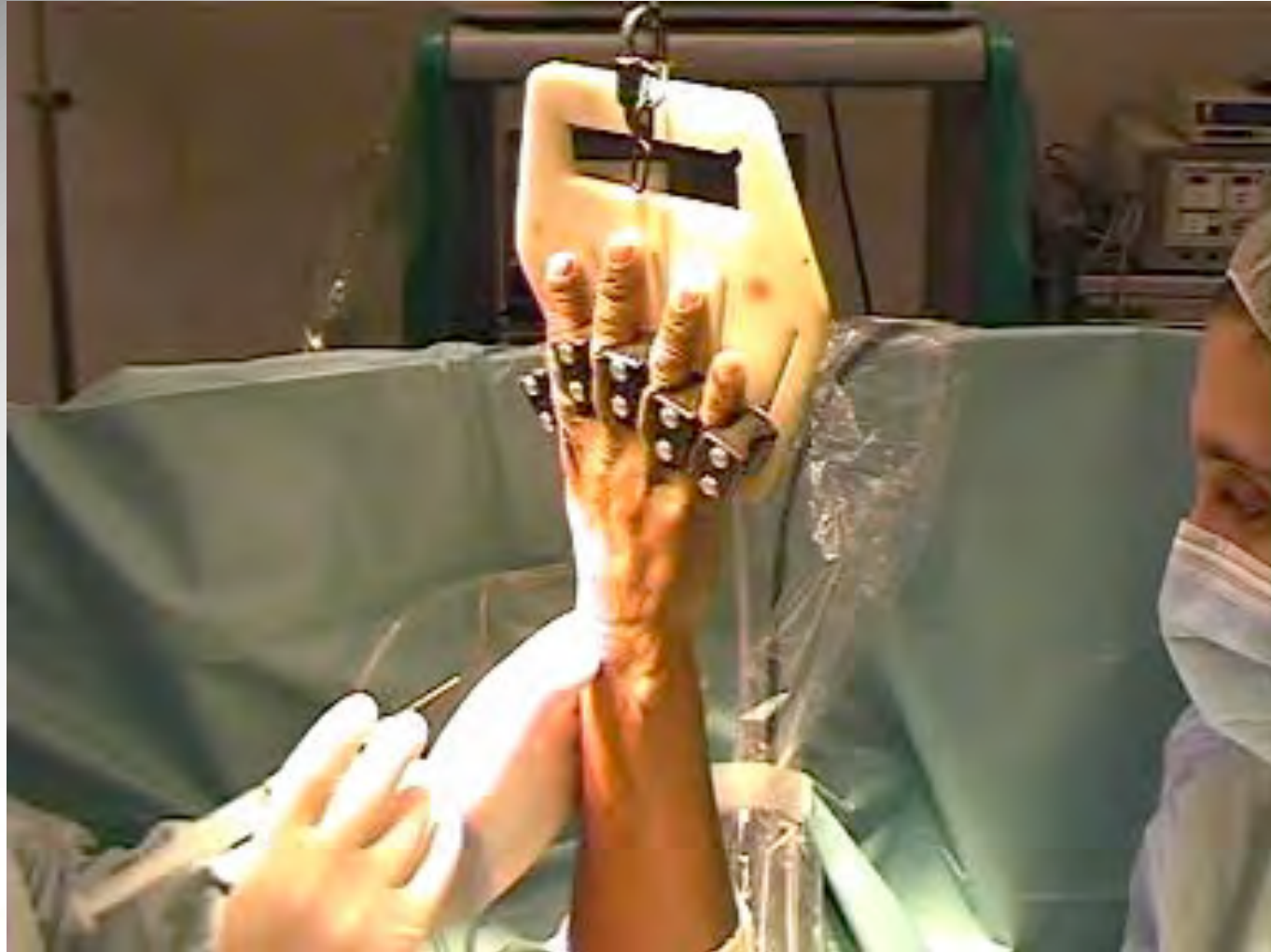

Voies d'abord –Porte d'entrée

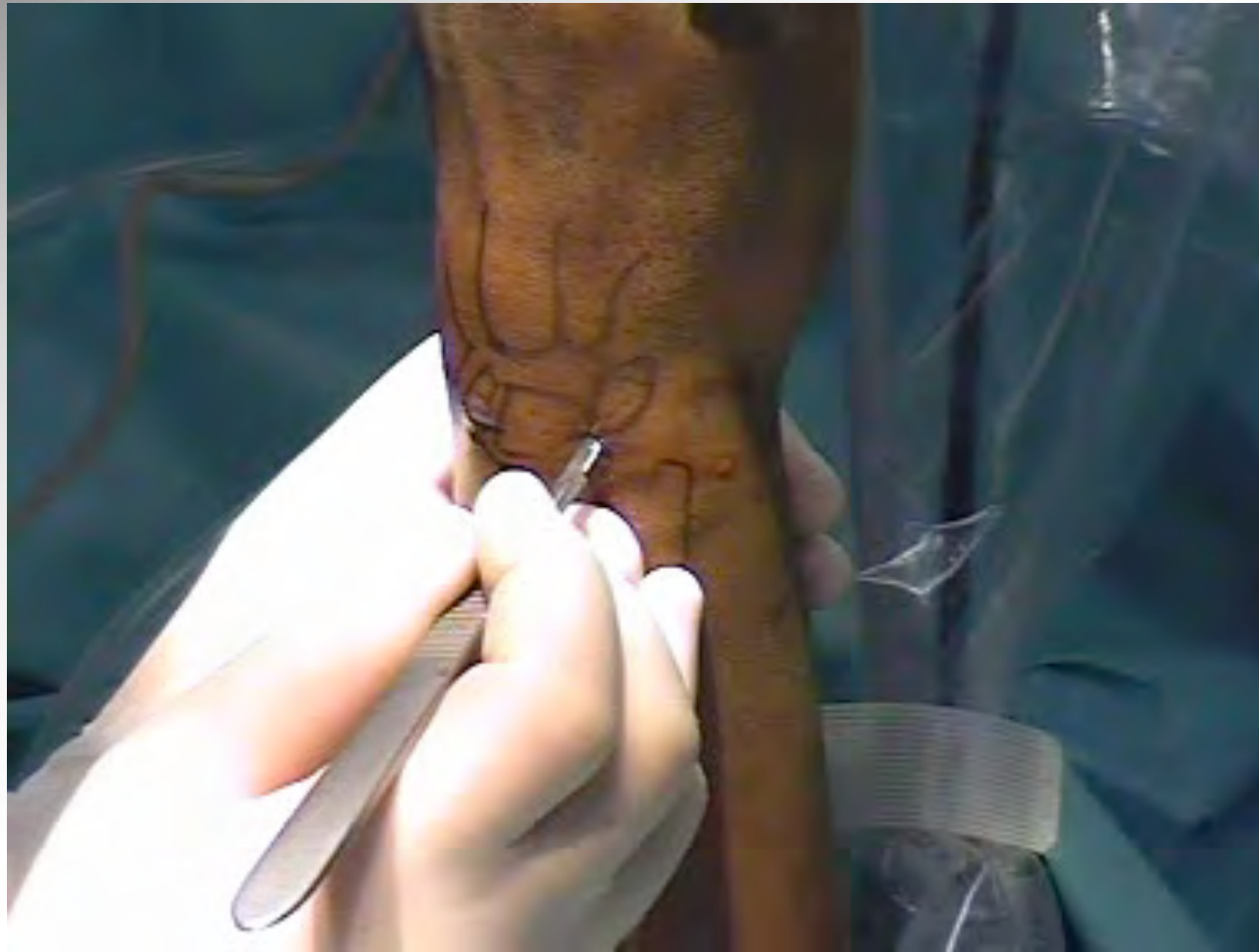- Radiocarpienne
- Médiocarpienne
- Radio-ulnaire inférieure



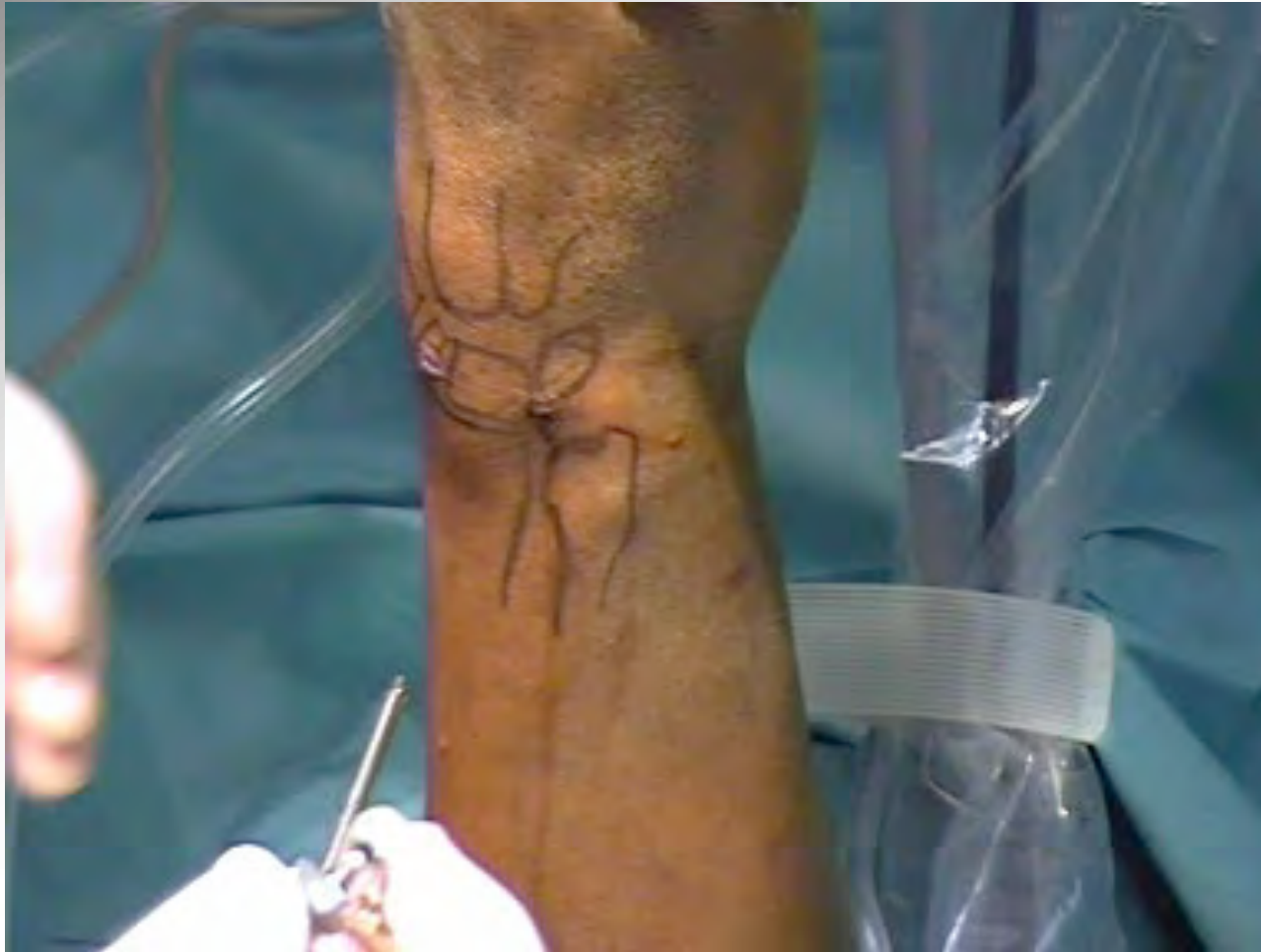Injection d'une solution saline



Lame de bistouri N° 15



Canule avec trocart avant l'optique

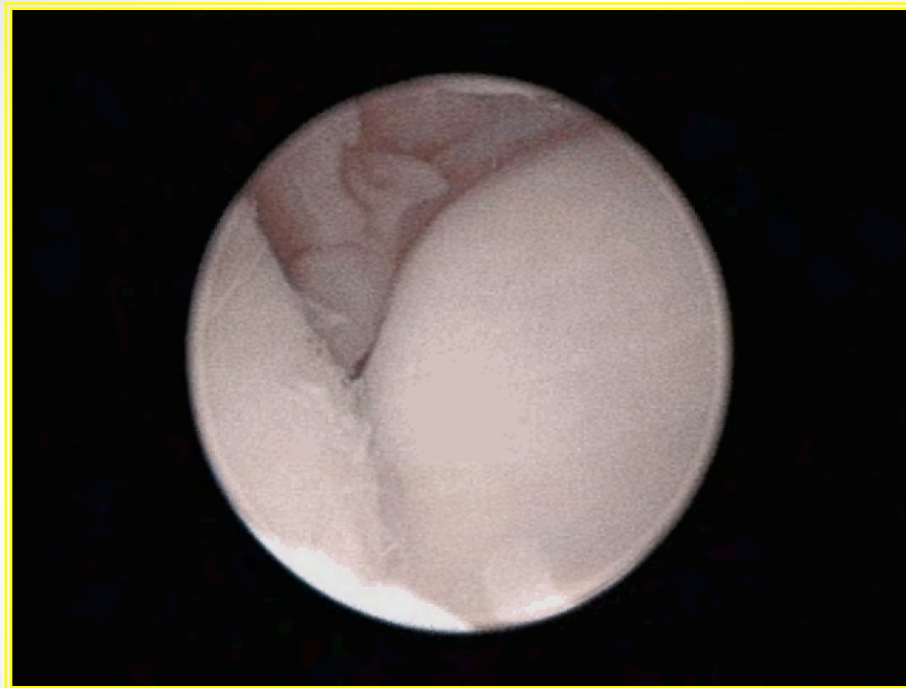
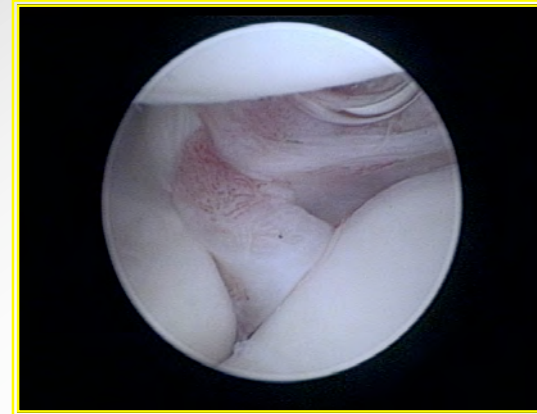
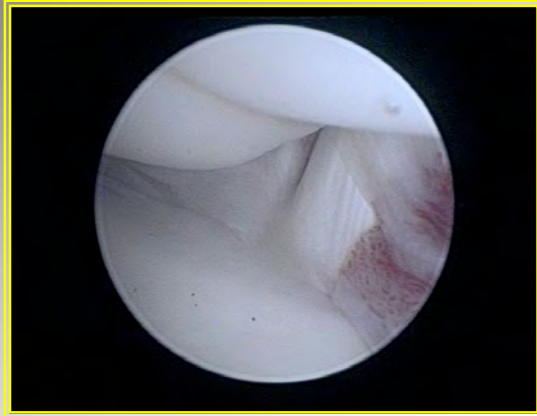


Bilan diagnostique

- Radiocarpien avant médiocarpien
- Coté radial avant ulnaire
- Distal avant proximal
- Palmaire avant dorsal
- Ligaments avant cartilage



Articulation médiocarpienne droite



Intérêt Thérapeutique :

Absence de geste (4%)

Aide aux traitements des fractures (7%)

Lésions du ligament triangulaire (17%)

Lésions des ligaments intrinsèques (21%)

Ectomie (13%)

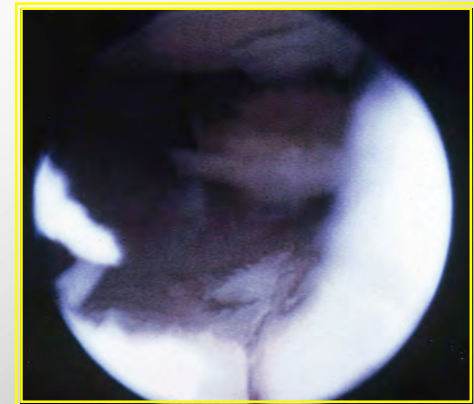
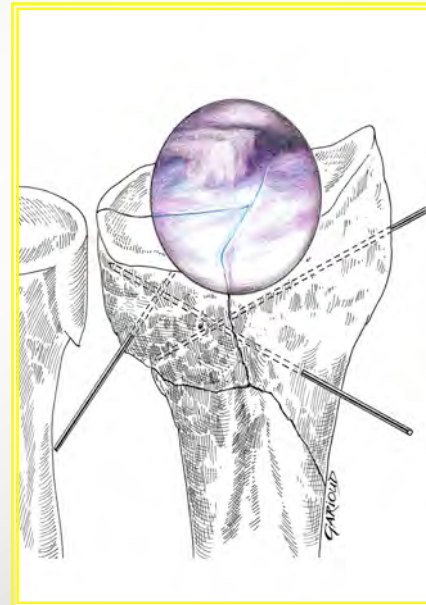
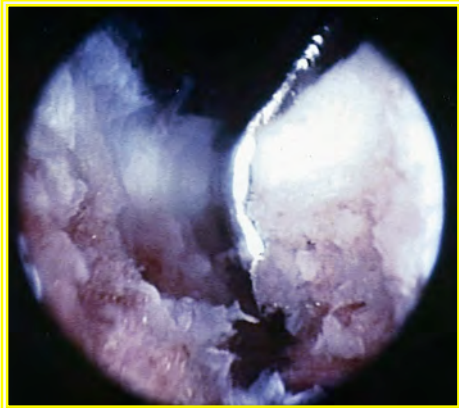
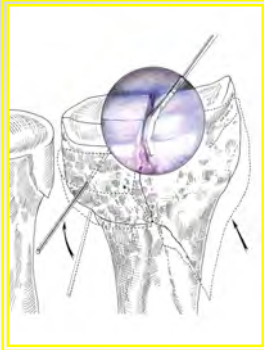
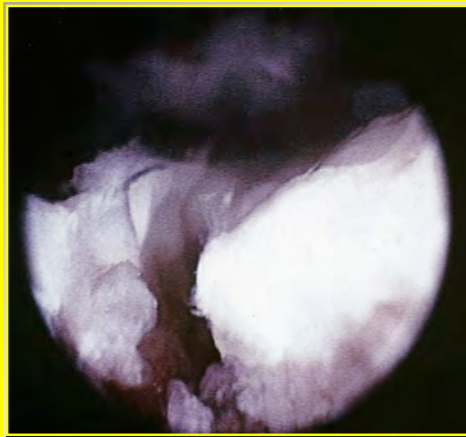
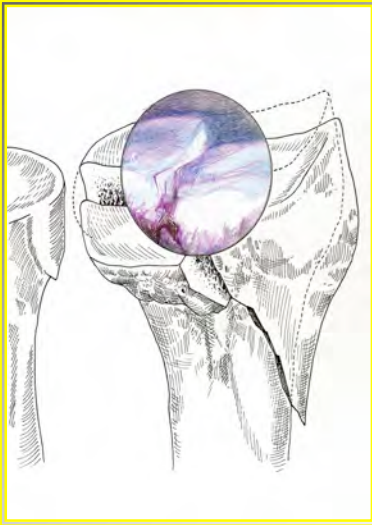Excision des kystes synoviaux (21%)

Prothèses partielles (2,5%)

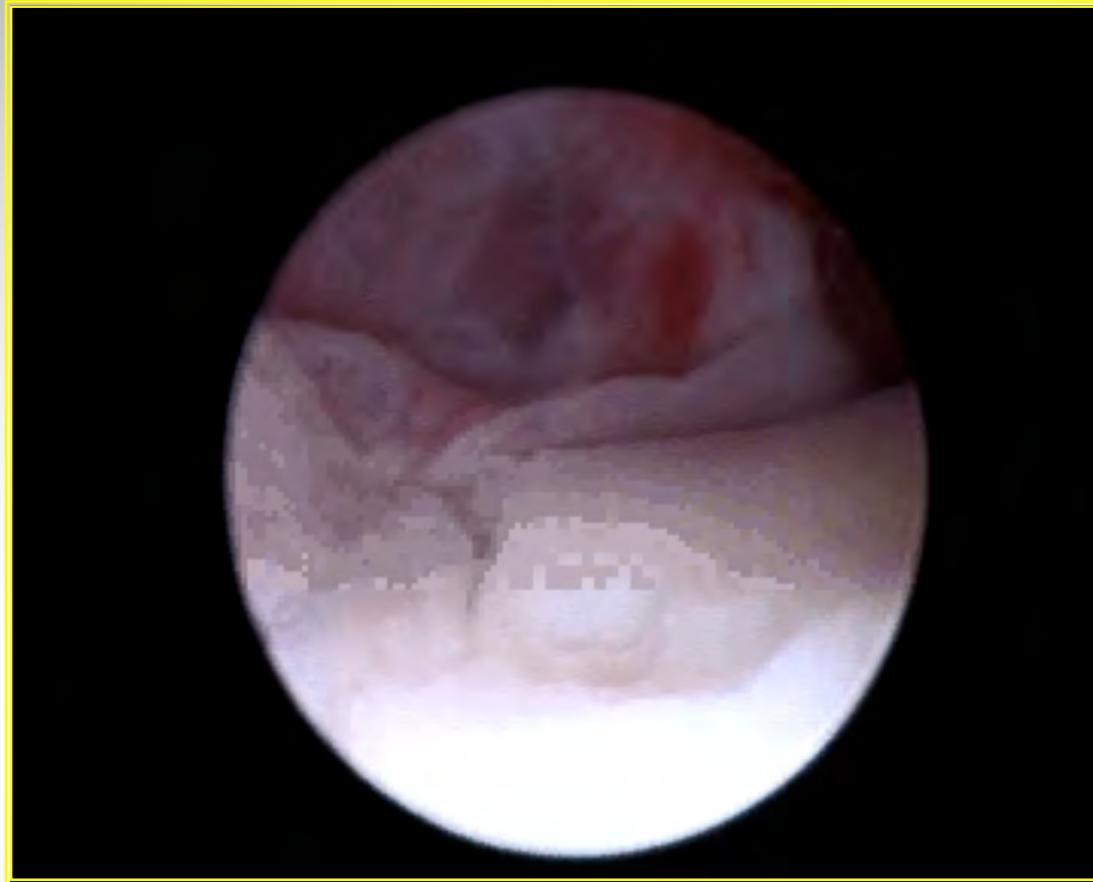
Autres (Synovectomie, arthrolyses...) (14,5%)



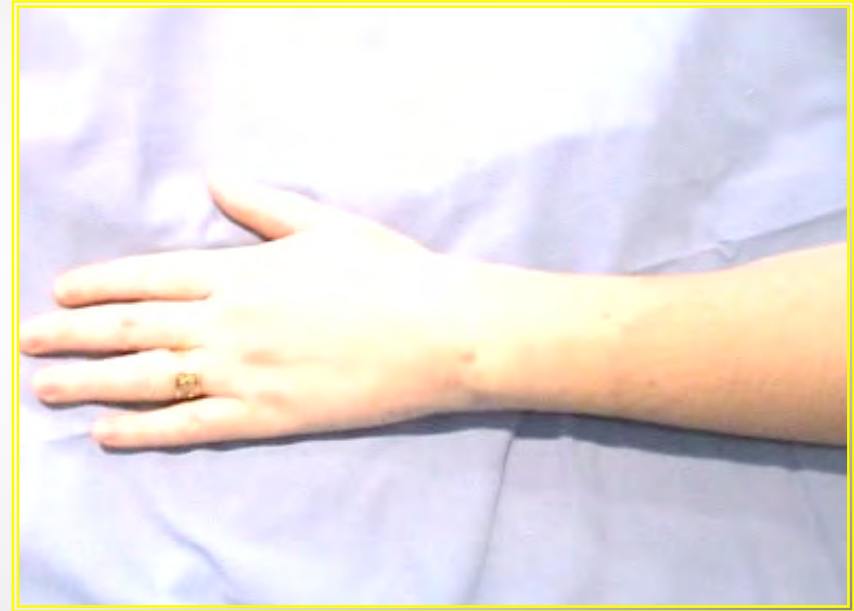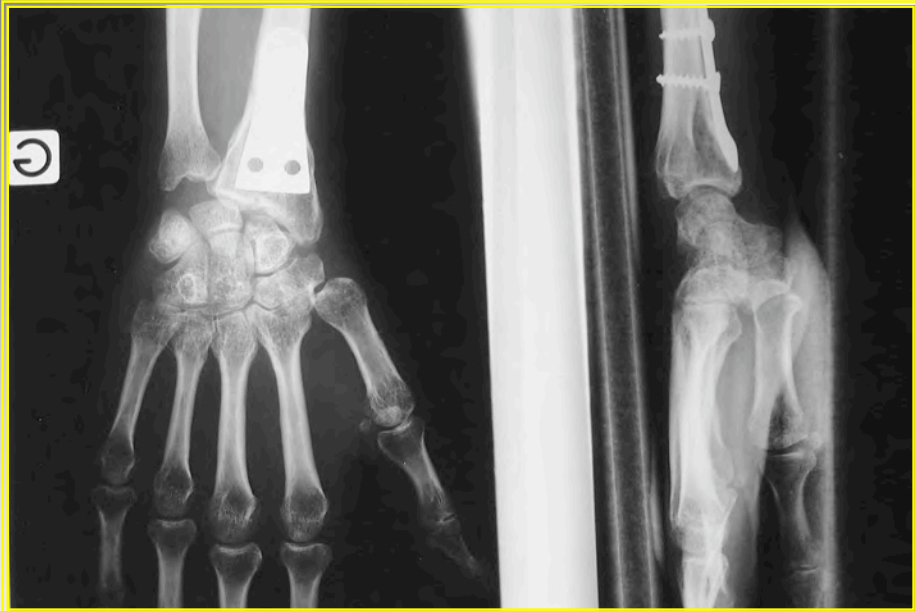Assistance pour le traitement des fractures articulaires du radius



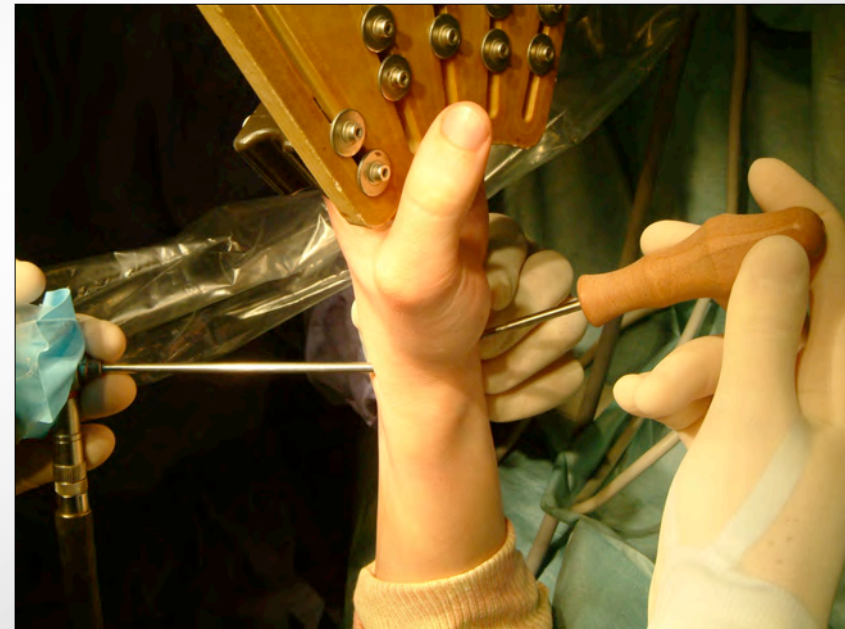
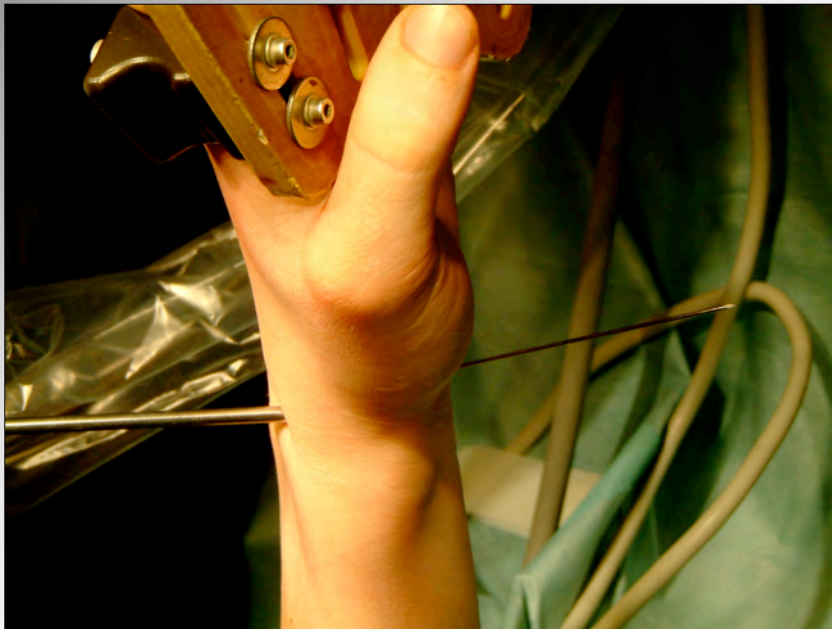
Assistance pour le traitement des fractures articulaires du radius



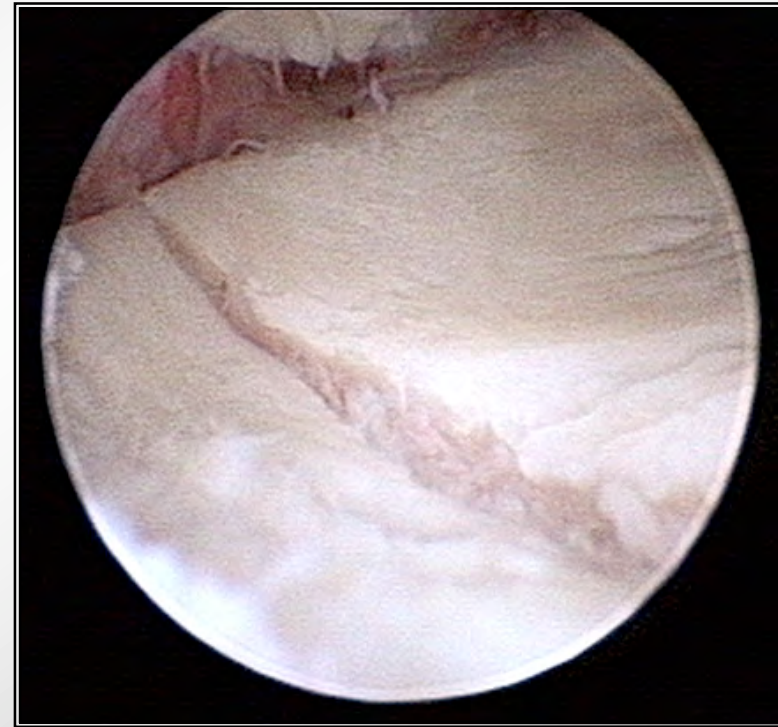
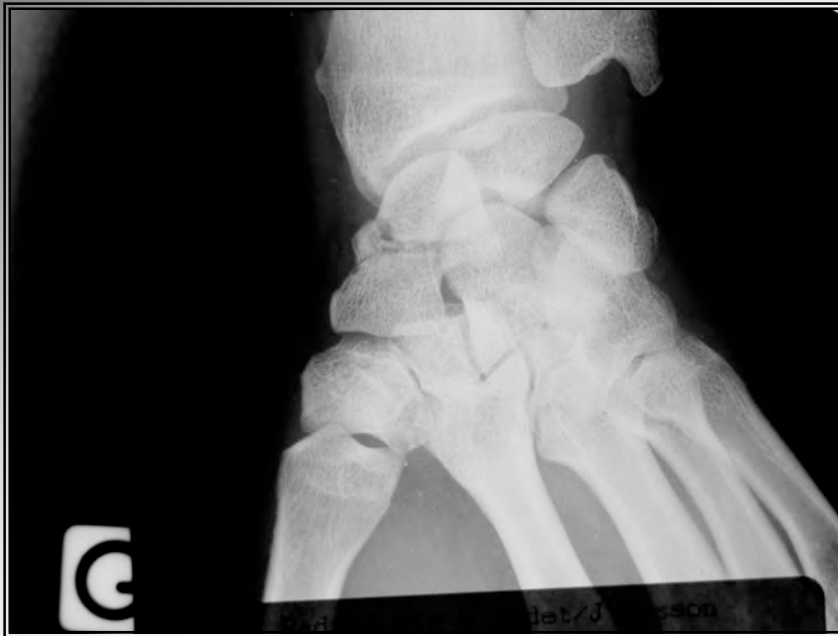Assistance pour le traitement des fractures articulaires du radius



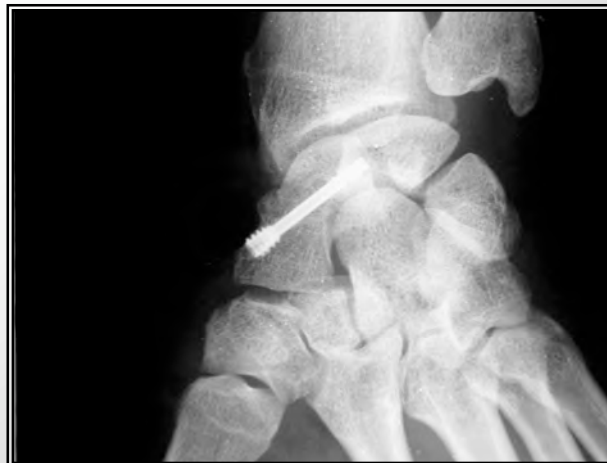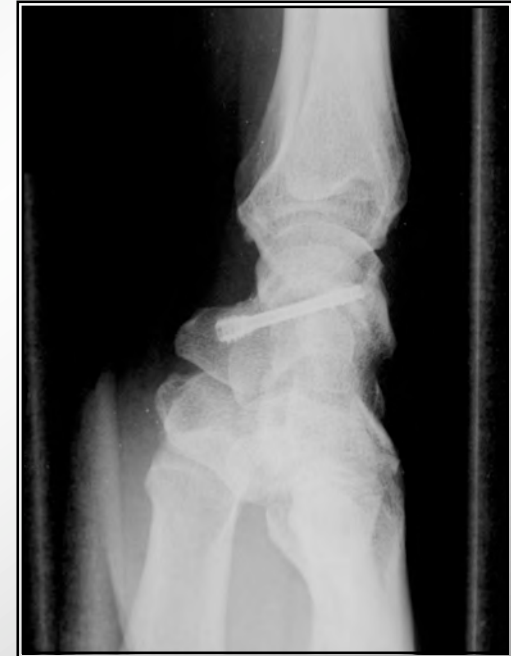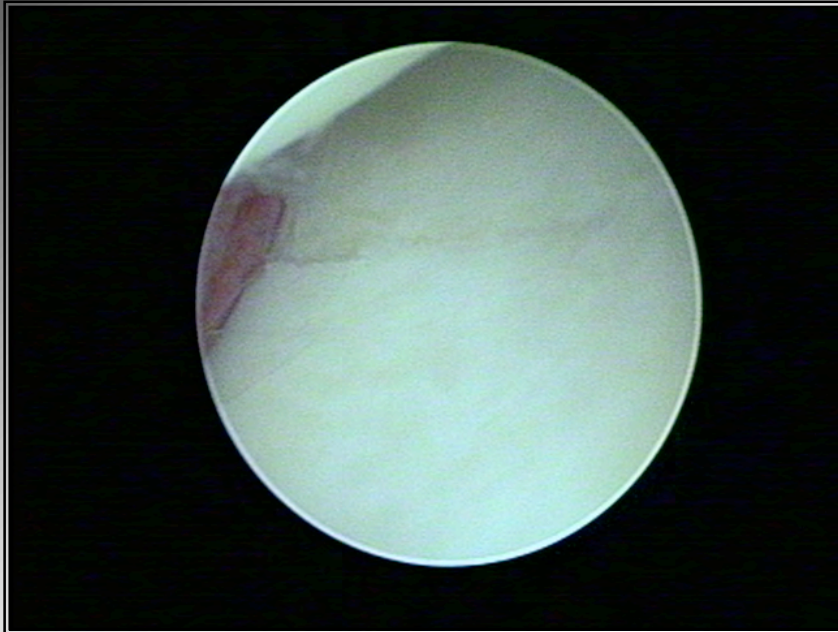
Assistance pour le traitement des fractures du scaphoïde



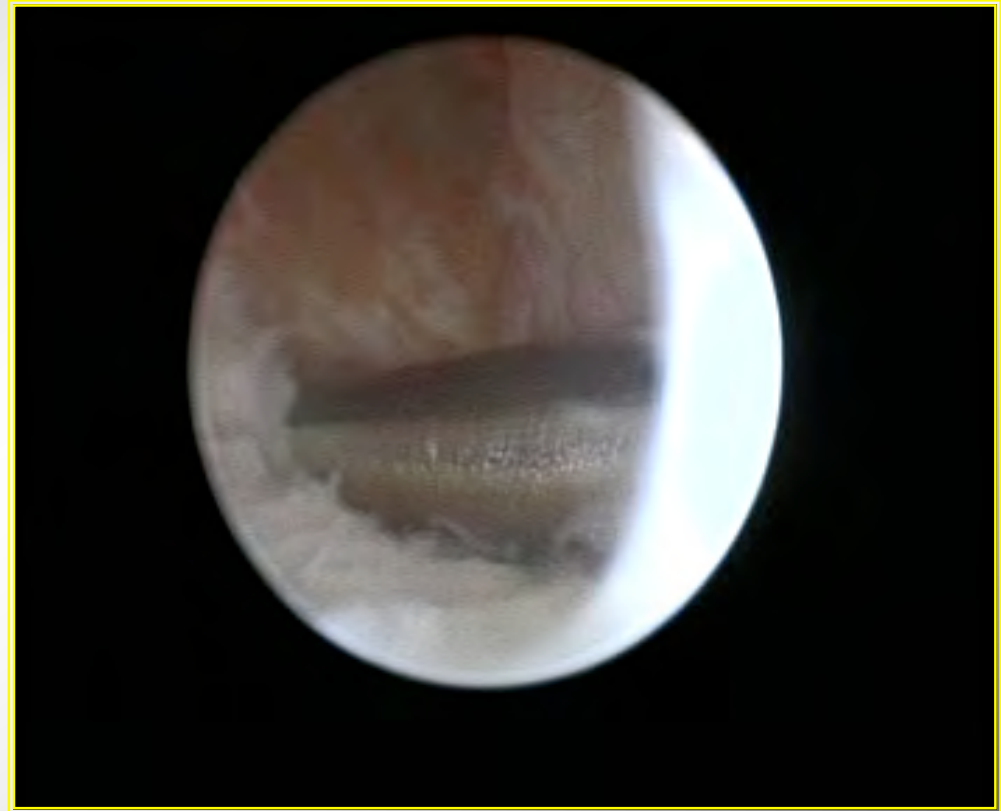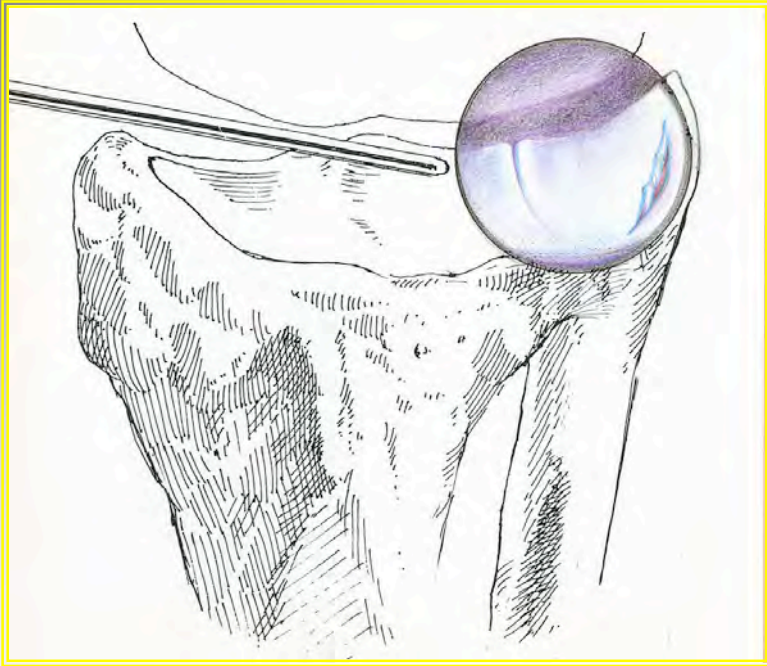
Assistance pour le traitement des fractures du scaphoïde



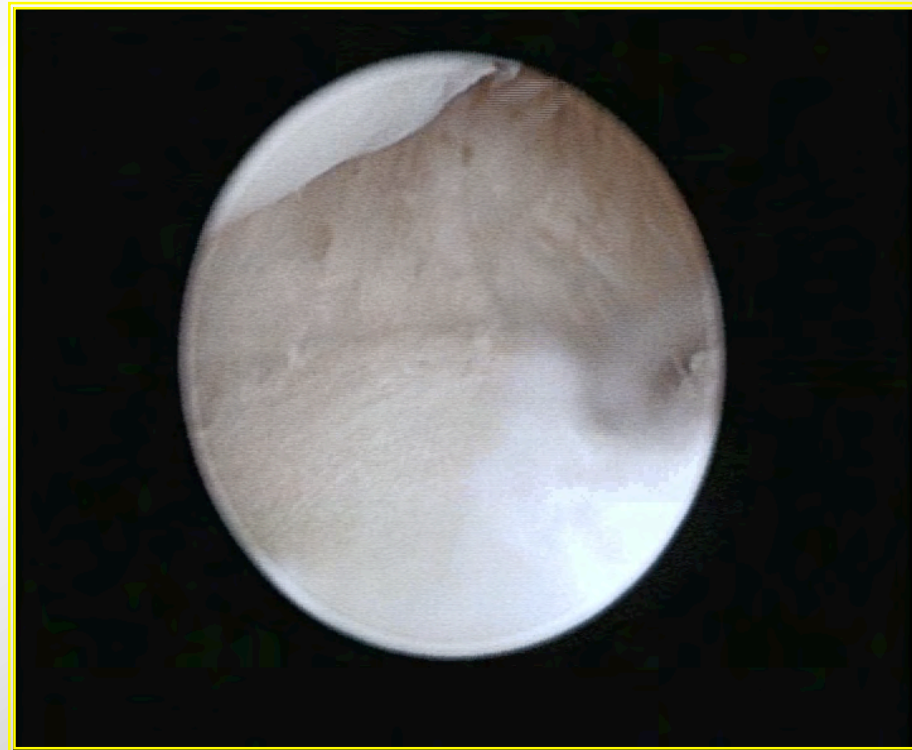
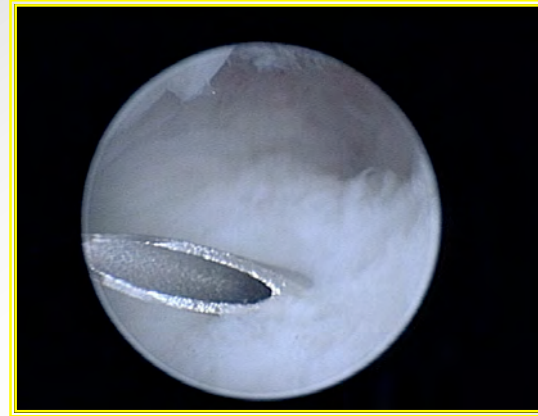
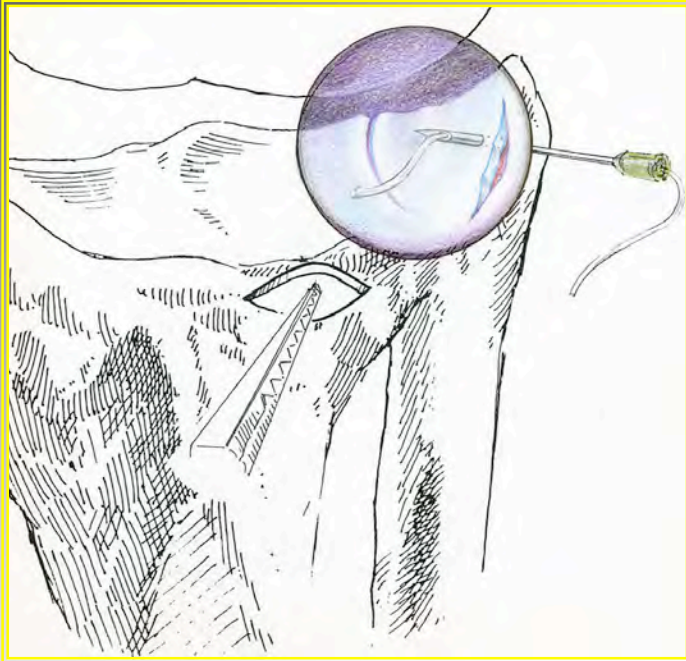
Assistance pour le traitement des fractures du scaphoïde



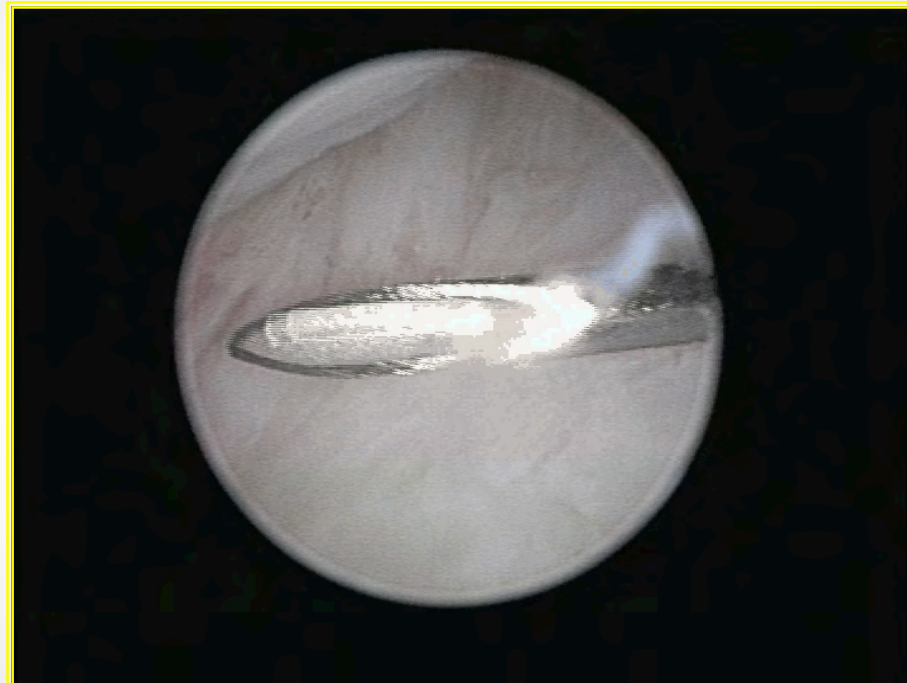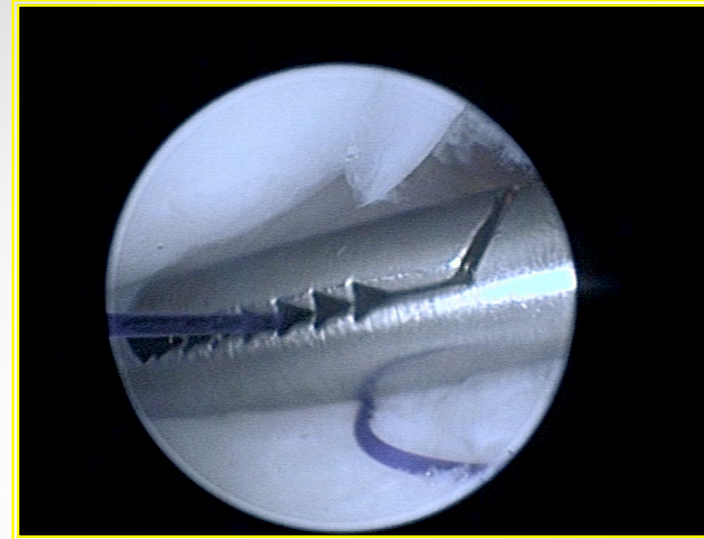
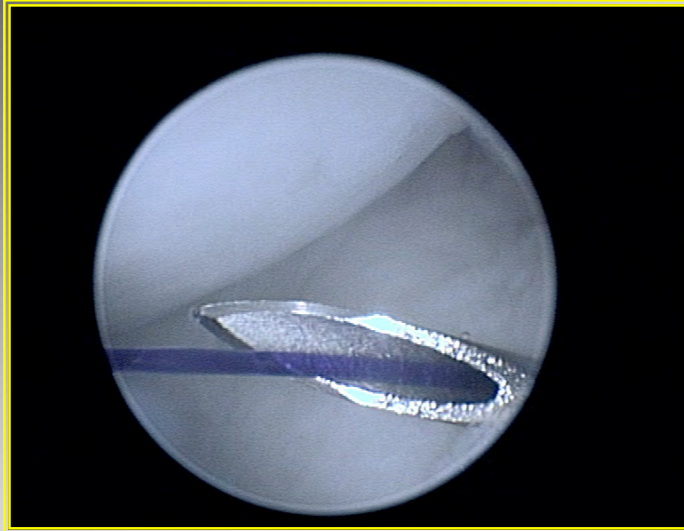
Lésions du ligament triangulaire



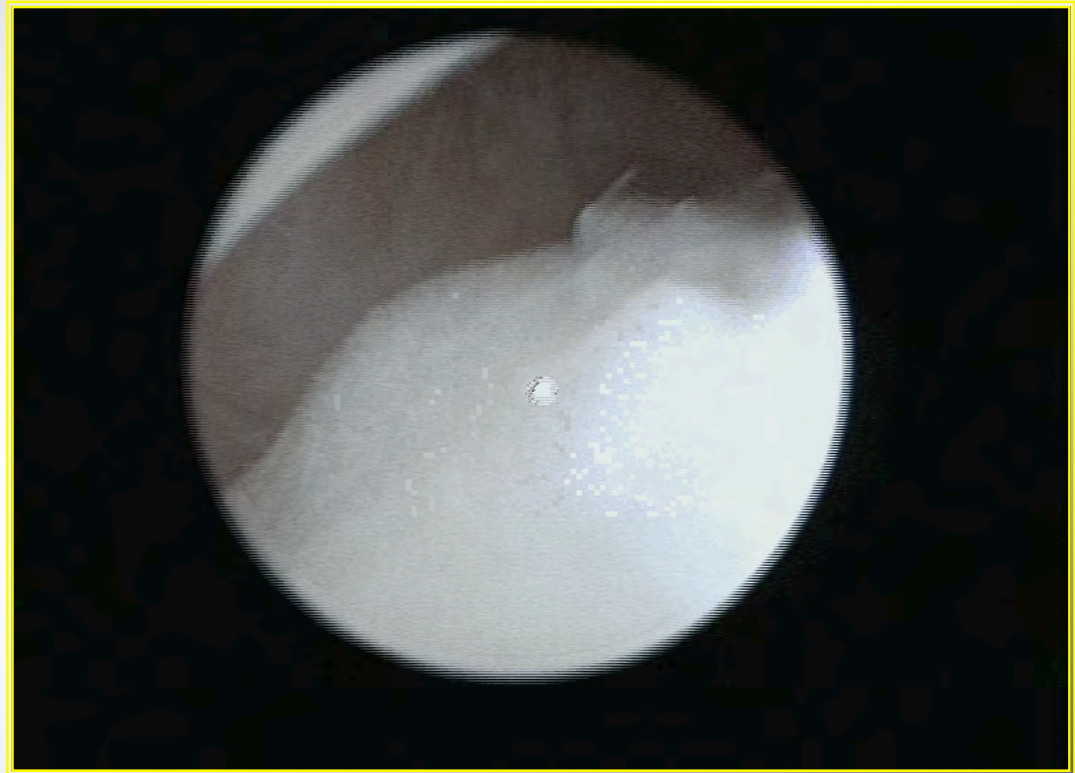
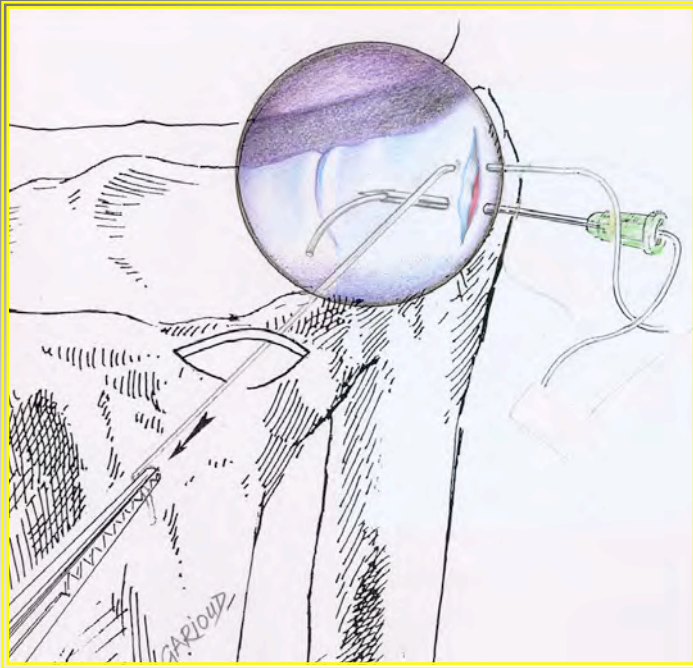
Lésions du ligament triangulaire



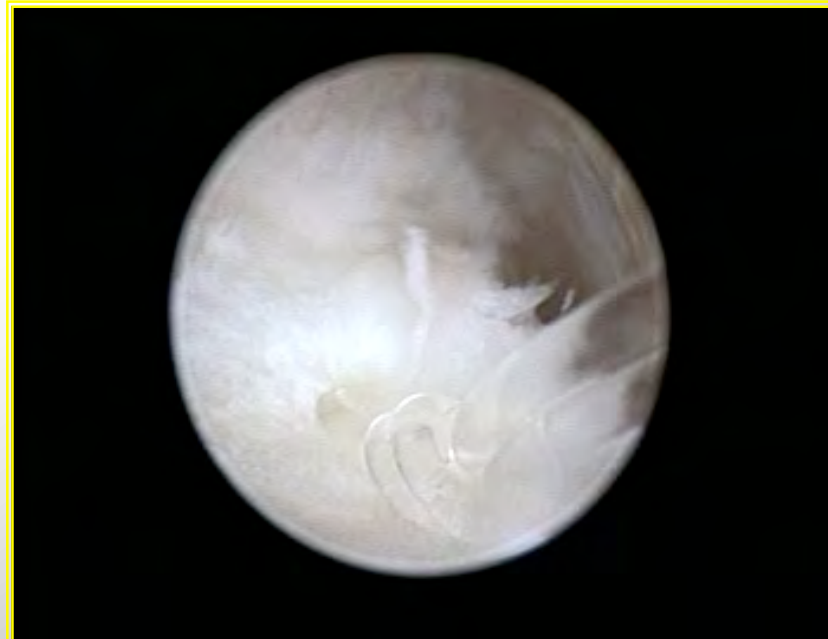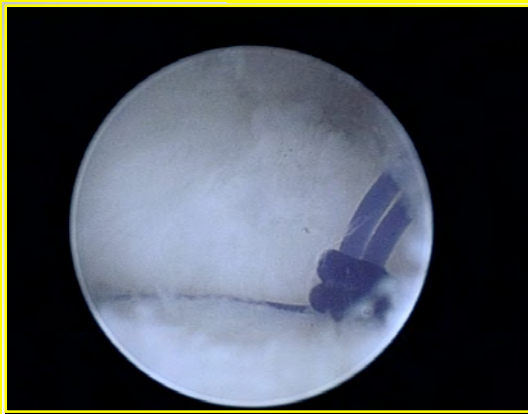
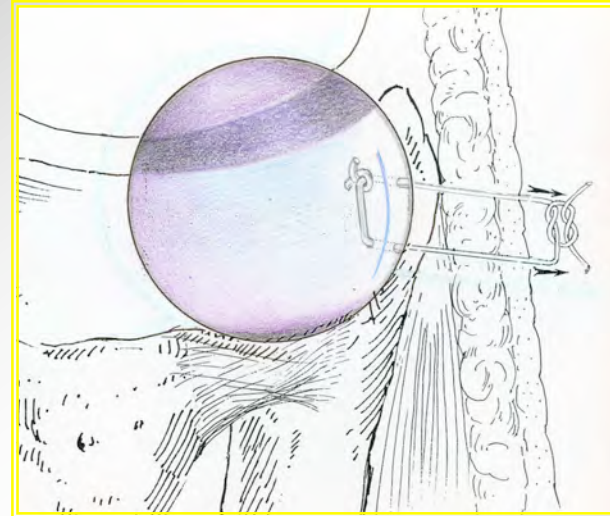
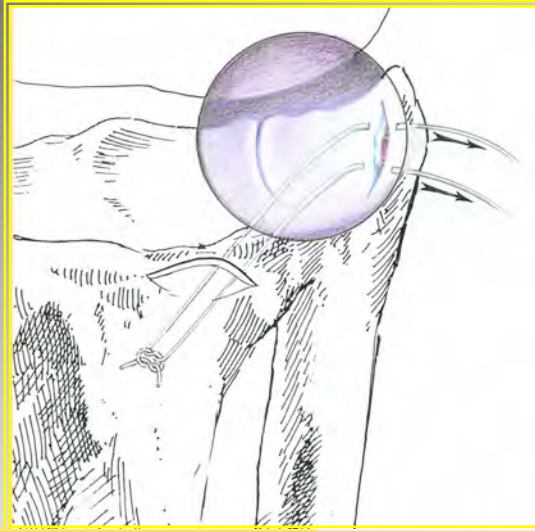
Lésions du ligament triangulaire



Lésions du ligament triangulaire

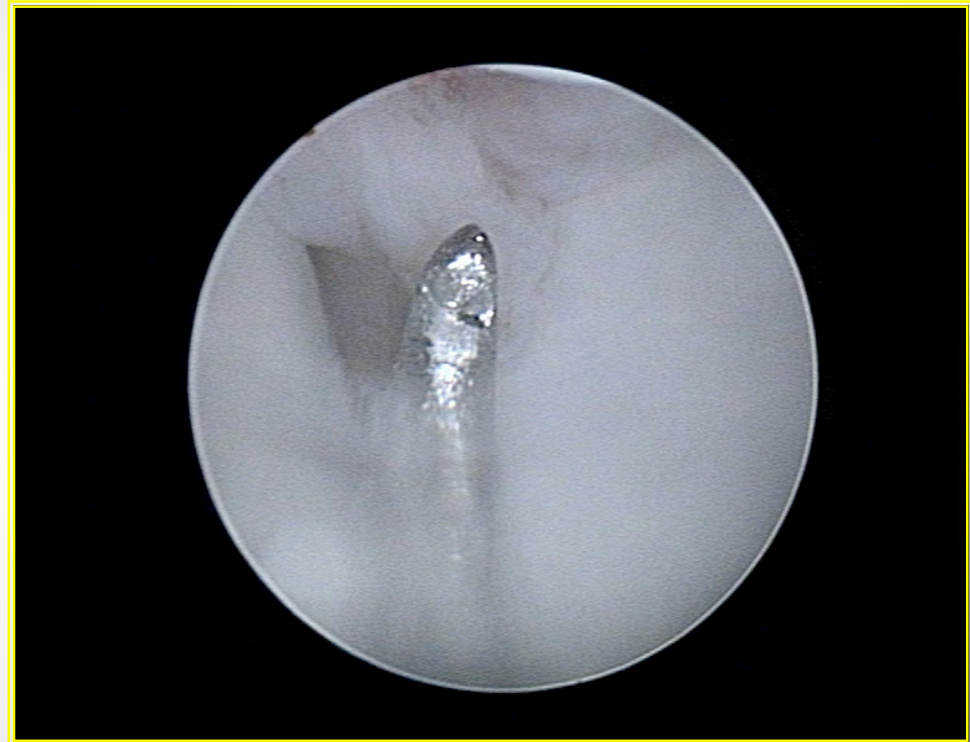
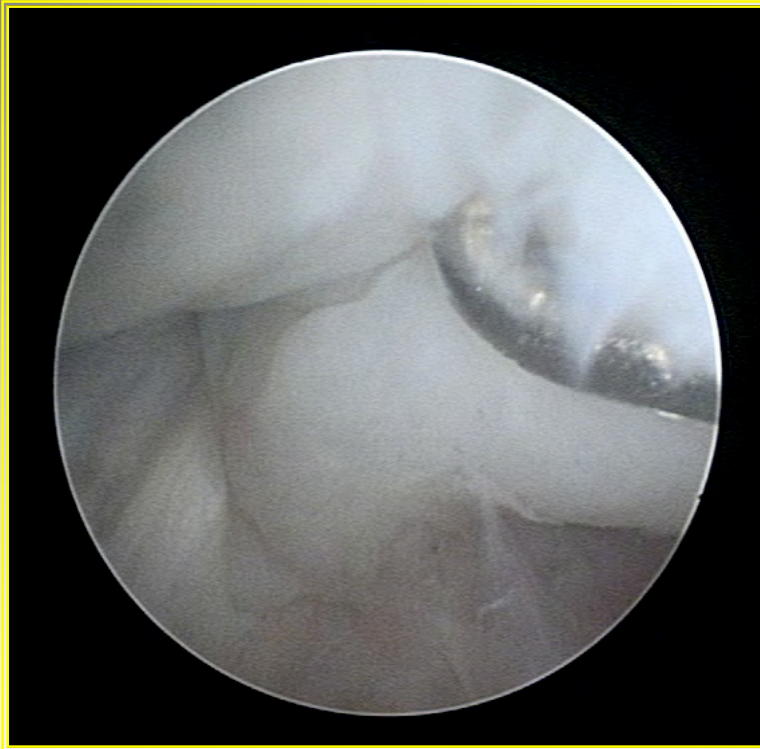
Lésions du ligament triangulaire

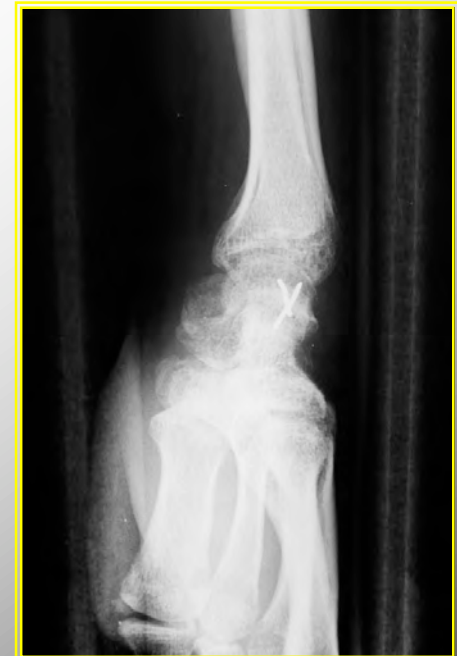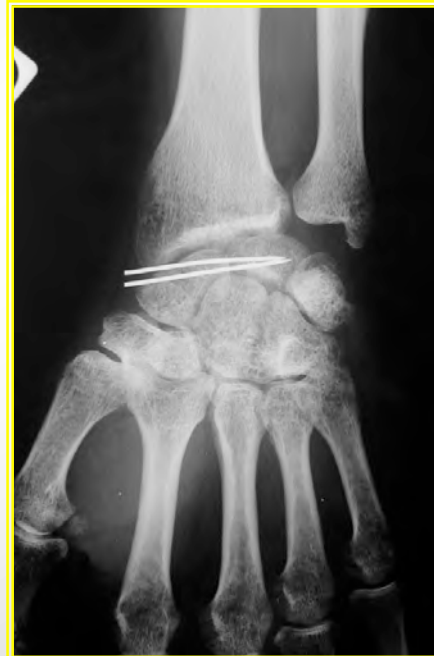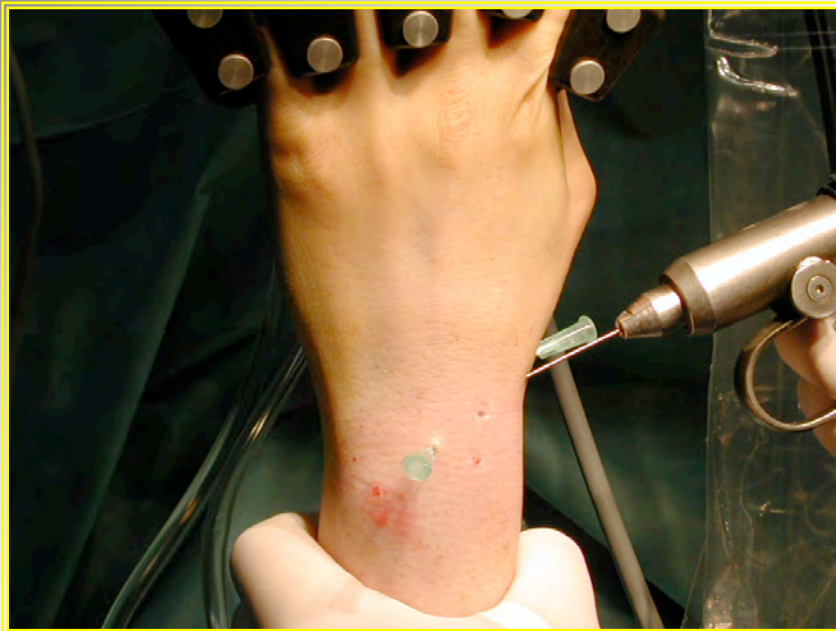


Lésions aiguës du ligament scapho-lunaire

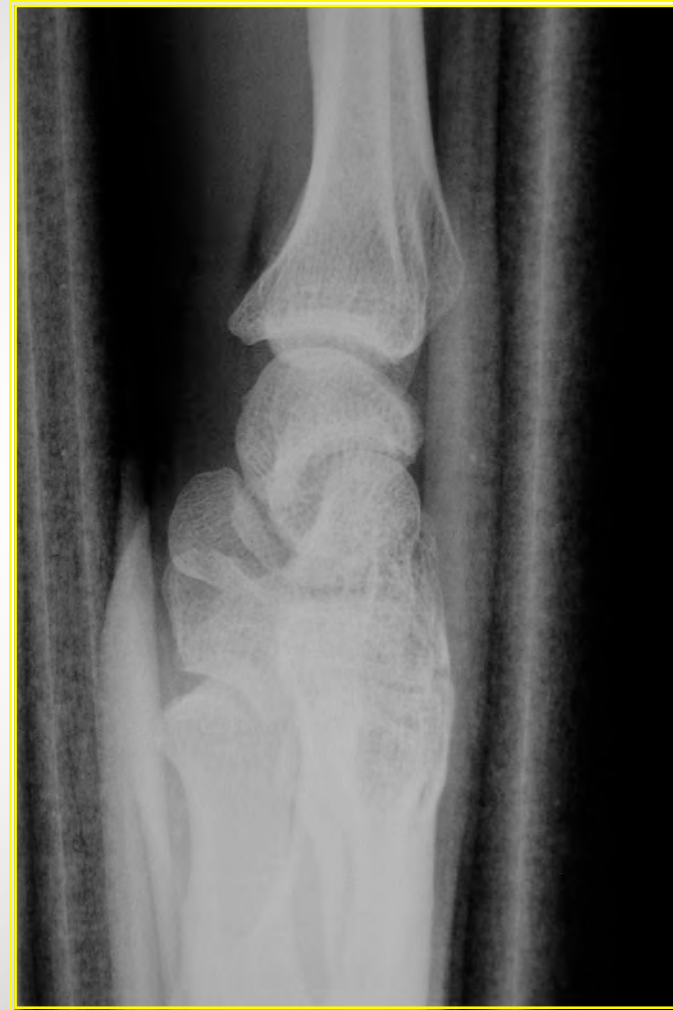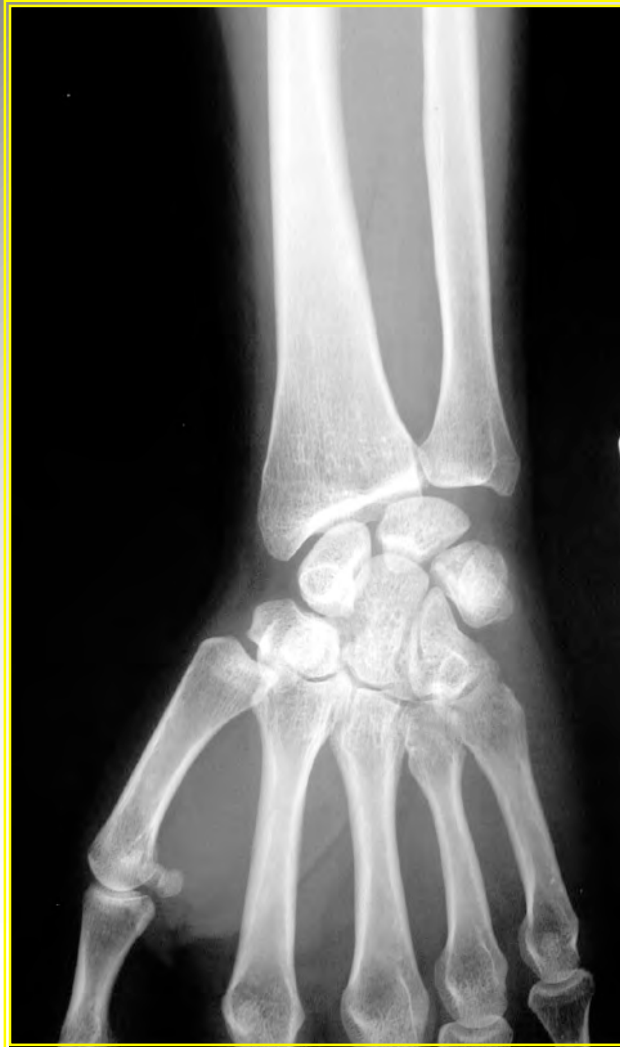Arthoscopie radio et médio-carpienne



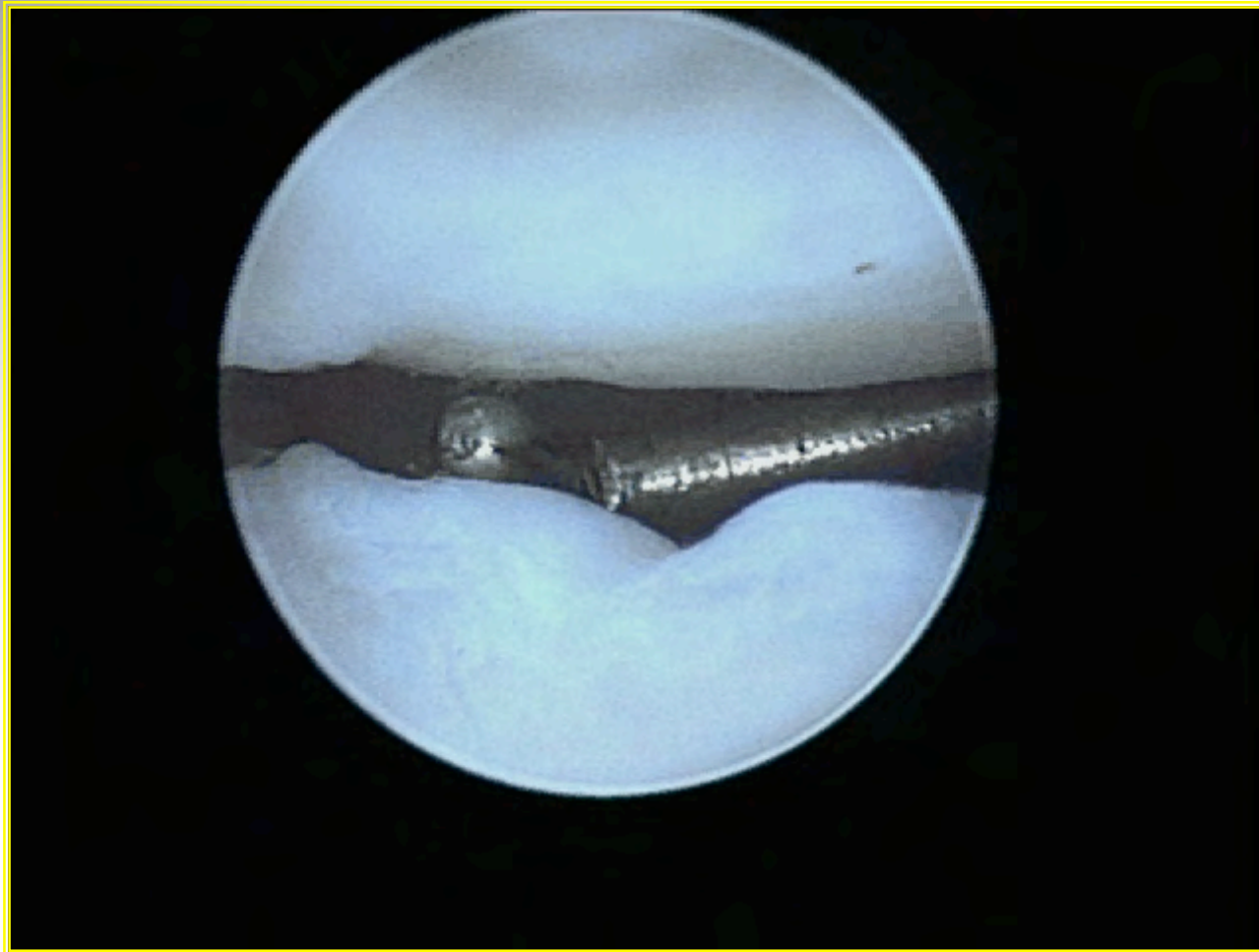Lésions aiguës du ligament scapho-lunaire



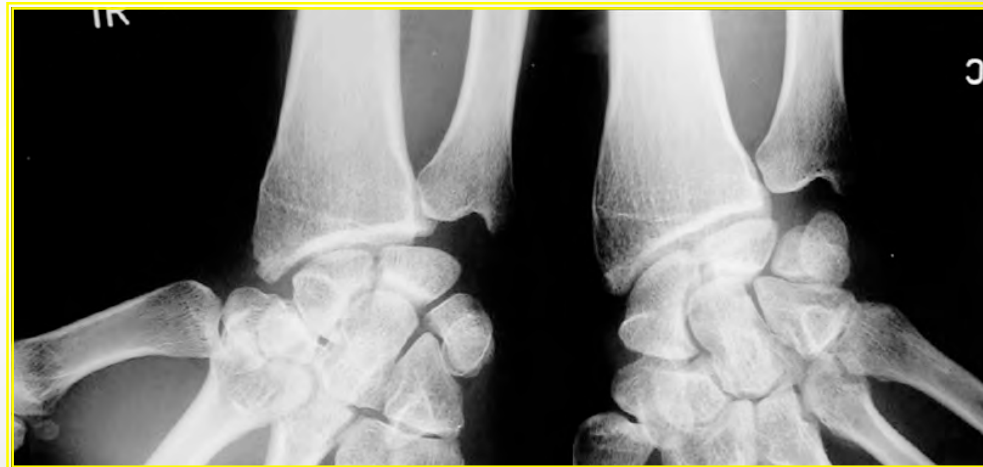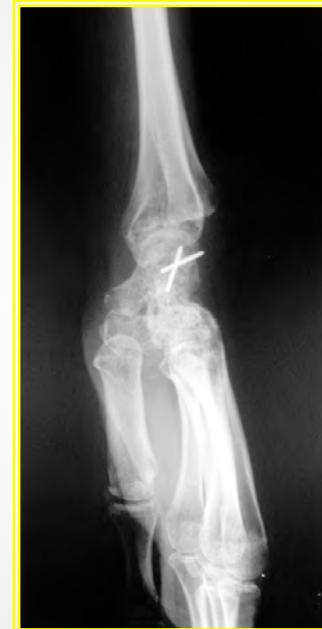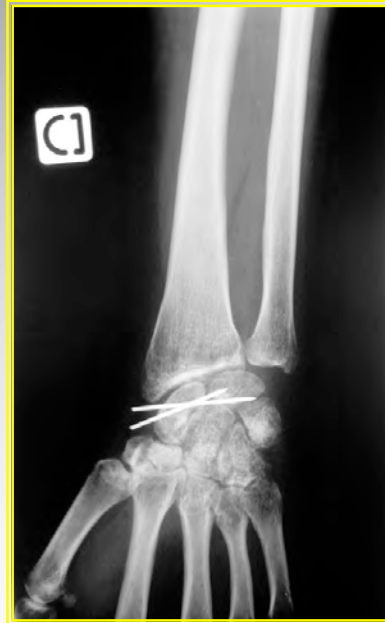Lésions aiguës du ligament scapho-lunaire



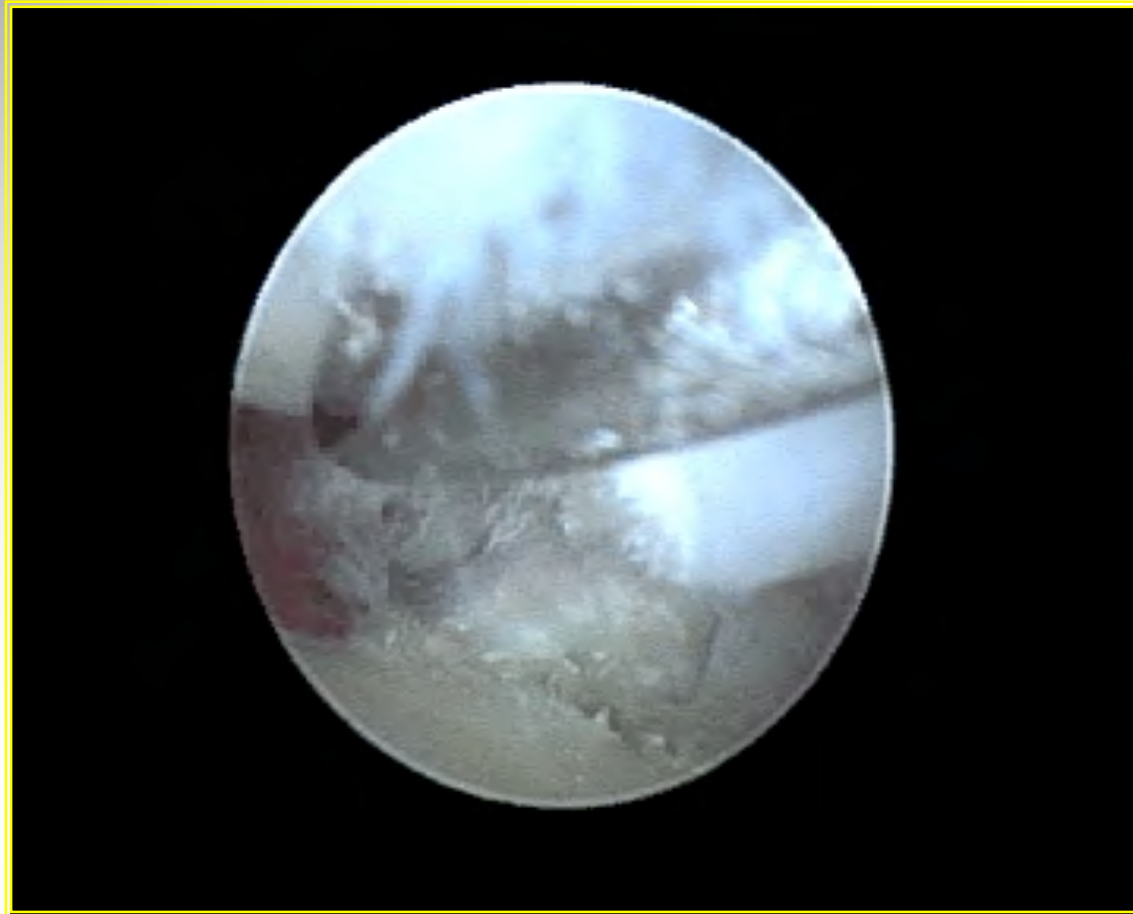
Lésions aiguës du ligament scapho-lunaire



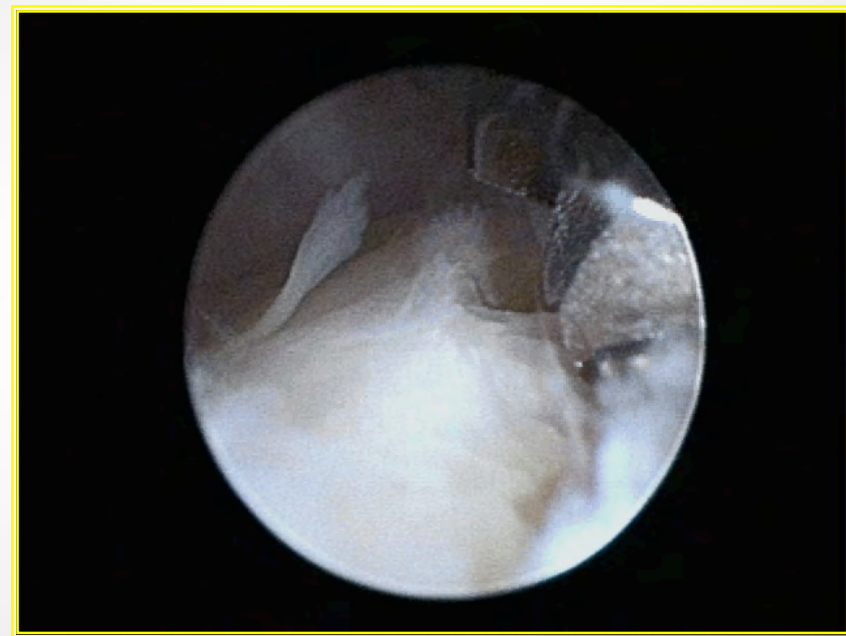
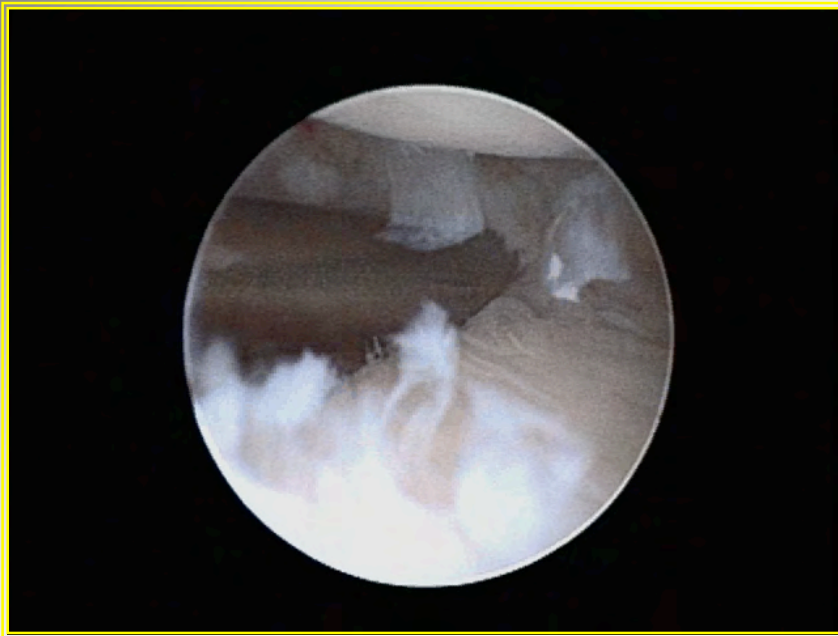
Lésions aiguës du ligament scapho-lunaire



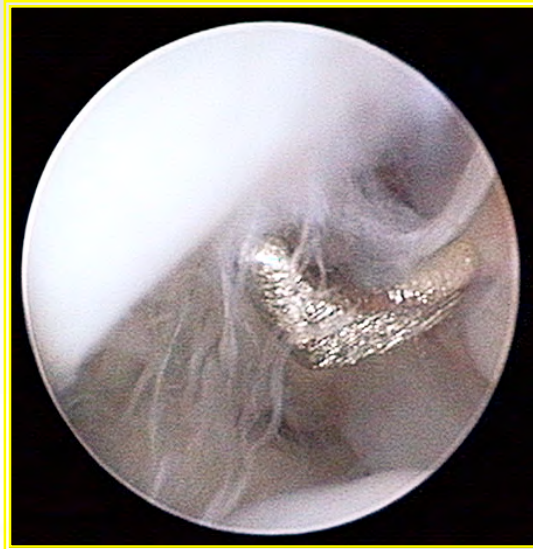
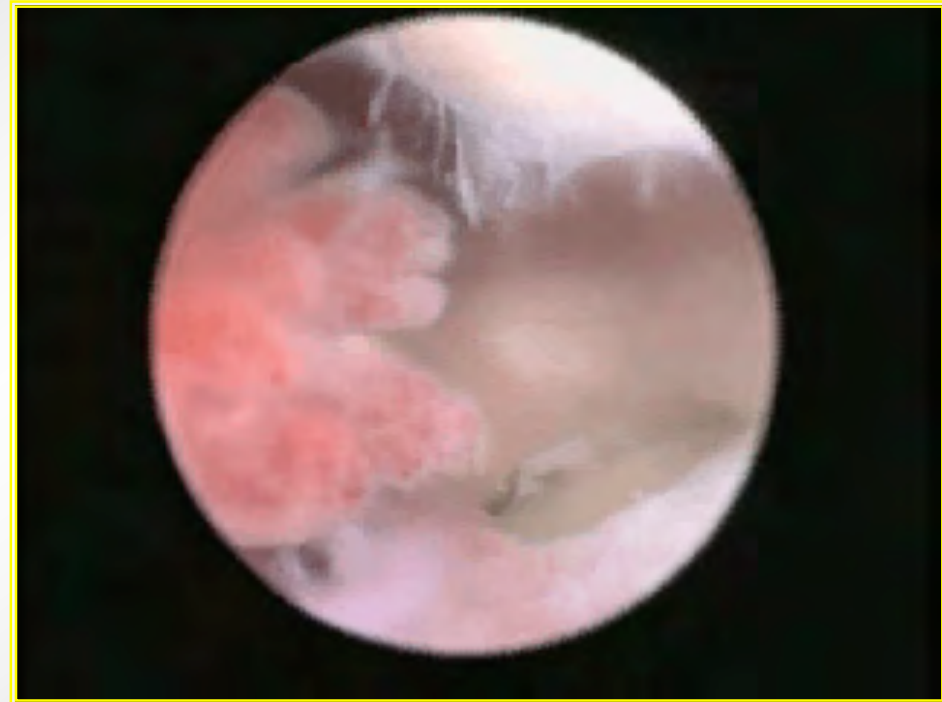
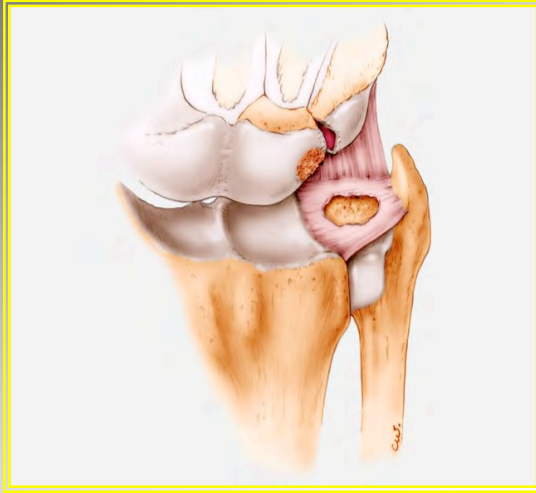
Lésions chroniques du ligament scapho-lunaire



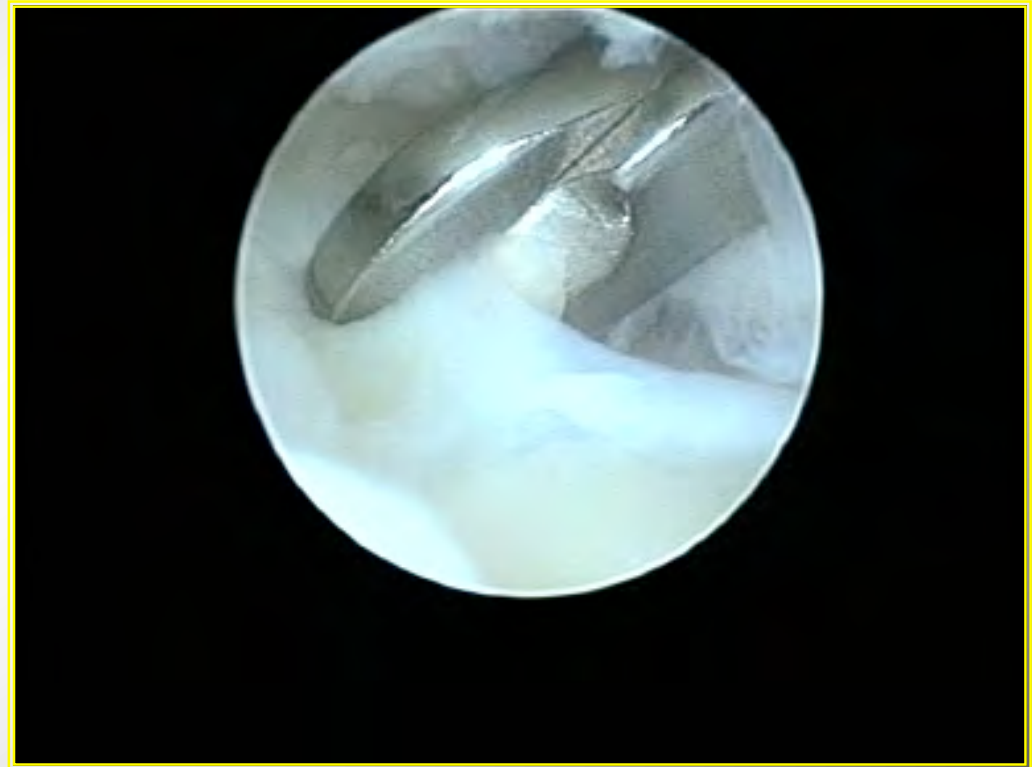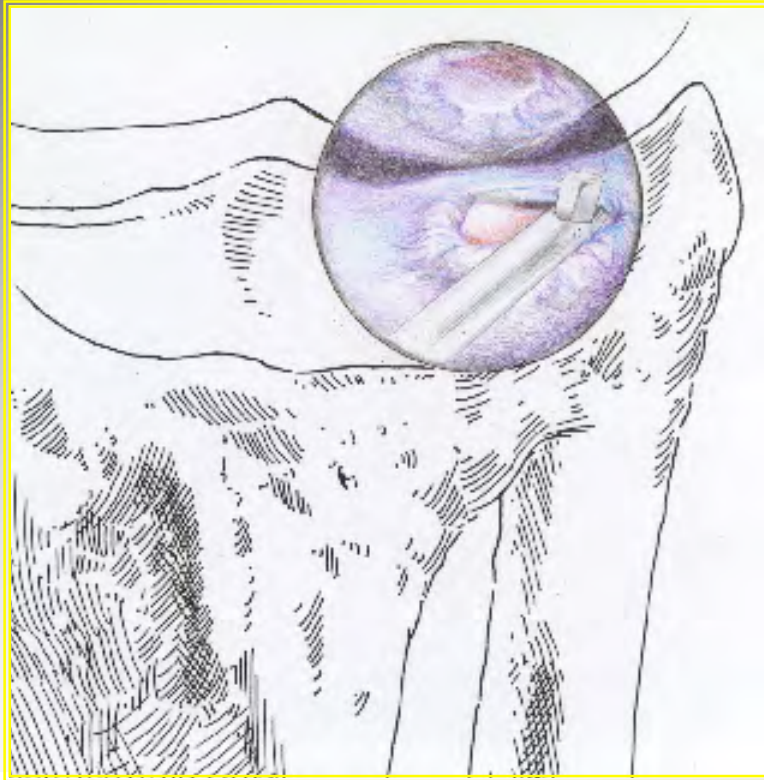
Styloïdectomie



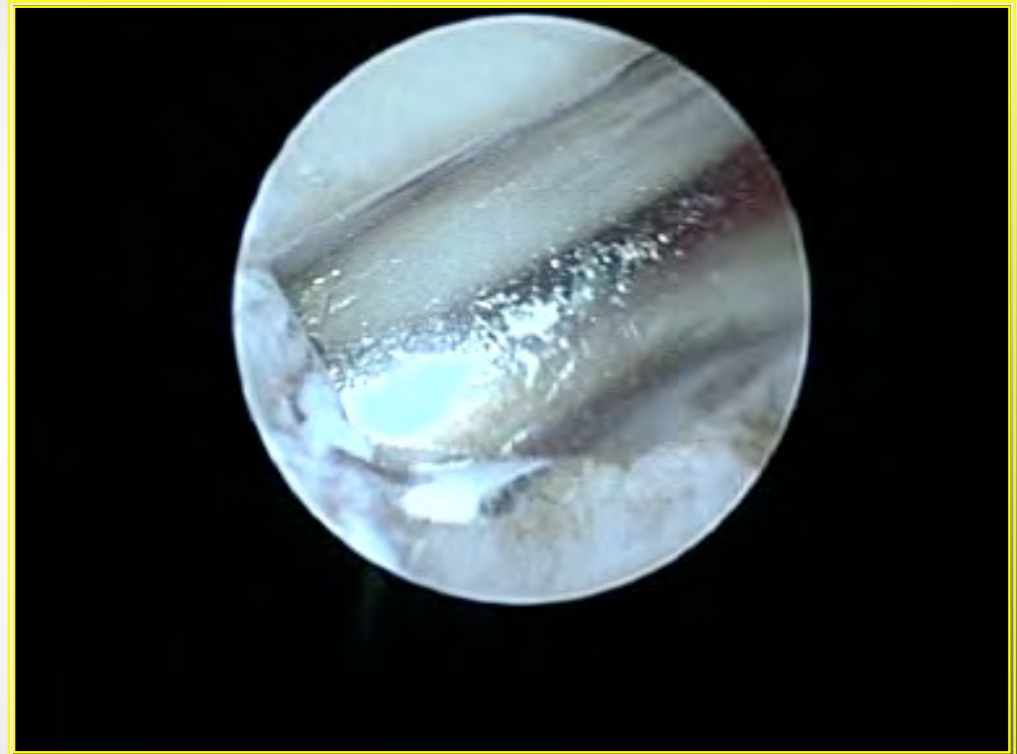
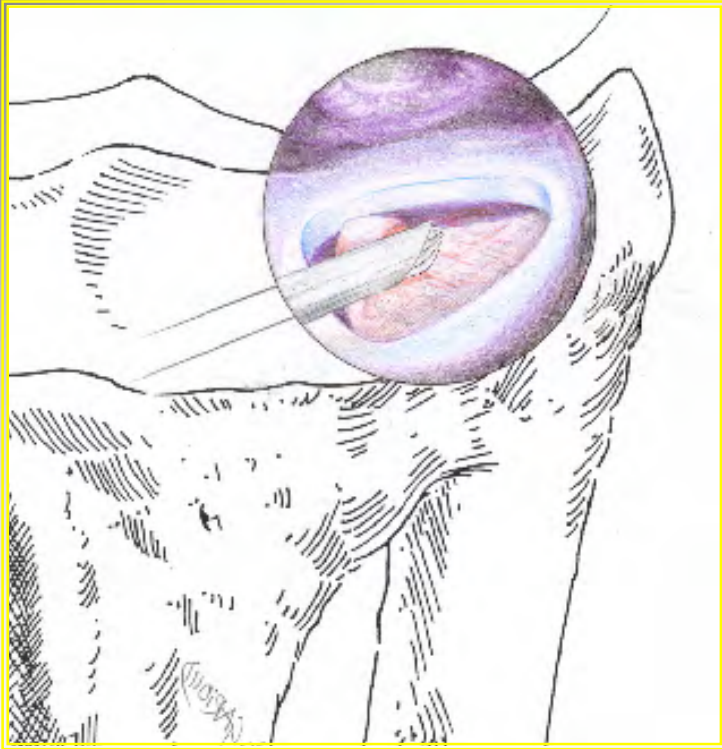
Résection distale de l'ulna (Wafer)



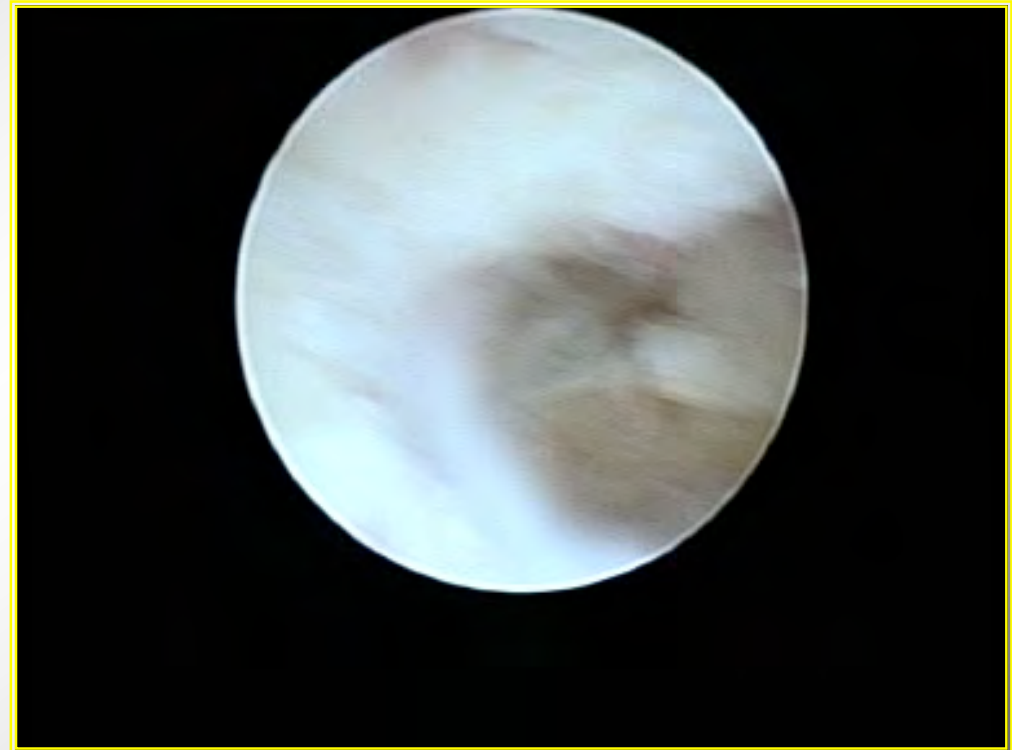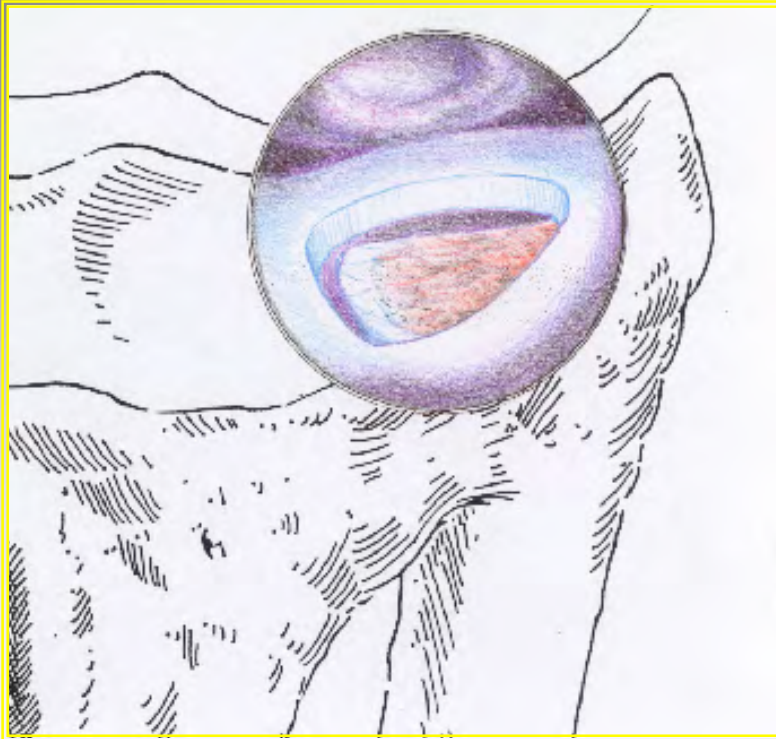
Résection distale de l'ulna (Wafer)



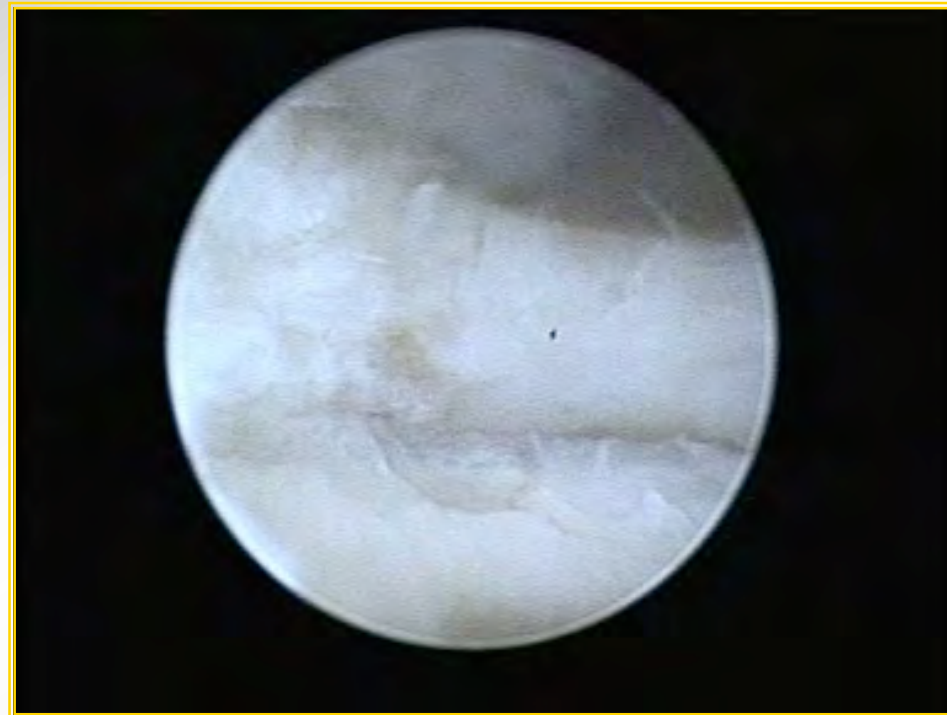Résection distale de l'ulna (Wafer)



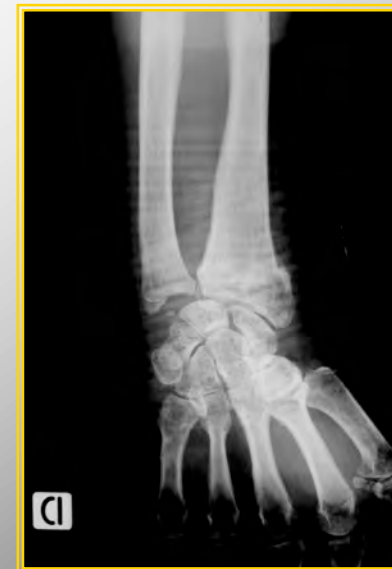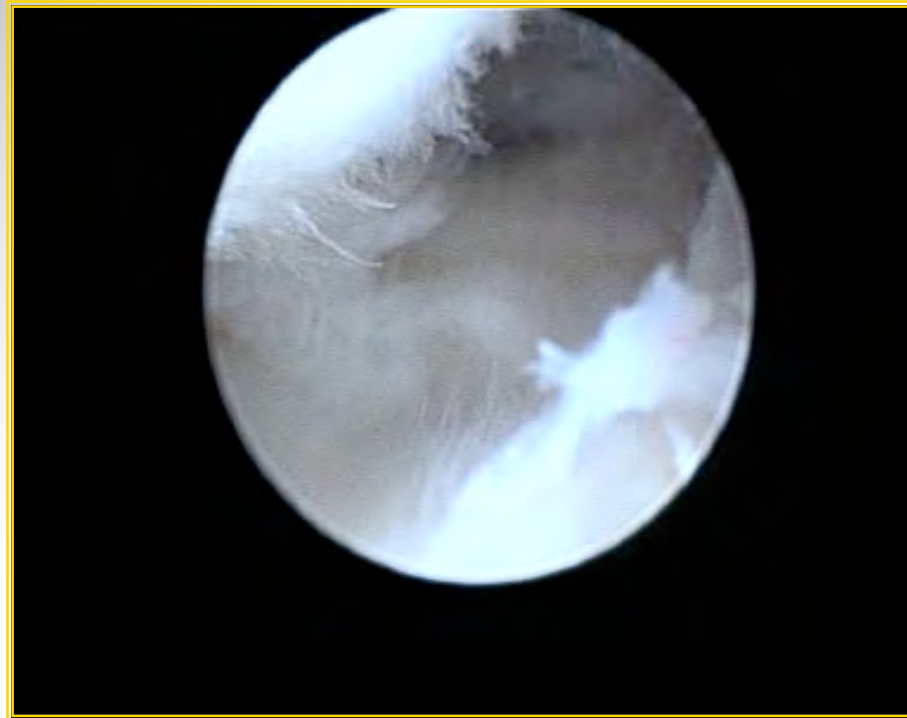
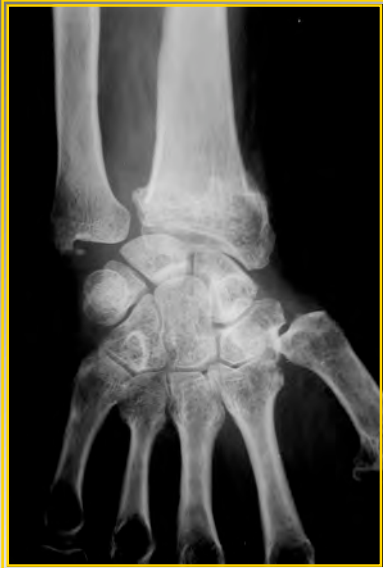Résection distale de l'ulna (Wafer)



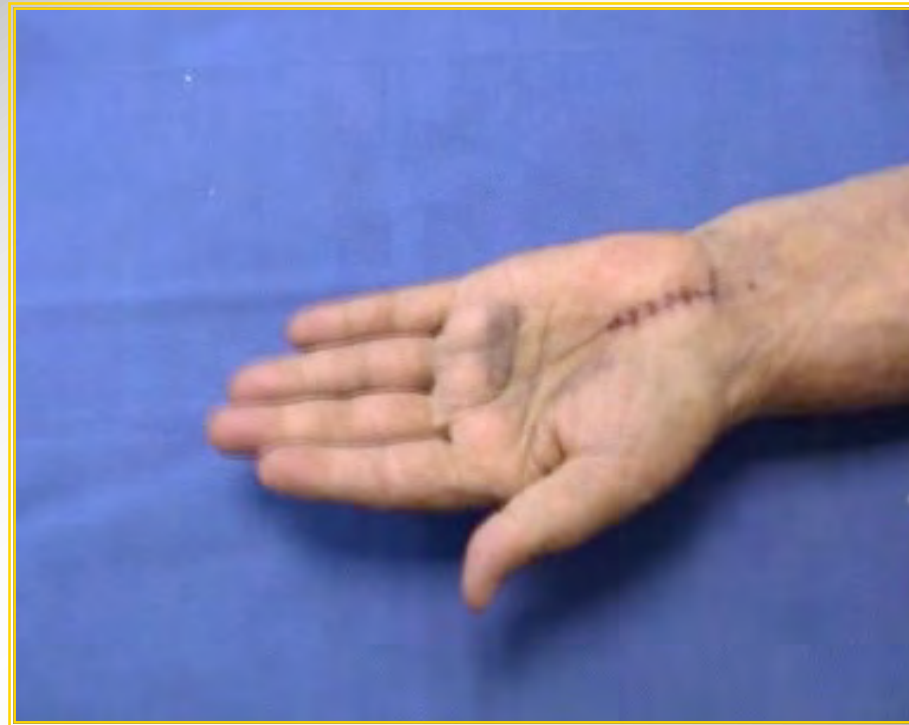Résection distale de l'ulna (Wafer)



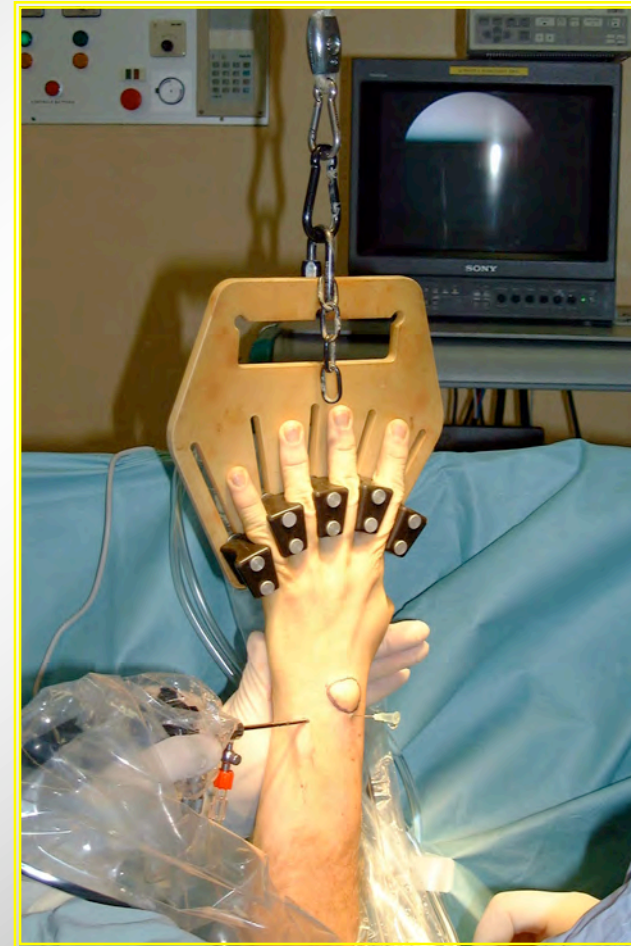
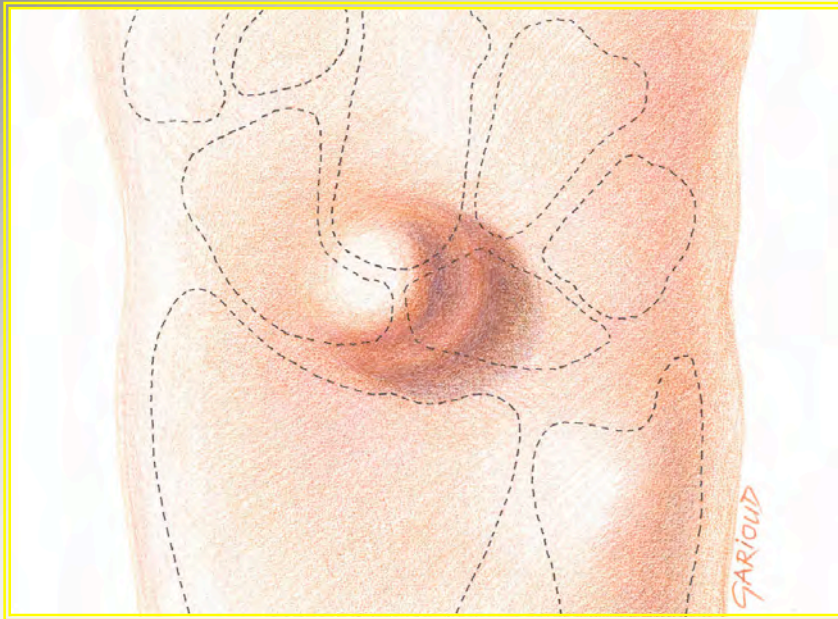
Résection distale de l'ulna (Wafer)



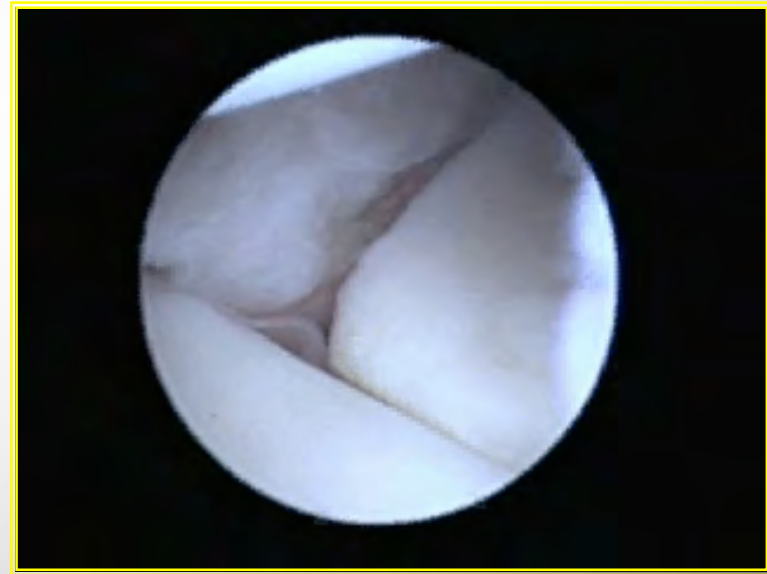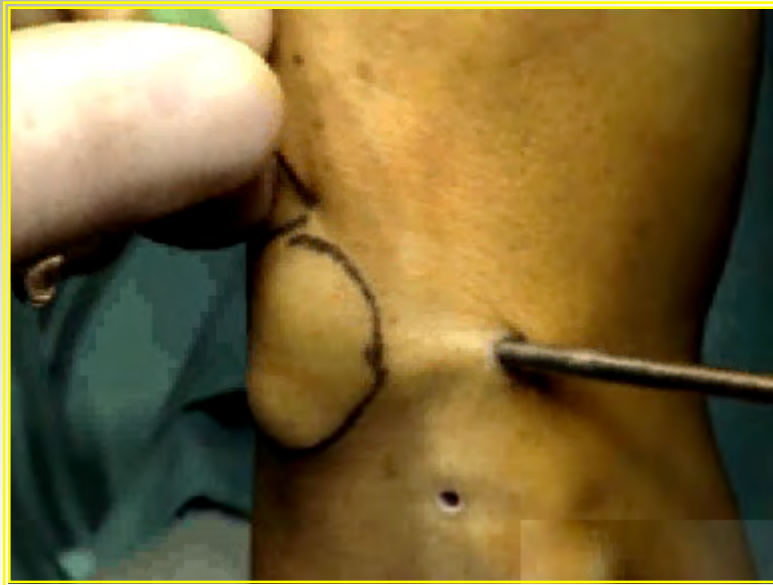Résection distale de l'ulna (Wafer)



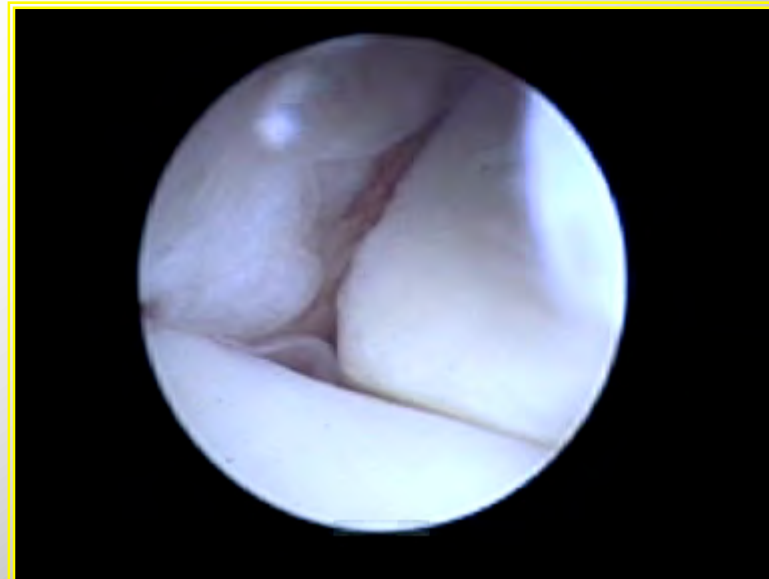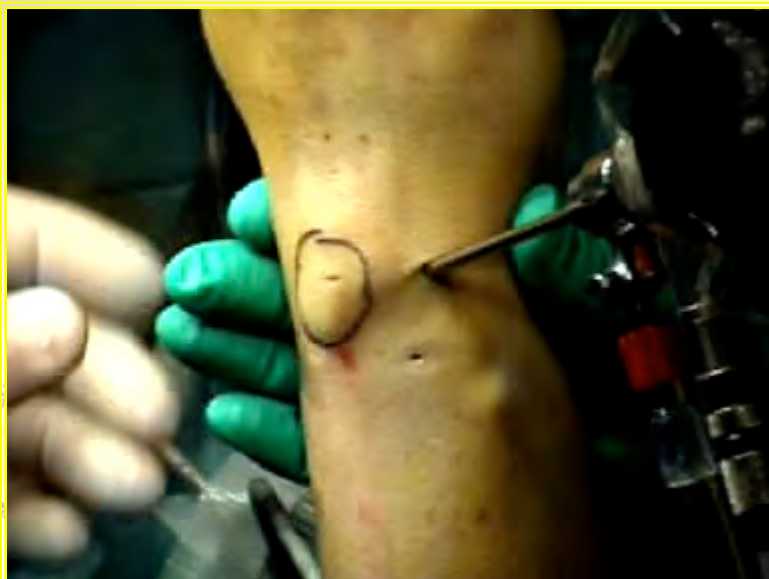
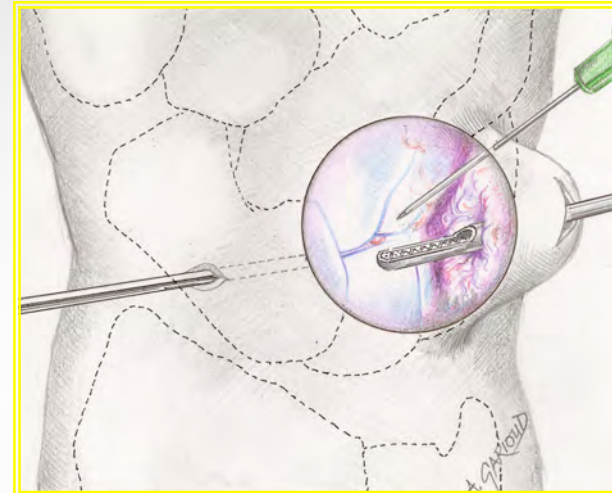
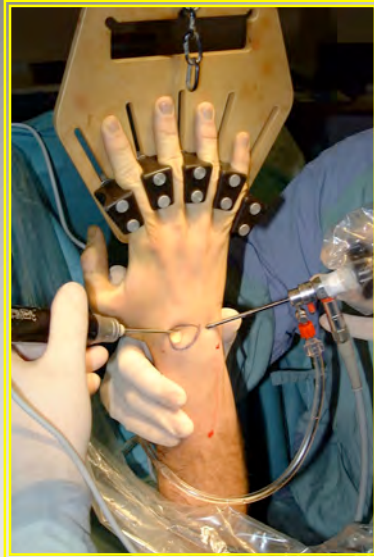Résection des kystes synoviaux dorsaux



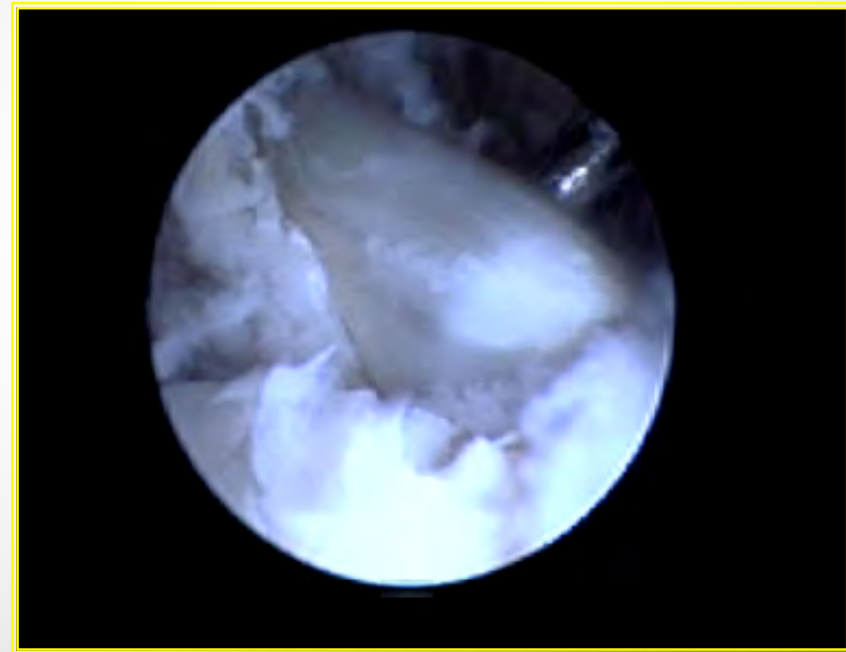
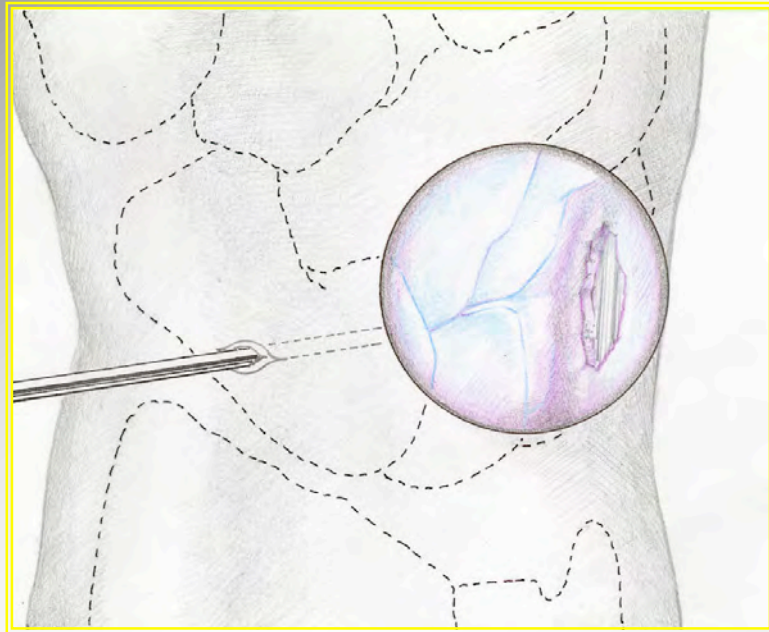
Résection des kystes synoviaux dorsaux



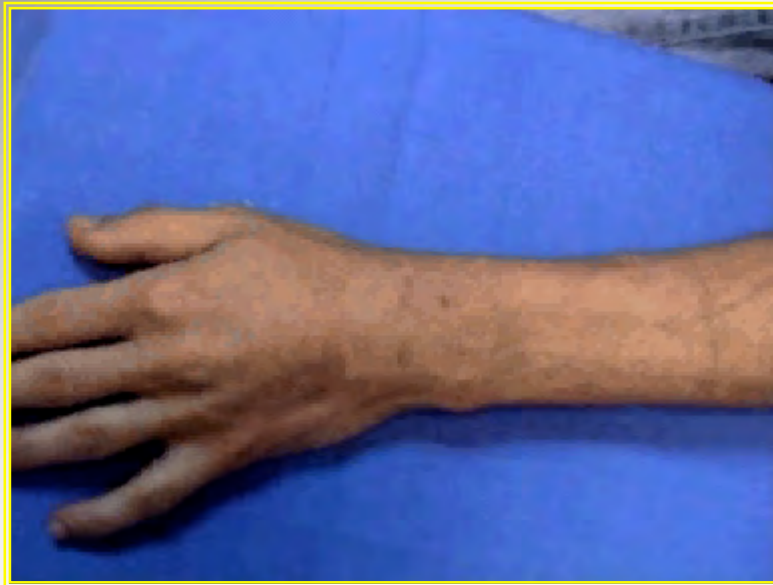Résection des kystes synoviaux dorsaux



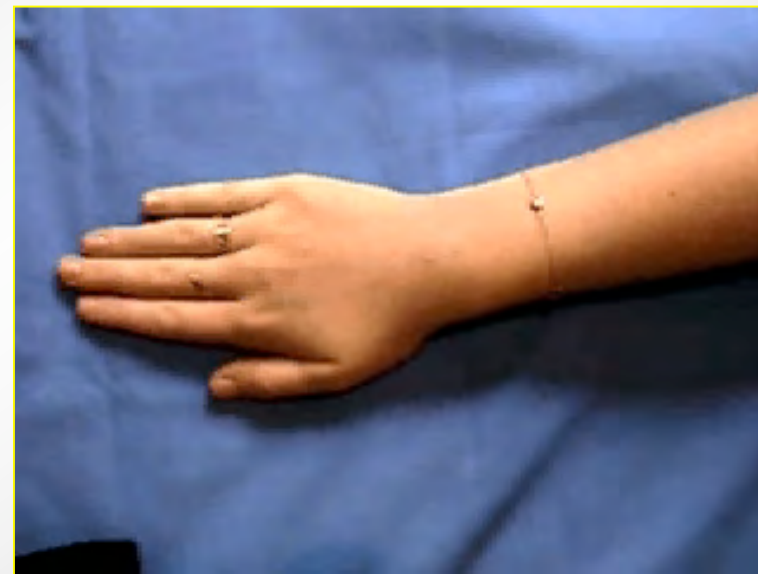Résection des kystes synoviaux dorsaux



Résection des kystes synoviaux dorsaux

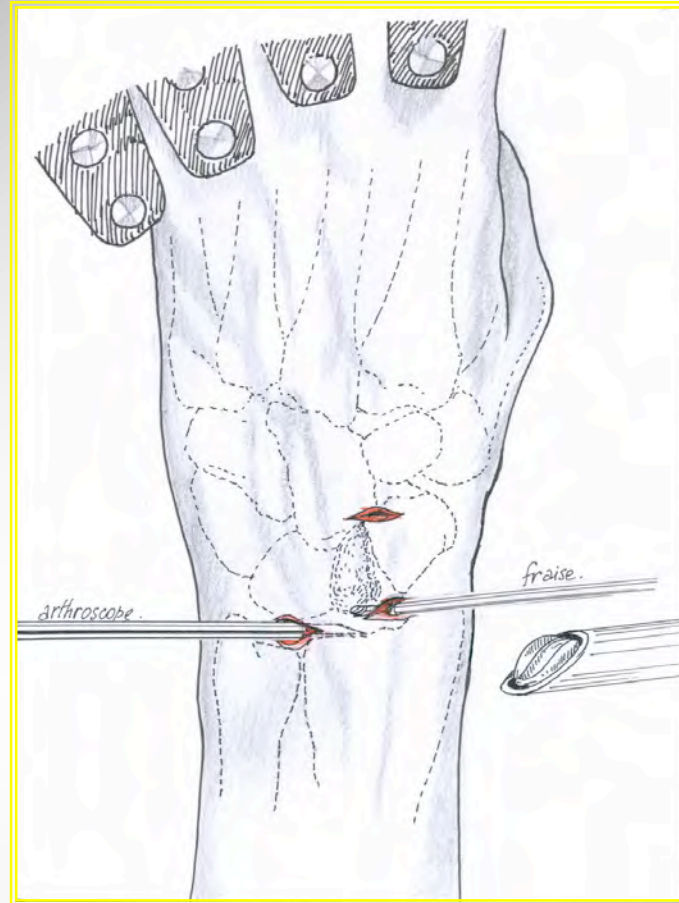


J+2

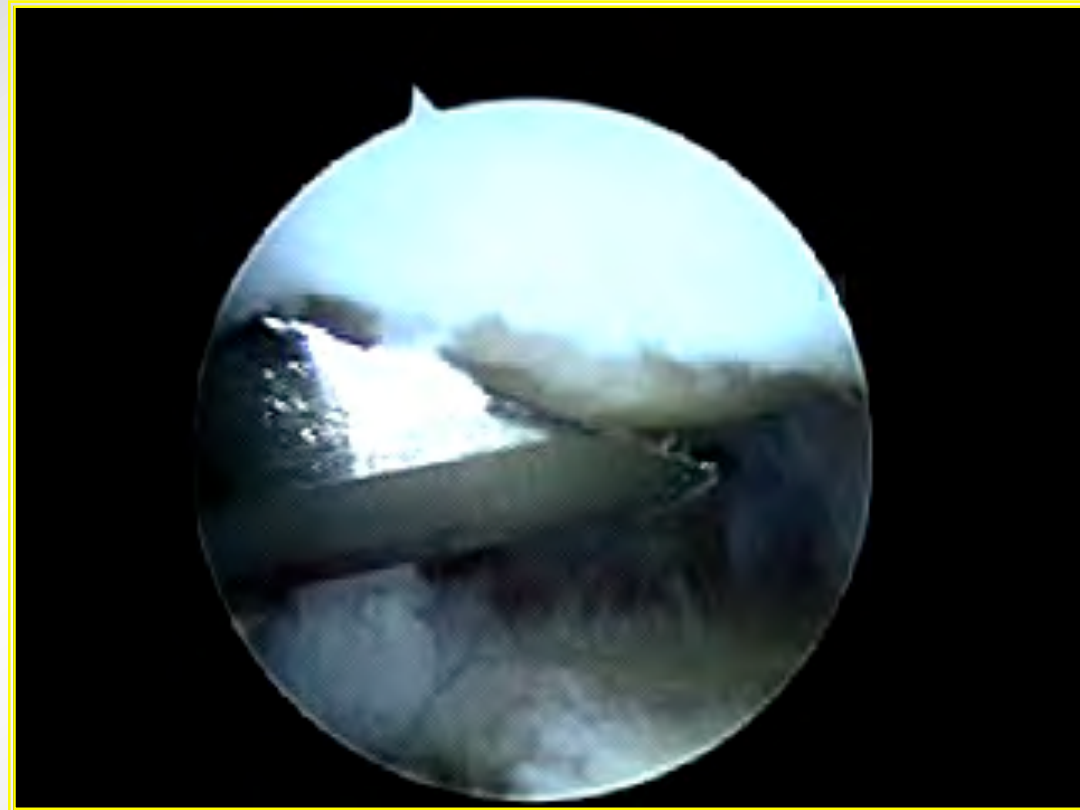
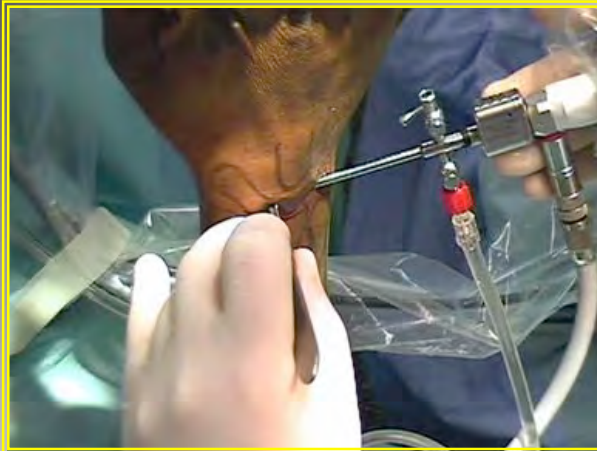


6 mois

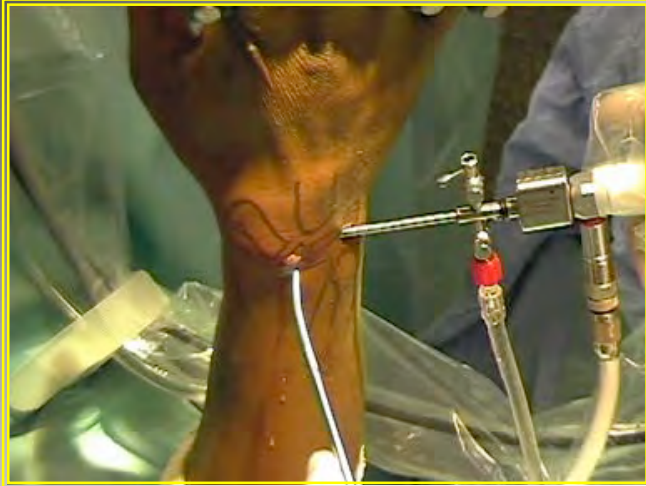
Prothèse partielle de scaphoïde



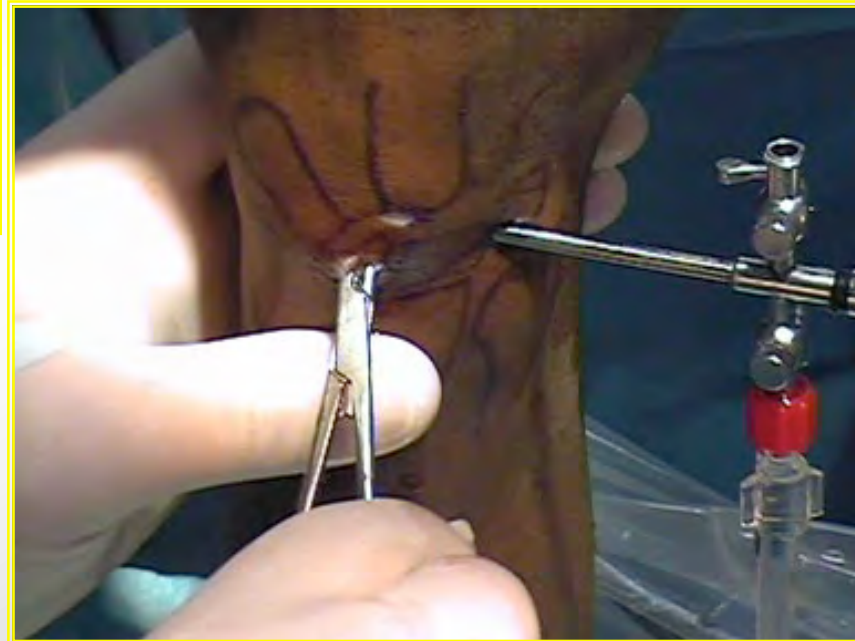
Prothèse partielle de scaphoïde



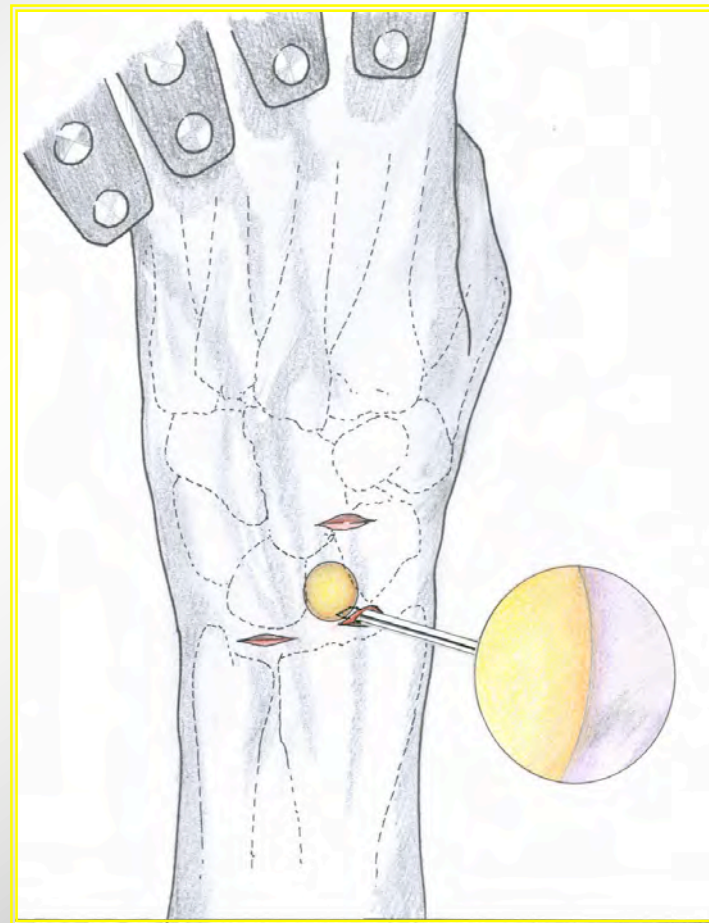
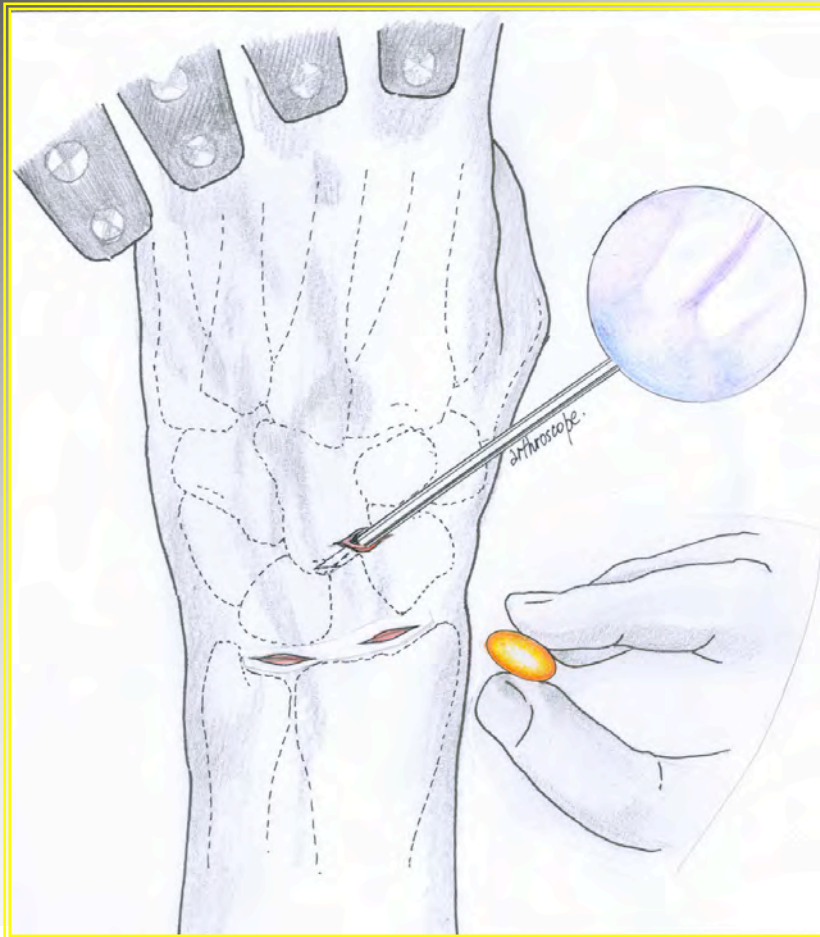Prothèse partielle de scaphoïde



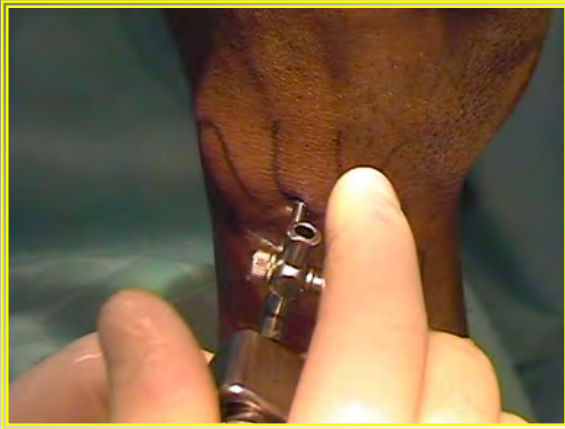Prothèse partielle de scaphoïde



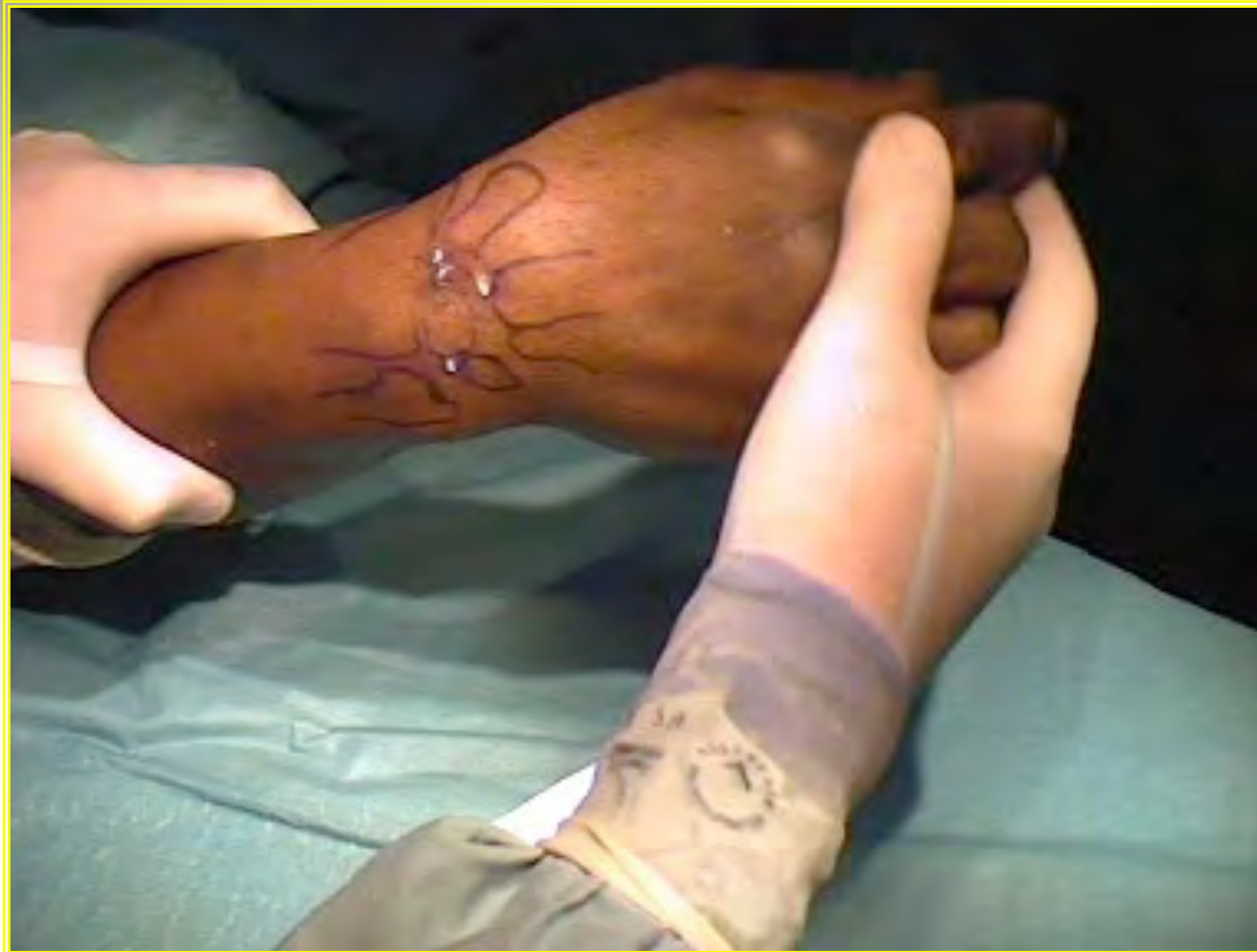Prothèse partielle de scaphoïde



Prothèse partielle de scaphoïde



Prothèse partielle de scaphoïde



Prothèse partielle de scaphoïde

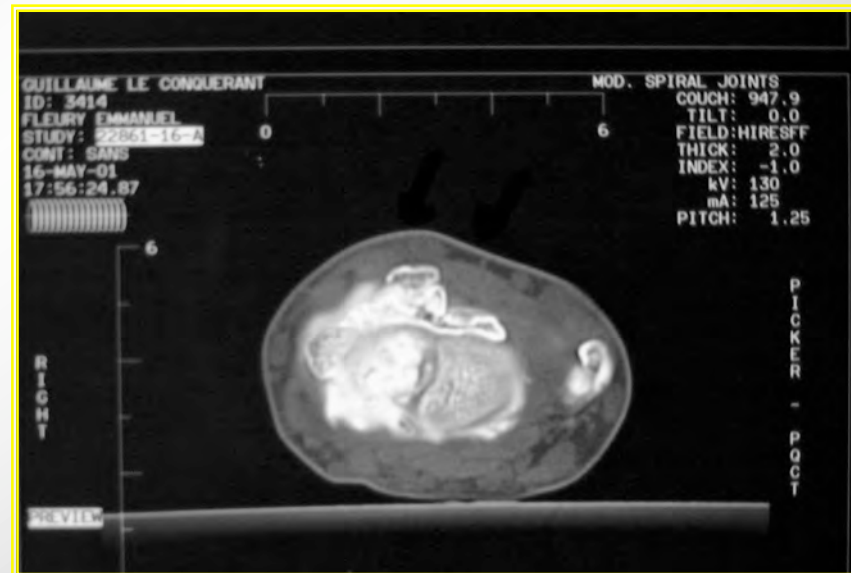
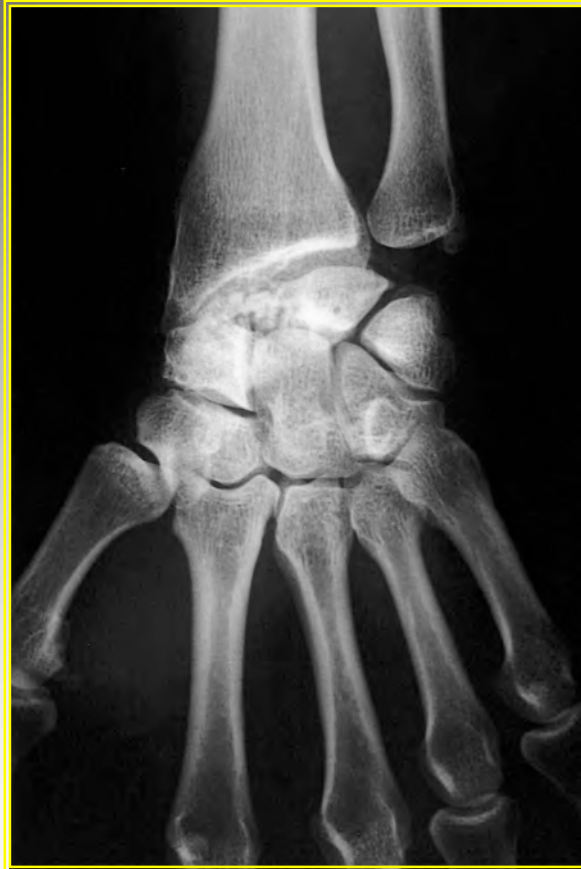Mr. F 42 ans

nécrose morcellée du
pole proximal

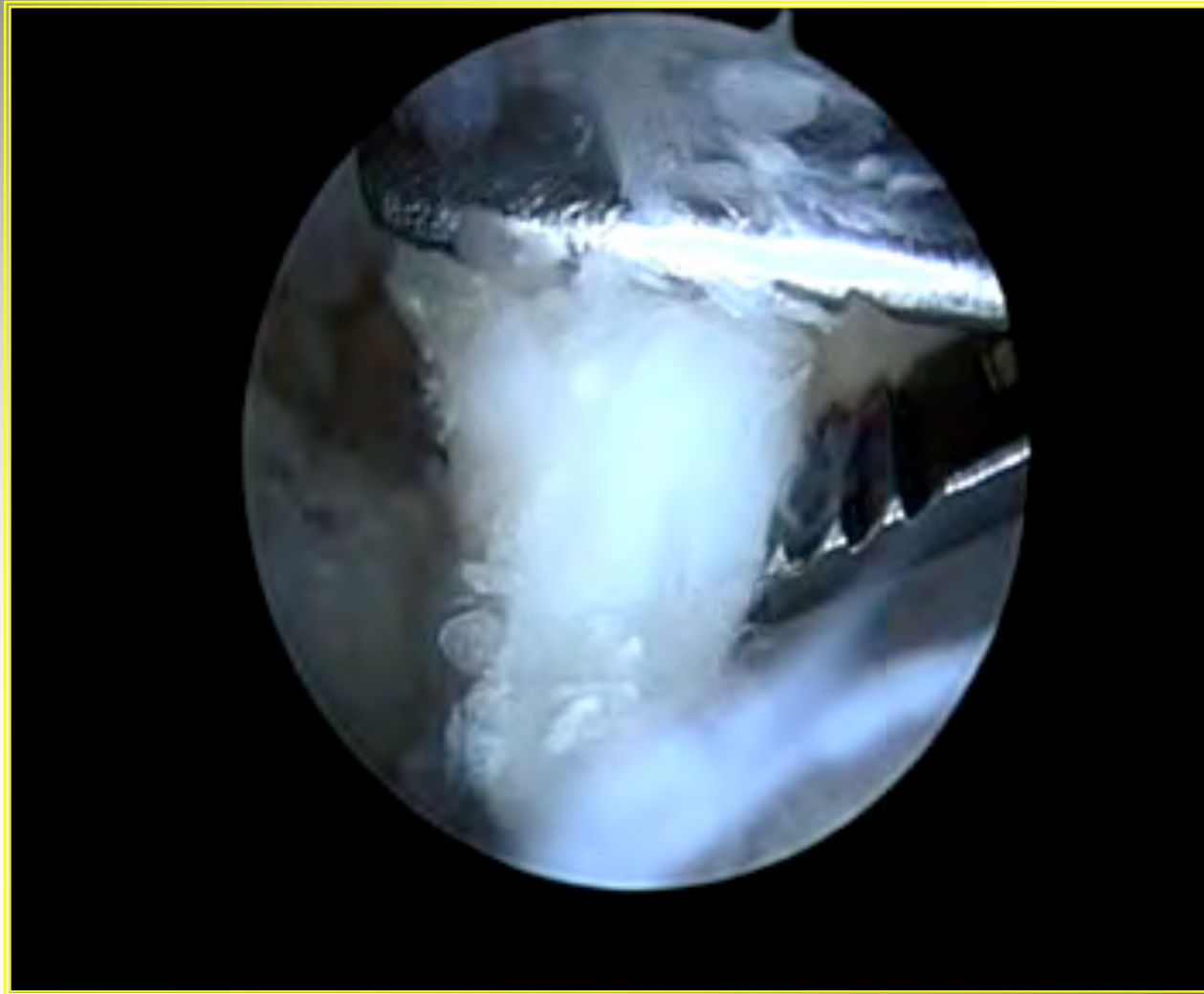
Flexion 20°

Extension 30°

douleurs invalidantes



Prothèse partielle de scaphoïde

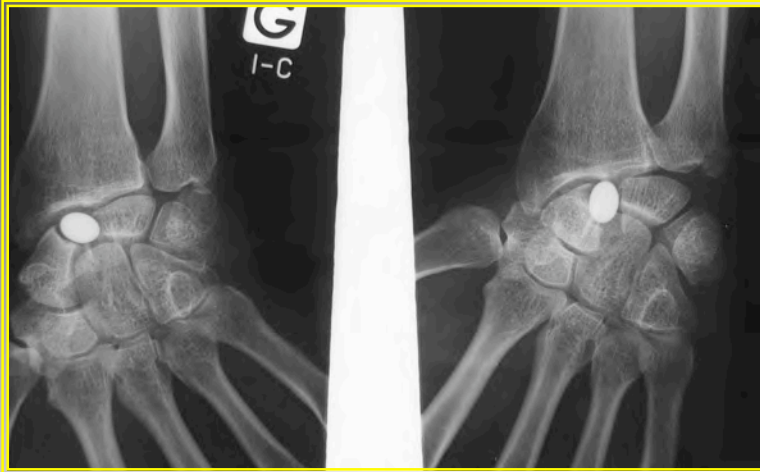


Prothèse partielle de scaphoïde

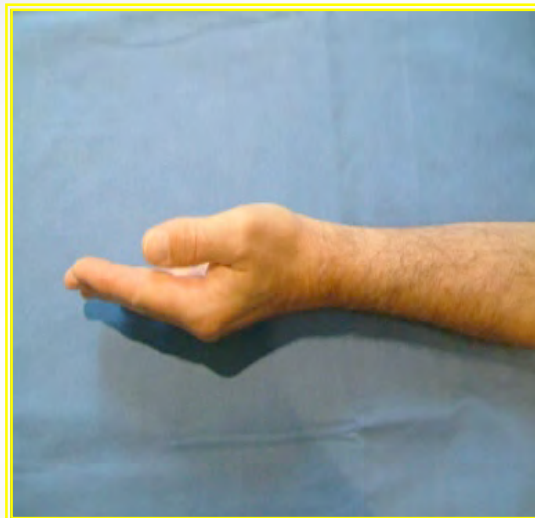
J + 3 semaines



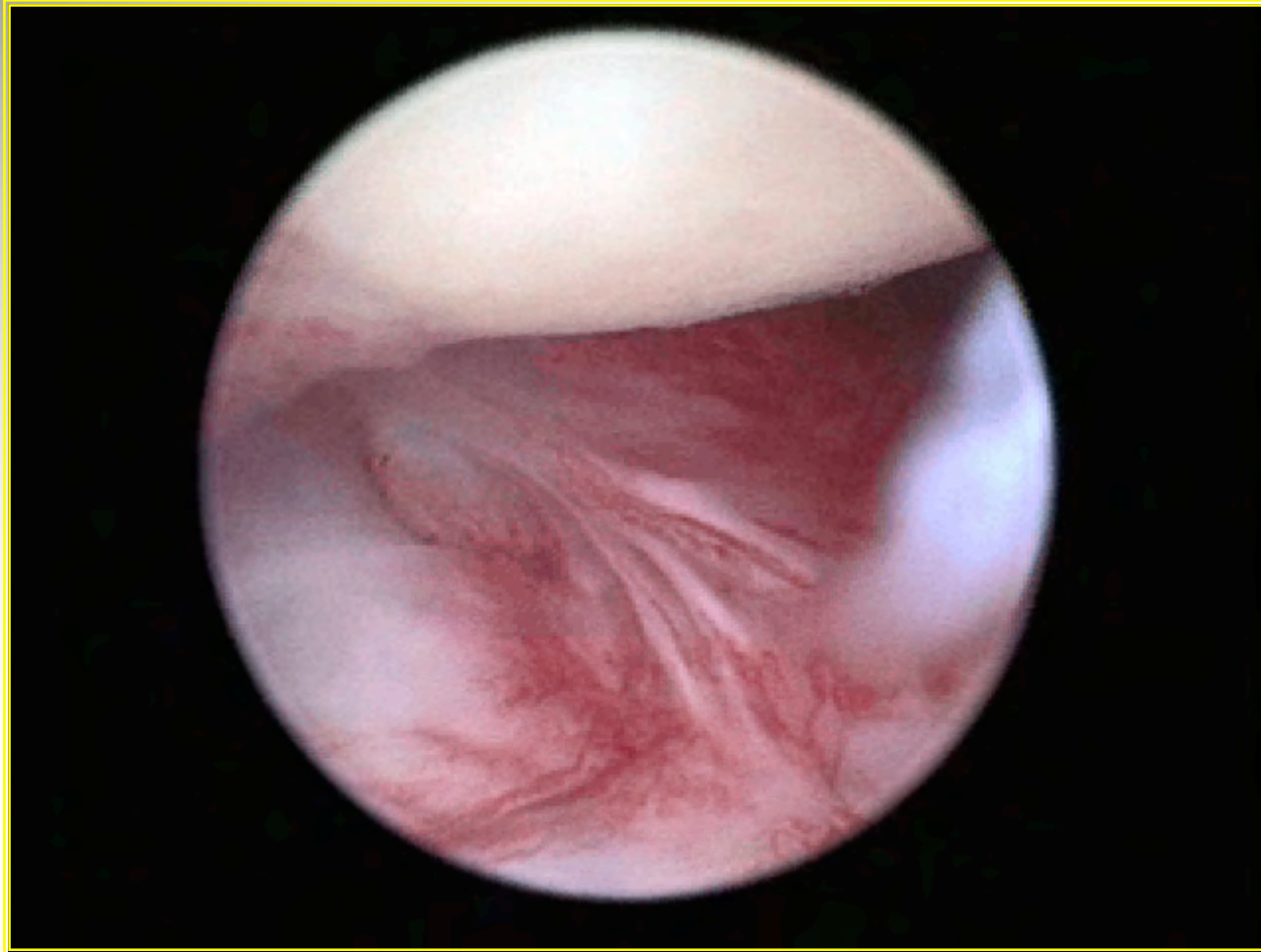
Prothèse partielle de scaphoïde



4 ans de recul
Flexion 45°
Extension 60°
Pas de douleur



Autres : Synovectomie



AUTRES

Carpe bossu

Résection des kystes palmaires

Lésions du ligament luno-triquétral

Arthrolyse du poignet

Prothèse d'interposition STT

.....



COMPLICATIONS

Algoneurodystrophies : 9 cas (1%)

Lésions nerveuses : 8 cas (0,8 %)

Lésions tendineuses : 3 cas (0,3%)

Hématomes : 6 cas (0,6%)



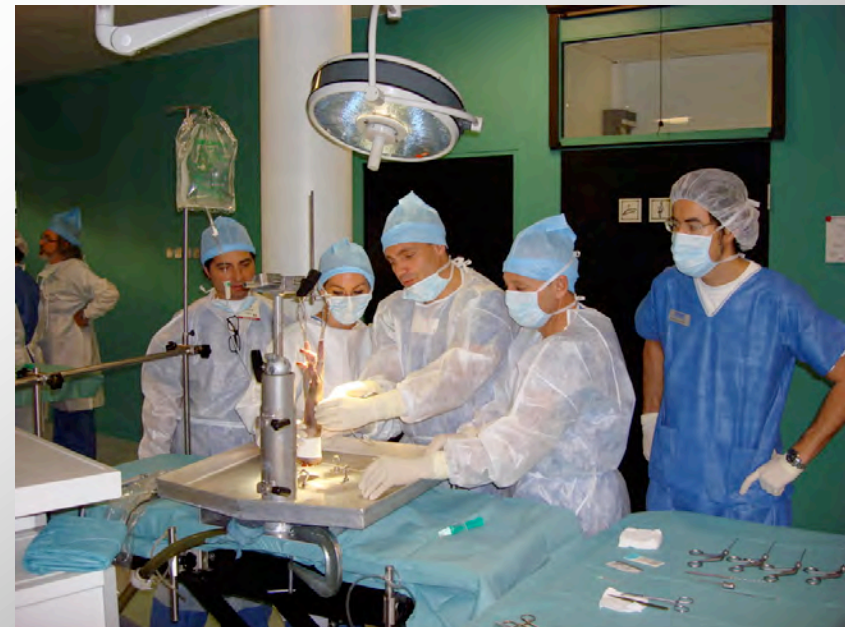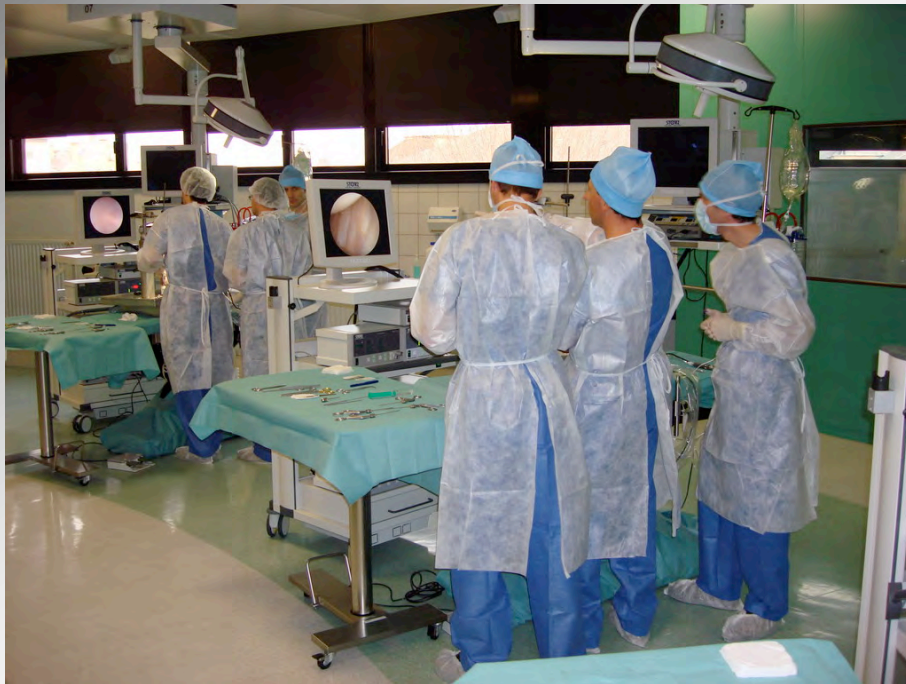Enseignement

Ircad/Eits Strasbourg



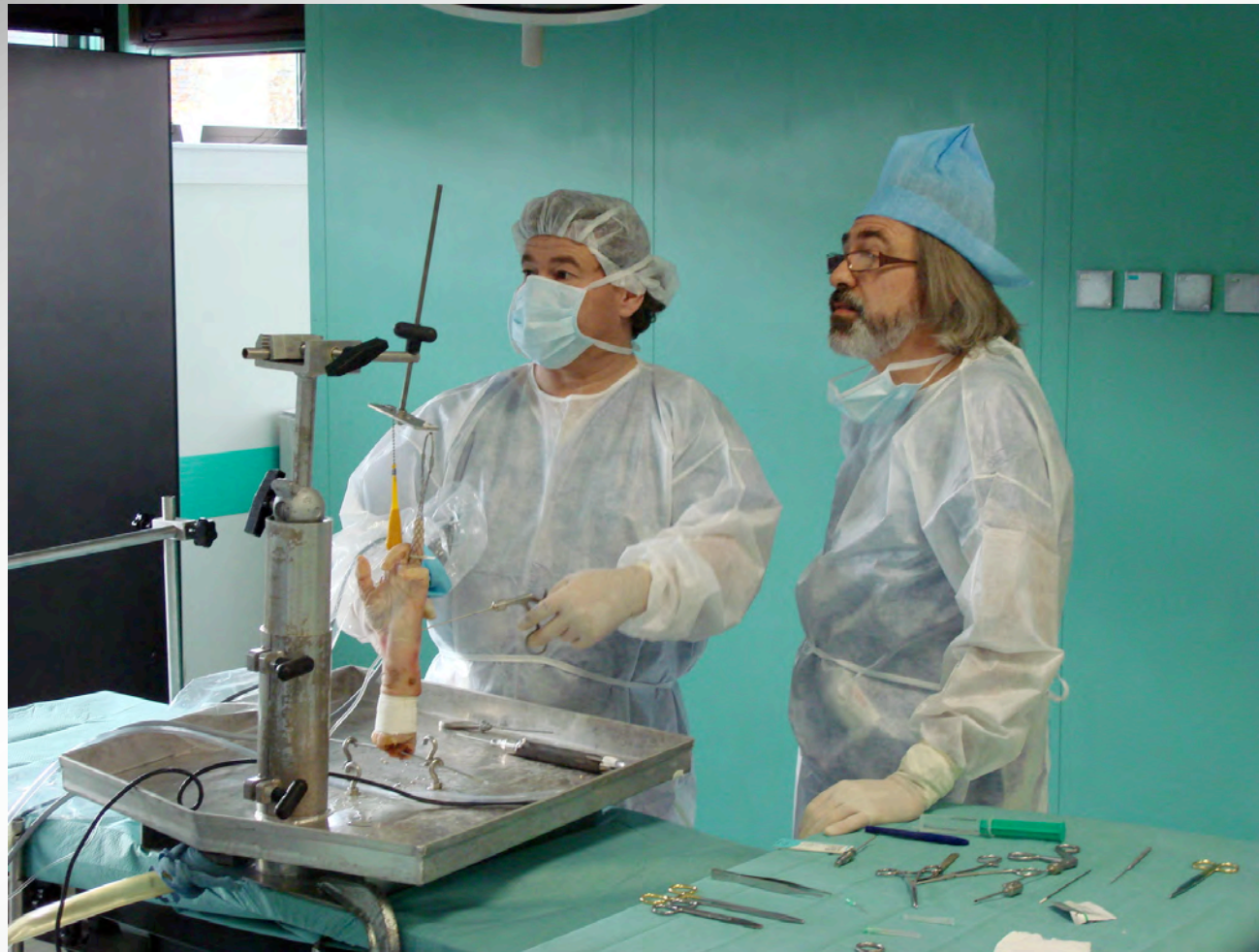Enseignement

Ircad/Eits Strasbourg



Enseignement

Ircad/Eits Strasbourg



Enseignement

Ircad/Eits Strasbourg



Enseignement

Ircad/Eits Strasbourg



Enseignement

Ircad/Eits Strasbourg



Enseignement

Ircad/Eits Strasbourg



Conclusion

L'arthroscopie du poignet
devient une technique de routine.

Intérêt diagnostique et thérapeutique.

Indications en hausse.

