Généralités sur l'orthopédie-traumatologie

Christian Dumontier
Institut de la Main & Hôpital Saint Antoine, Paris

Orthopédie

- *Orthos* (droit), *peidein* (pied ou enfant)
- Nicolas Andry (XVIIIème)
- Symbole: arbre tordu avec un tuteur

Orthopédie

- Prise en charge des lésions non-traumatiques de l'appareil locomoteur
  - Maladies dégénératives
  - Maladies inflammatoires
  - Tumeurs
  - Malformations (différences) congénitales

Maladies dégénératives articulaires

- Arthrose: usure anormale, précoce du cartilage articulaire
  - Arthrose primitive
  - Arthrose “métabolique”
  - Arthrose secondaire à des troubles mécaniques

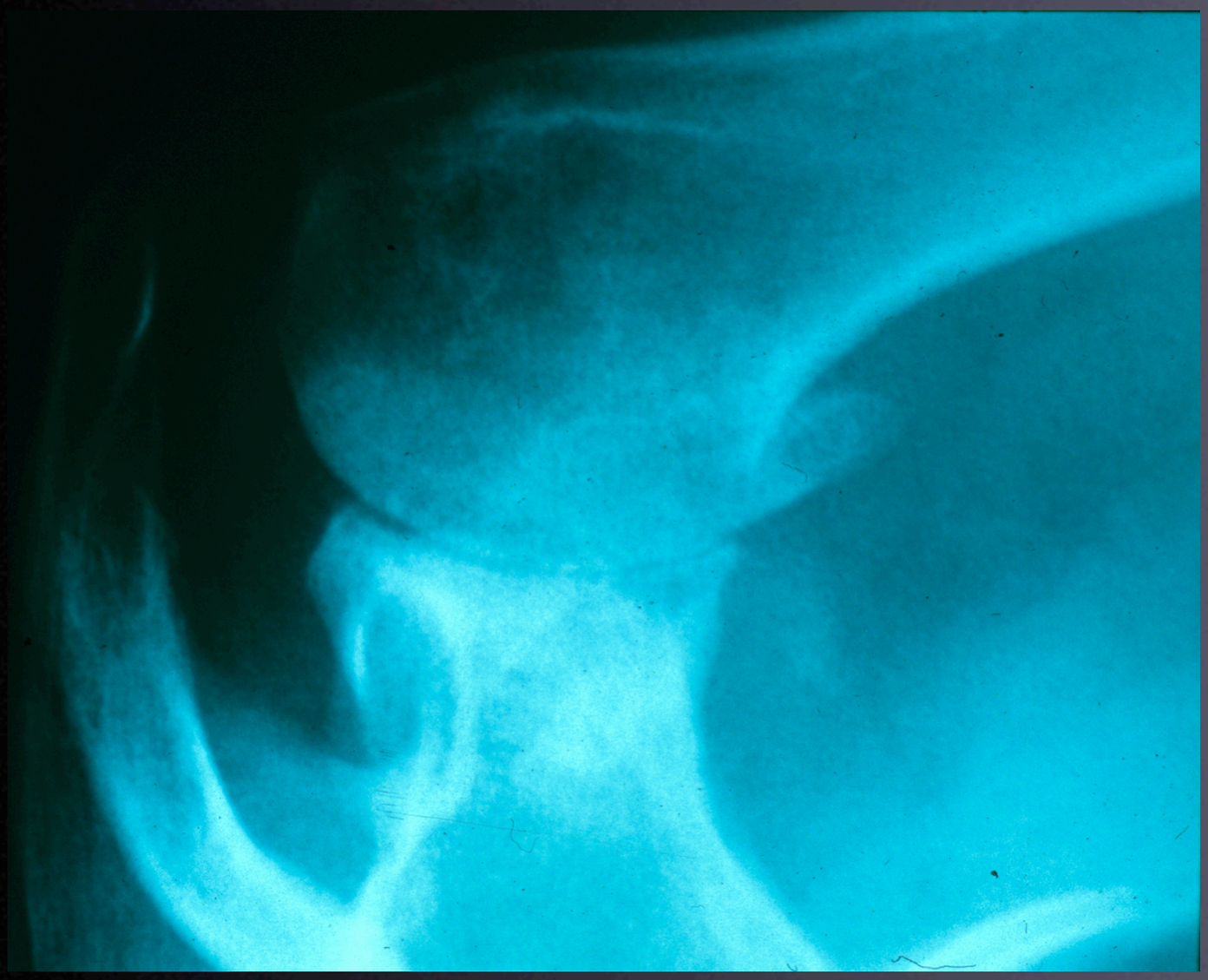

Mme HUBERT
Ex : 04-10-02

Maladies dégénératives des tendons

- Tendinopathies:
  - Douleurs tendineuses lors des mouvements
  - Accrochages, ressauts
  - Ruptures (biceps, achille, coiffe des rotateurs,...)

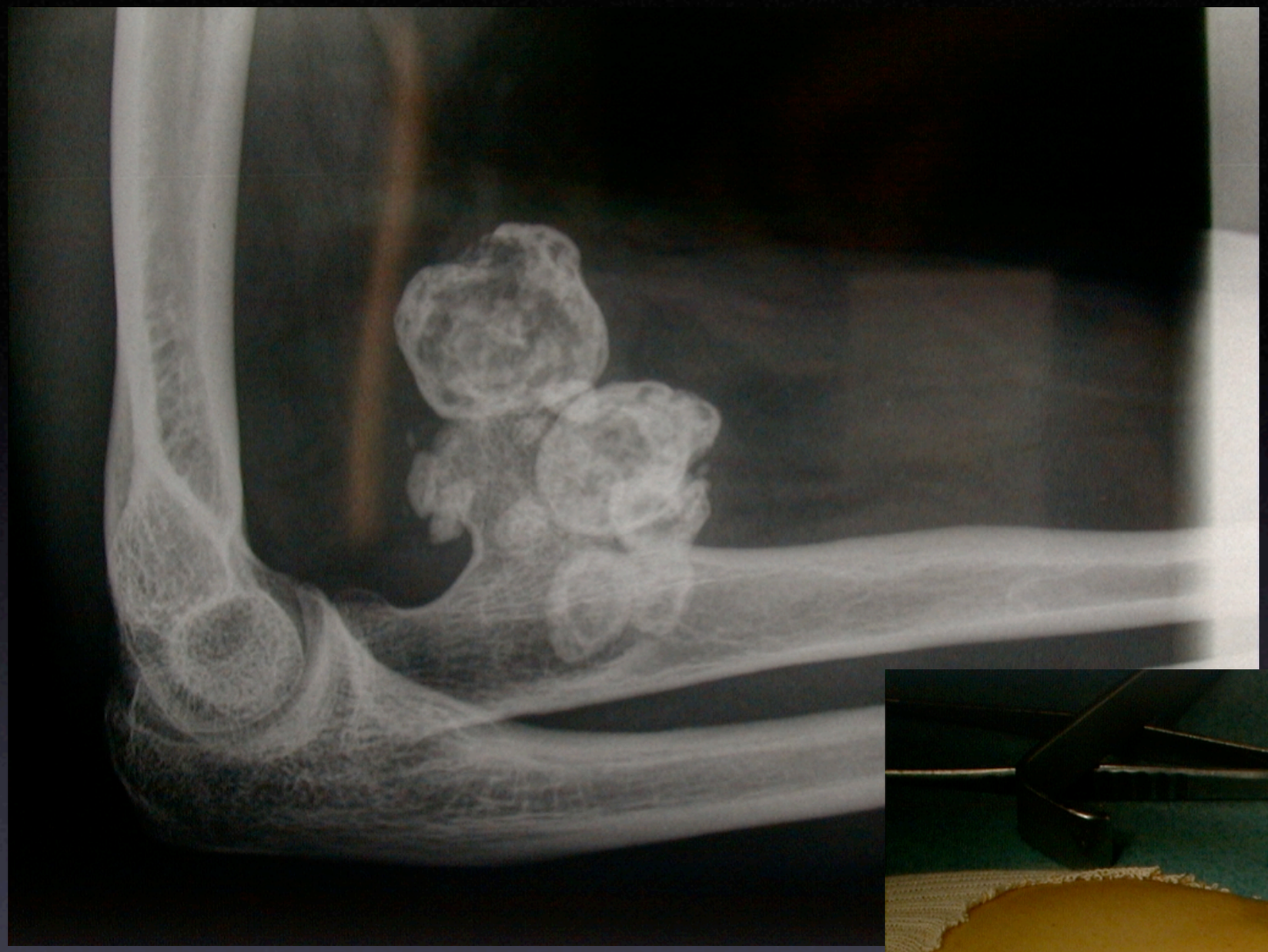

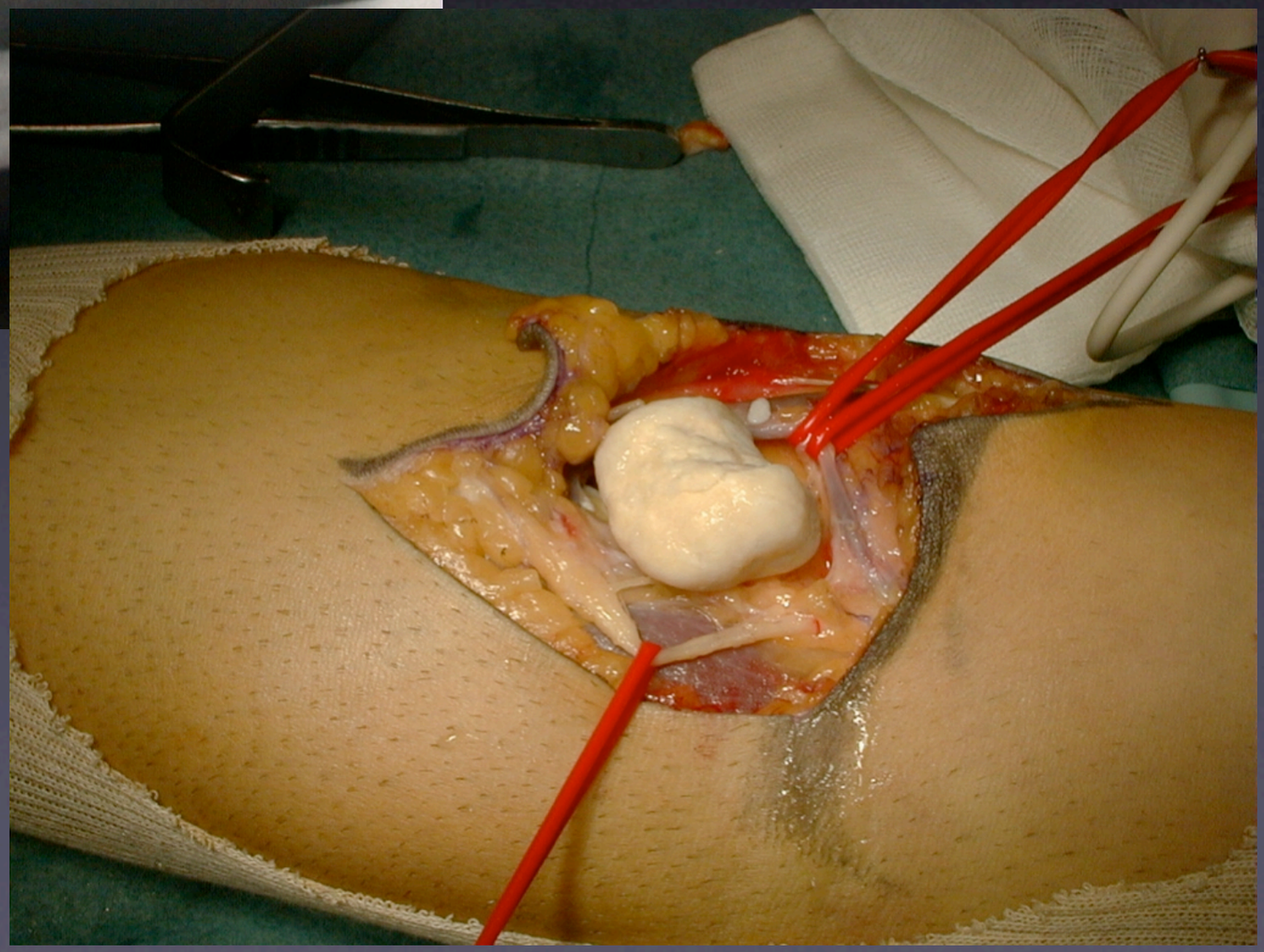

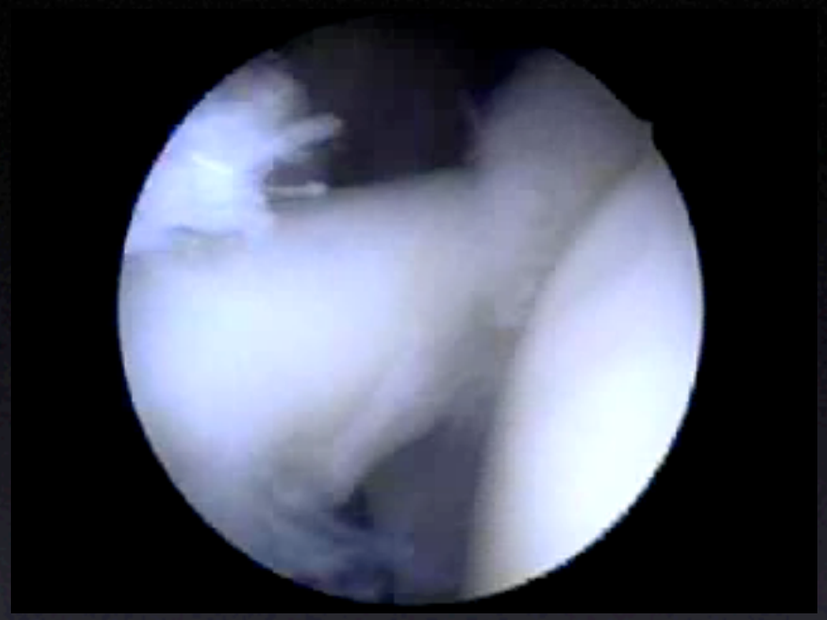

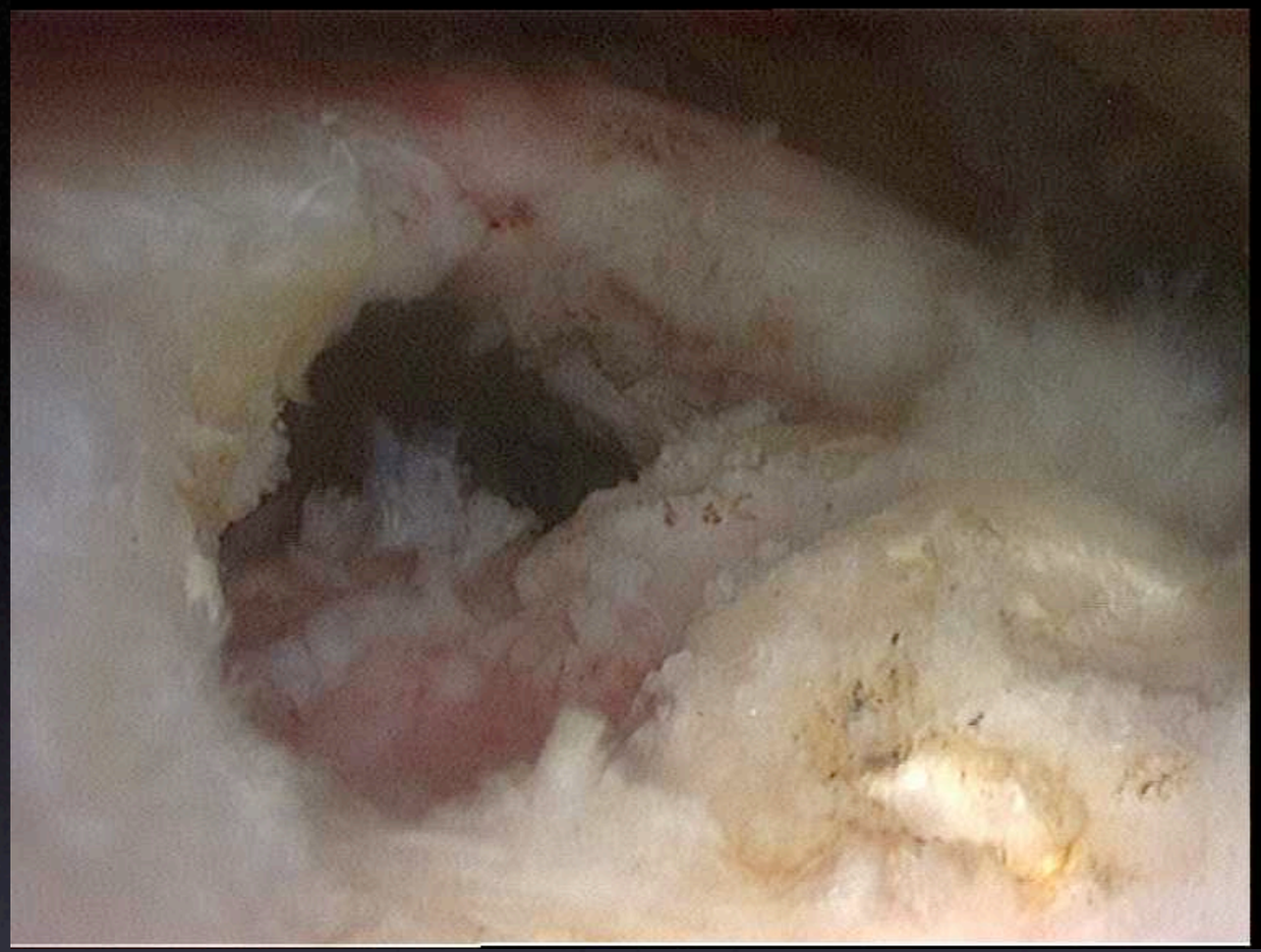

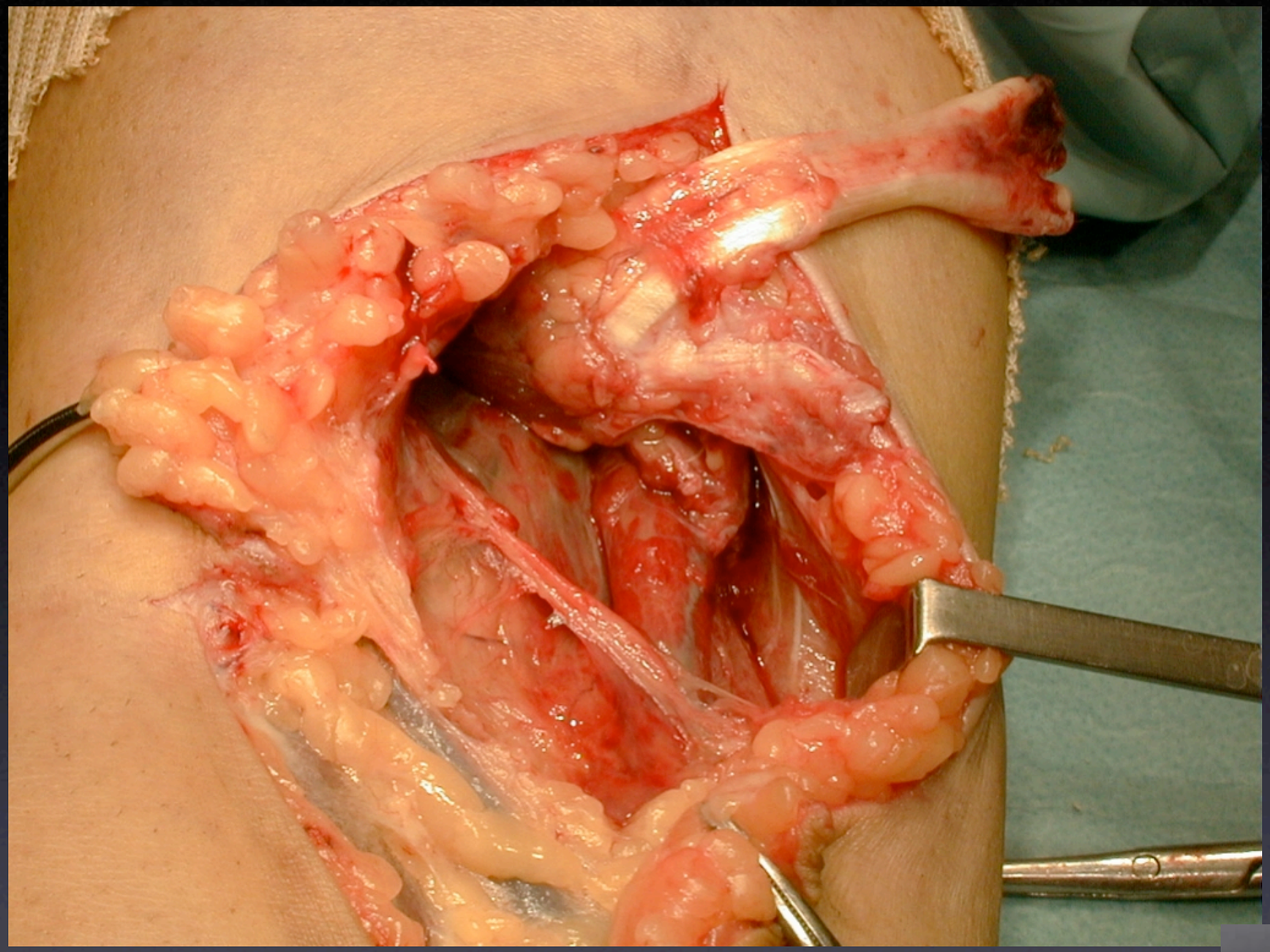

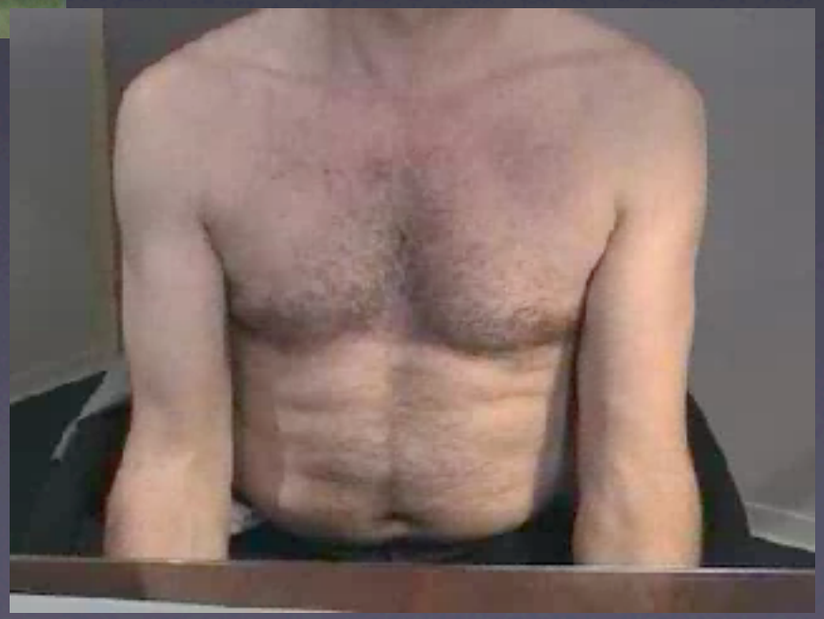

Maladies dégénératives

- Lésions nerveuses
  - Compressions nerveuses
  - Paralysies (infectieuse, toxique, traumatique,...)

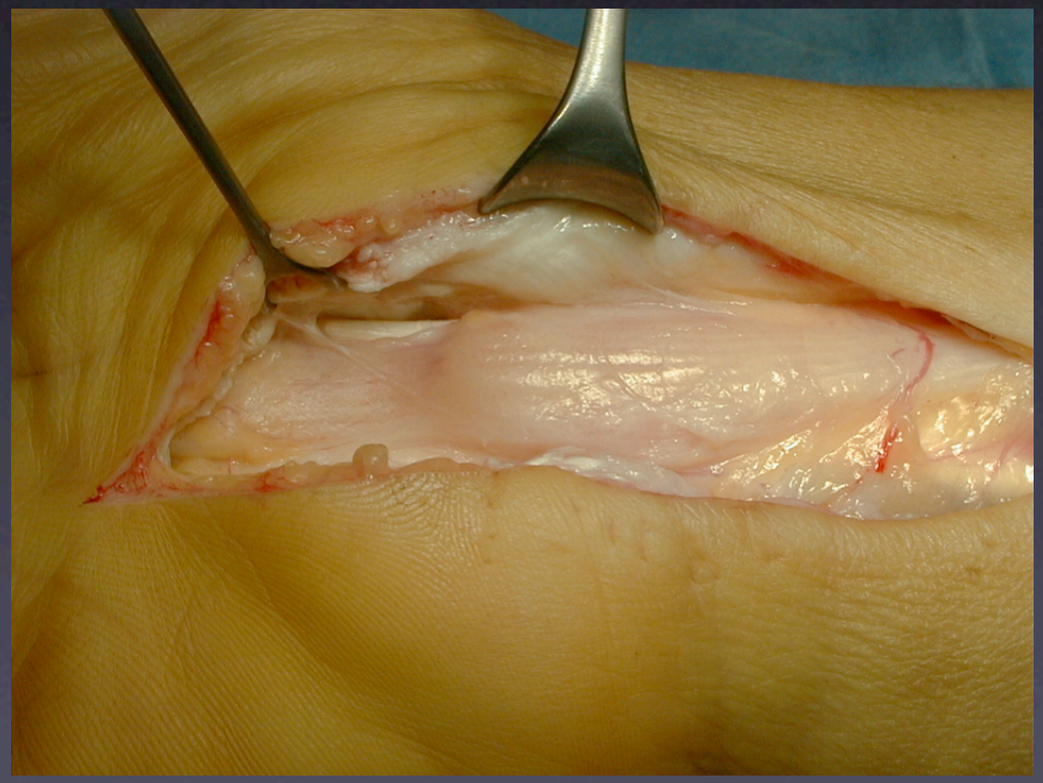

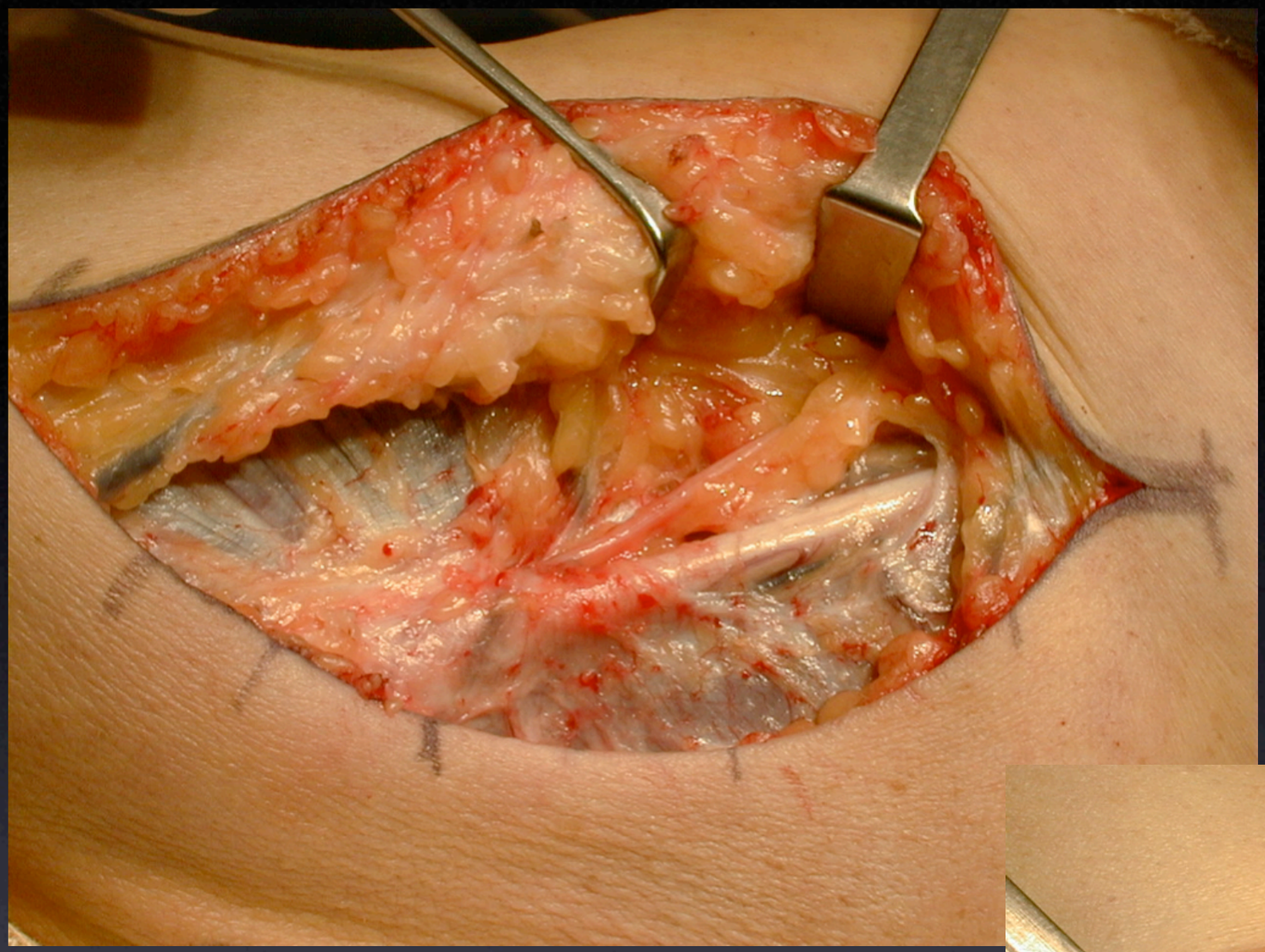

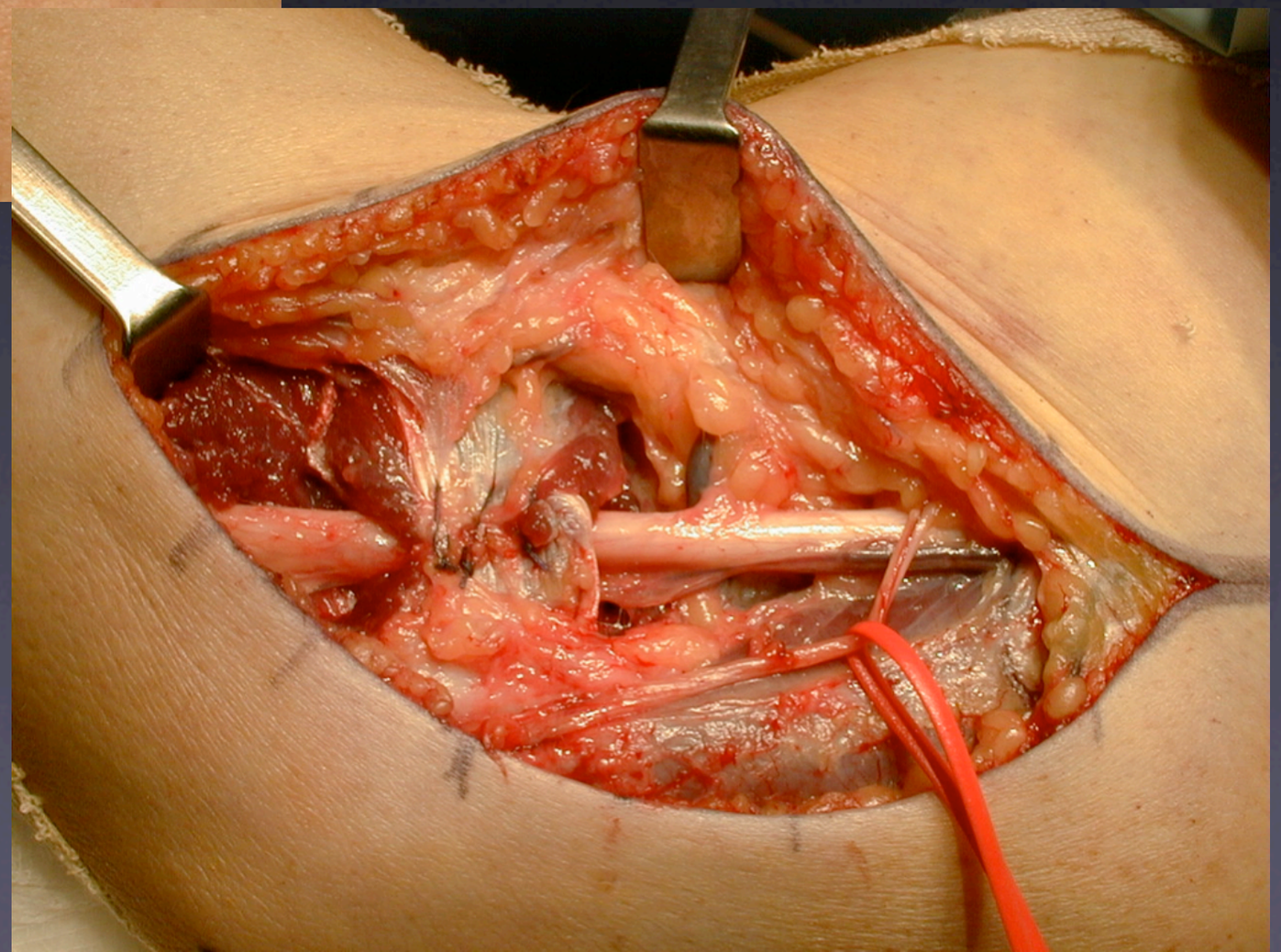

Maladies inflammatoires

- Destruction progressive de l'articulation (des tissus) liée à une prolifération synoviale
- Exemple type: la polyarthrite rhumatoïde

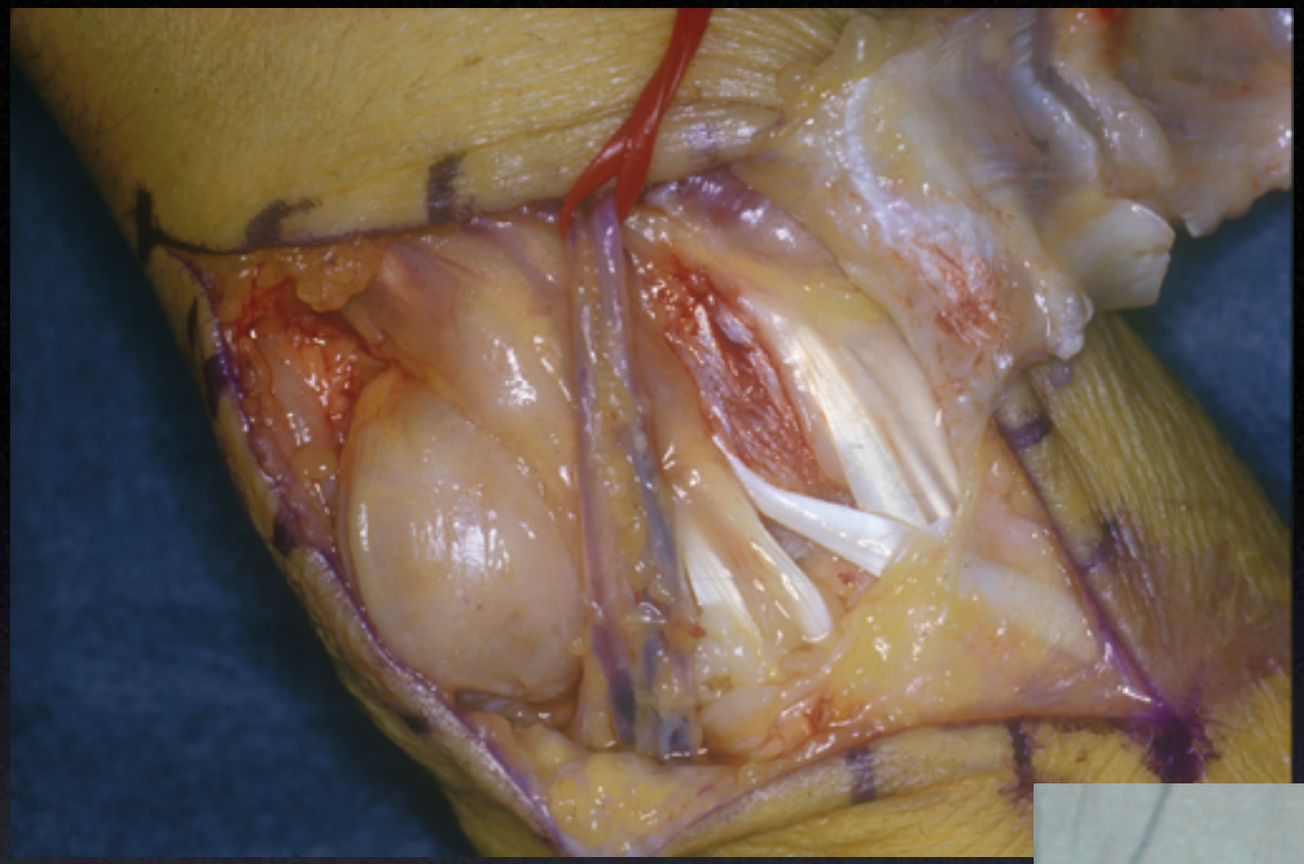

Les tumeurs

- Osseuses
- Cartilagineuses
- Parties molles

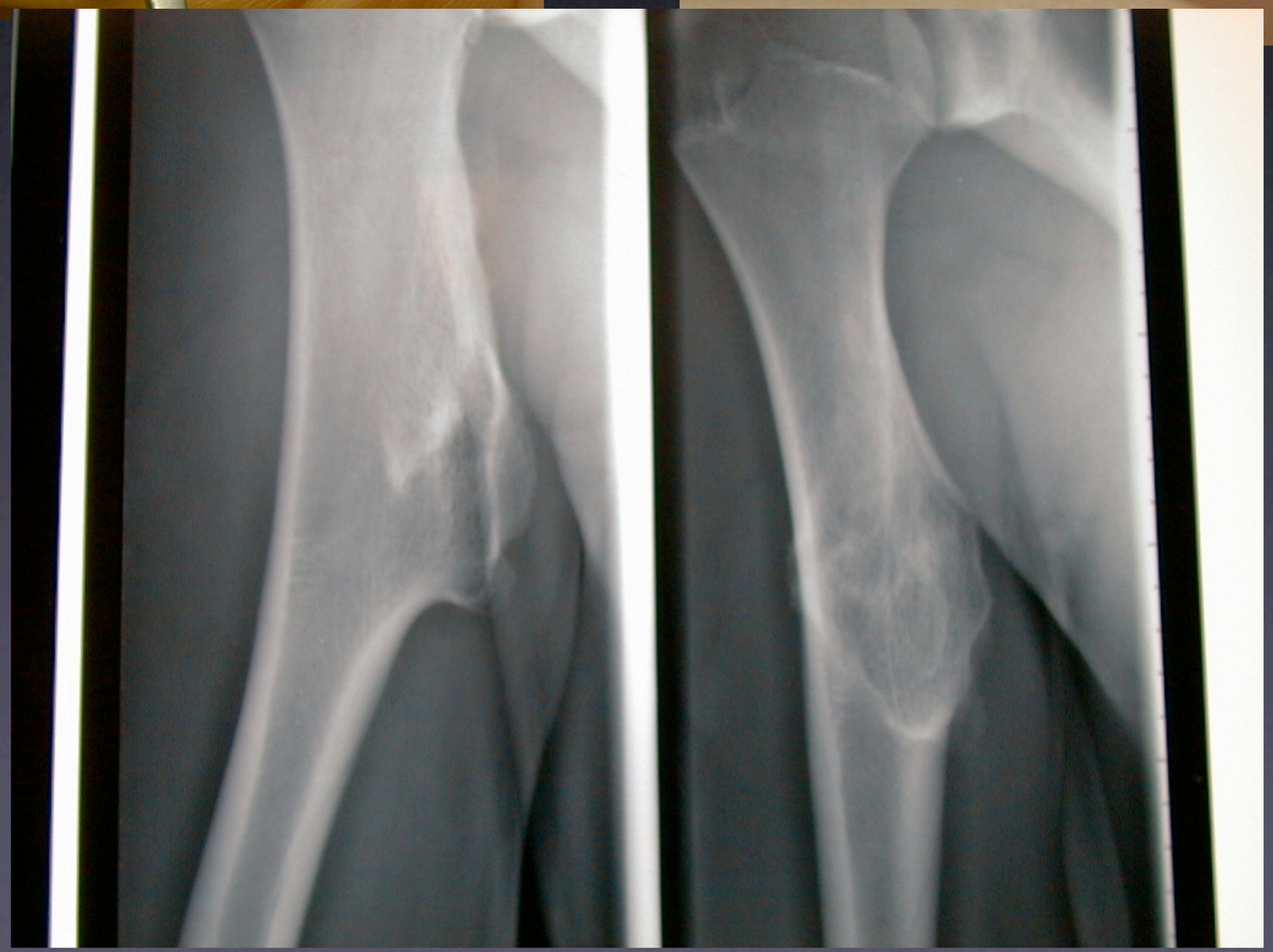

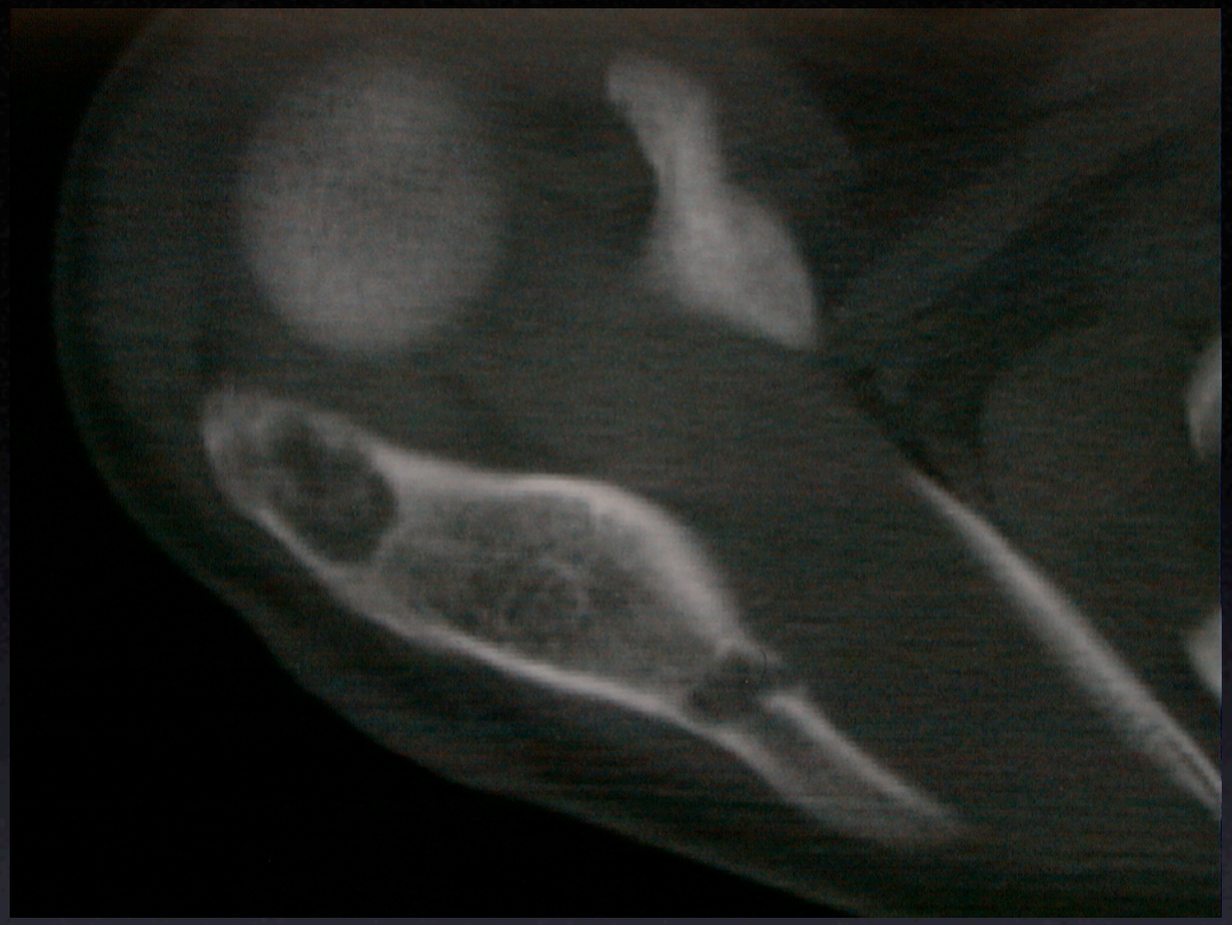

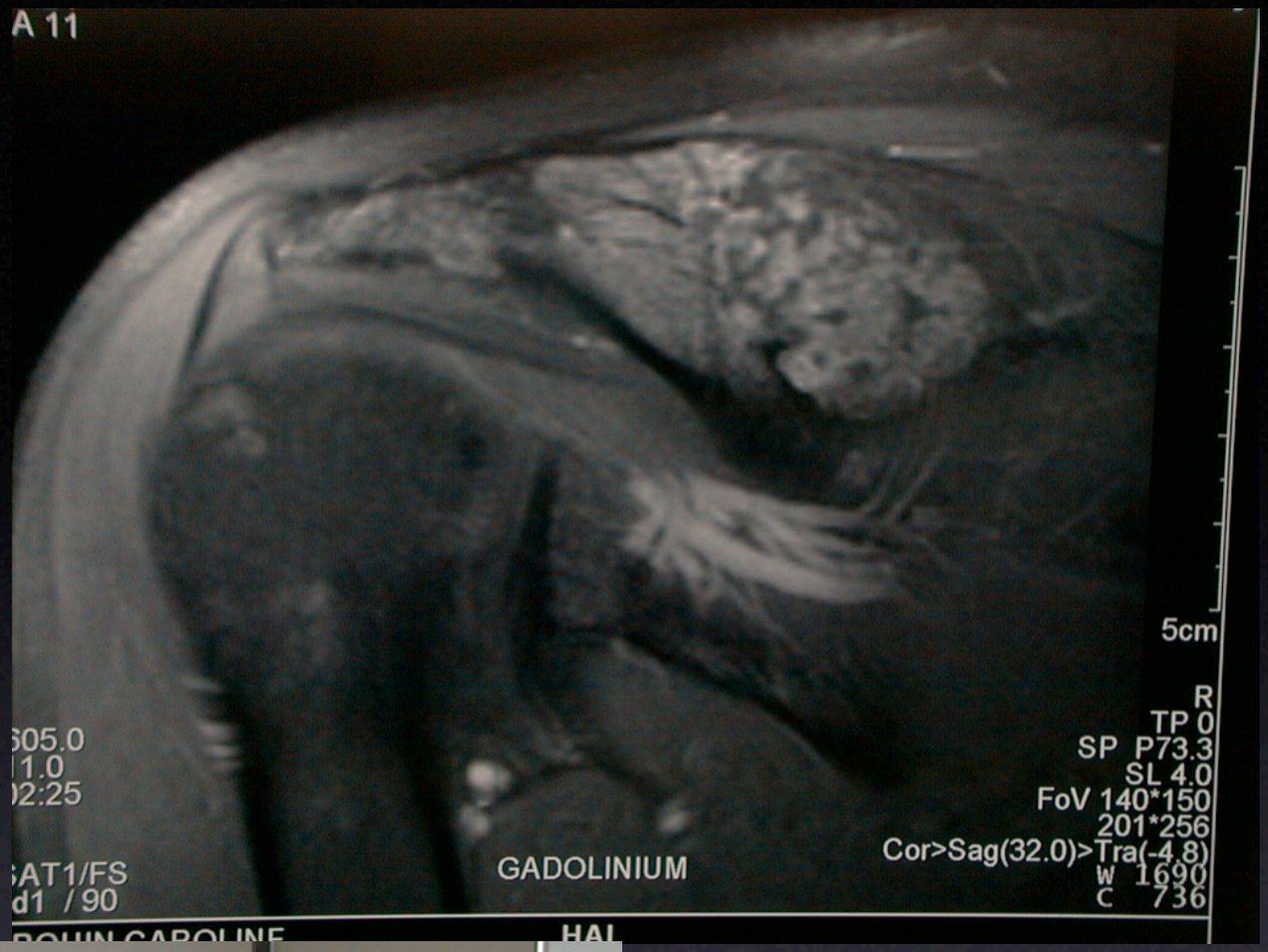
A 11
5cm
R
TP 0
SP P73.3
SL 4.0
FoV 140*150
201*256
Cor>Sag(32.0)>Tra(-4.8)
W 1690
C 736
GADOLINIUM

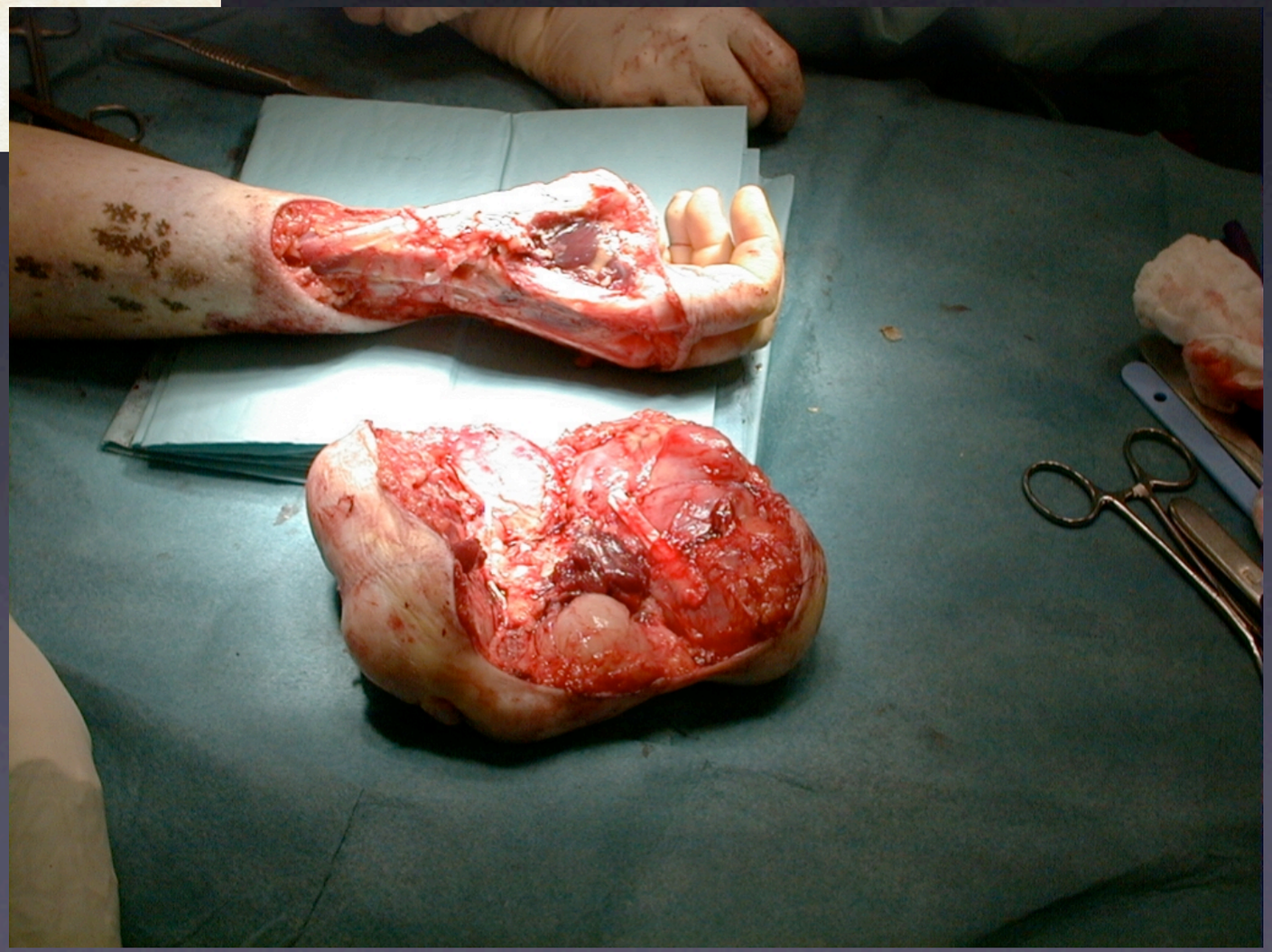

Différences congénitales

- Très variées dans leur expression
  - Isolée ou dans le cadre d'un syndrome
  - Visibles dès la naissance ou ne s'exprimant que tardivement
  - Mettant en jeu le pronostic vital, le pronostic fonctionnel, ou sans aucune conséquence

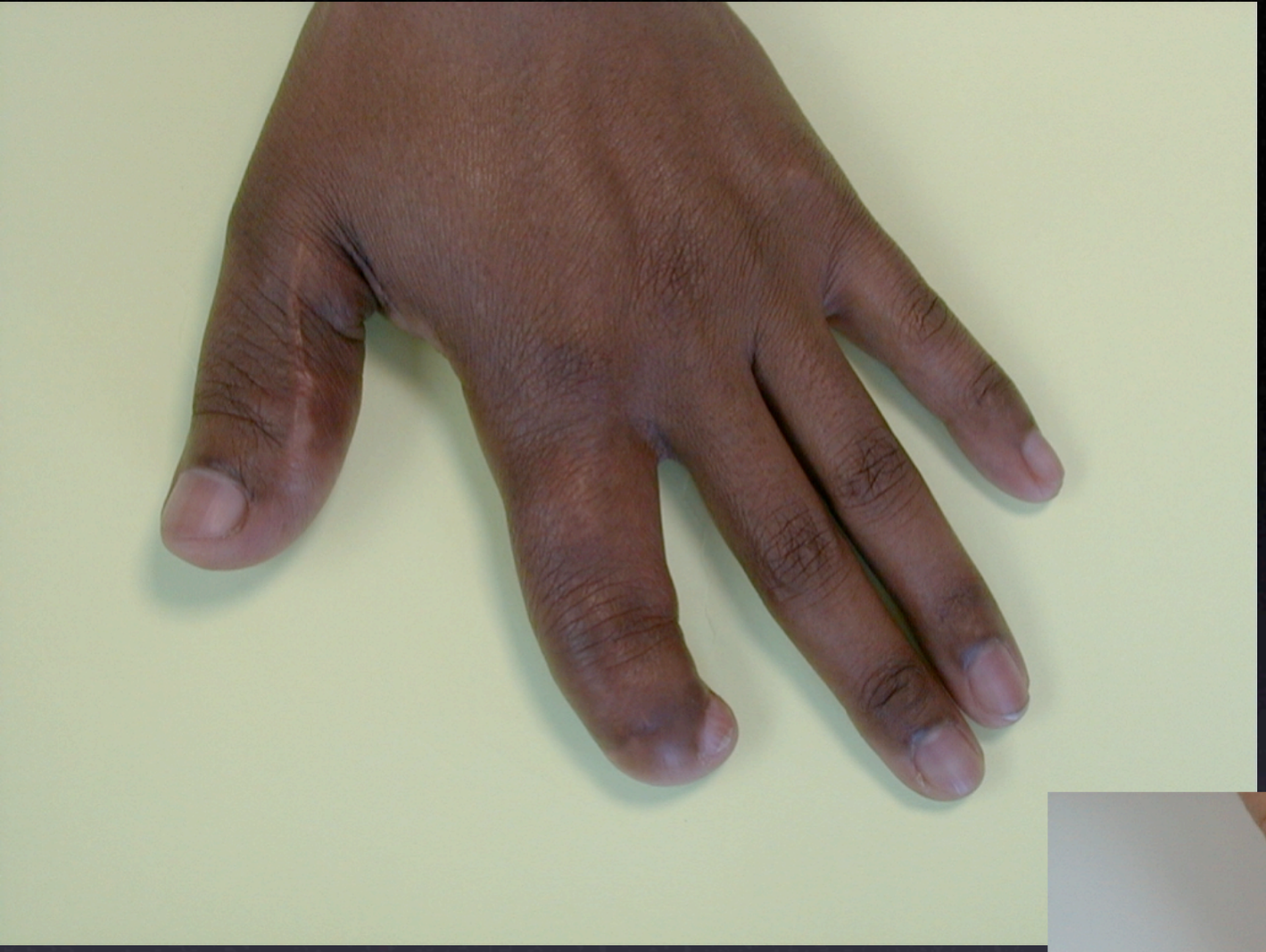

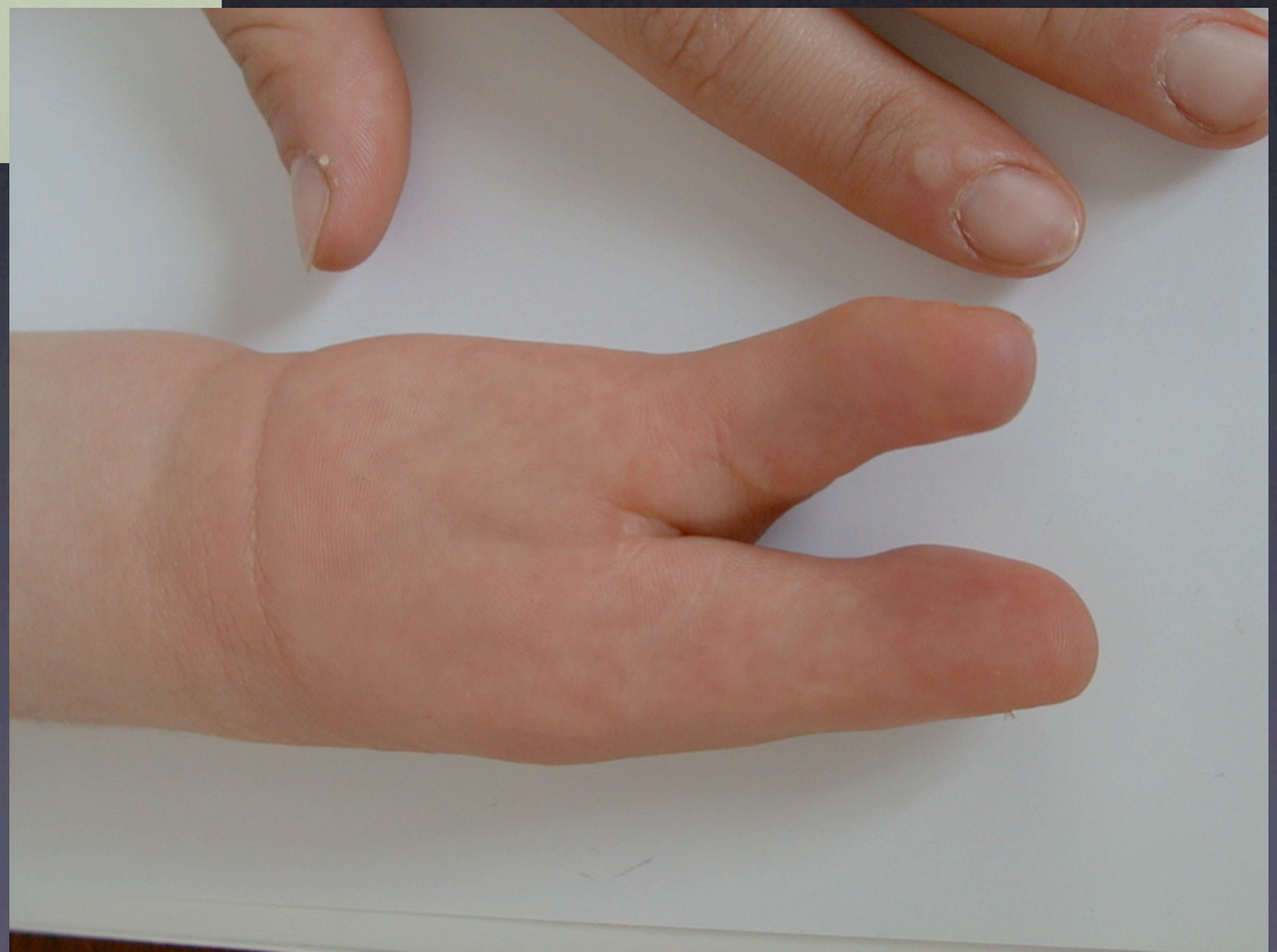

Traumatologie

- Toutes les lésions traumatiques et leurs séquelles
  - Lésions osseuses ou ostéo-articulaires
  - Lésions des parties molles (plaies surtout)

Traumatologie osté-articulaire

- Contusions
- Entorses
- Luxations
- Fractures

Fractures

- Ouvertes / Fermées
- Non déplacées / Déplacées
- Articulaires / Diaphysai

- **Traumatismes directs**
  - **Fractures transversales, comminutives**
  - **Contusions, lésions des parties molles**
- **Traumatismes indirects**
  - **Torsions**
    - **Fractures spiroïdes**

Ouverture cutanée

- de dedans en dehors
- de dehors en dedans
- **3 stades**

Risque septique ++

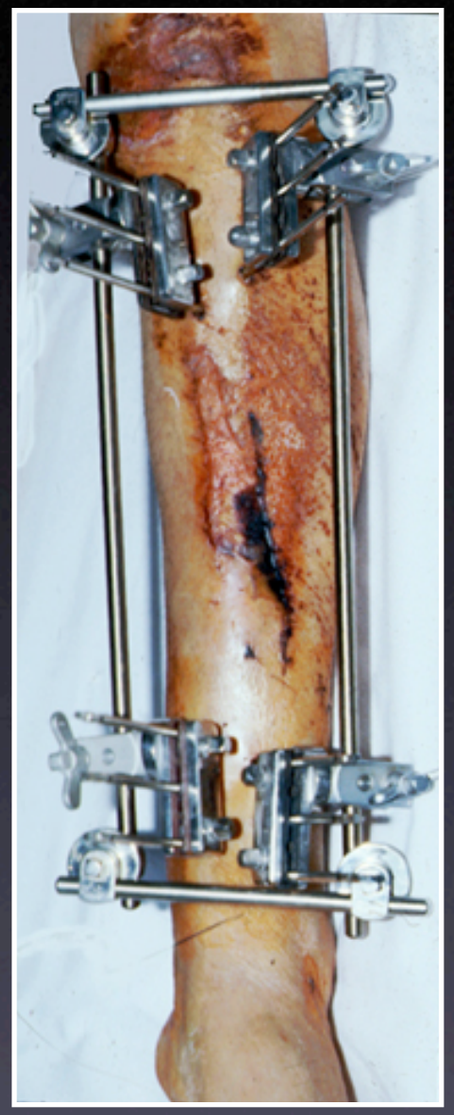

Stade 1 **Stade 2** **Stade 3**

Plaie simple sans décollement **Bords excisés suture simple** **Perte de substance**

1

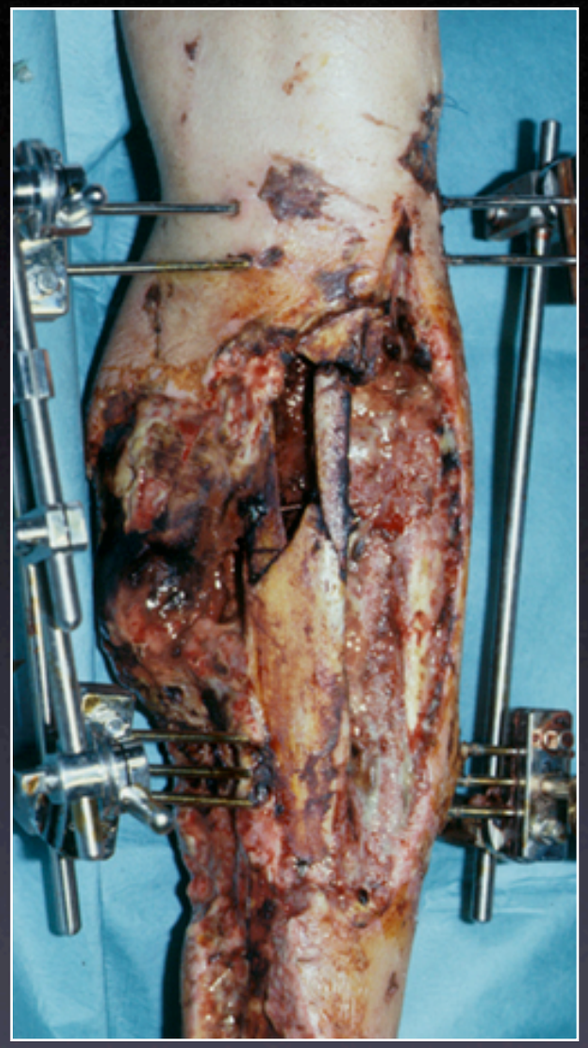

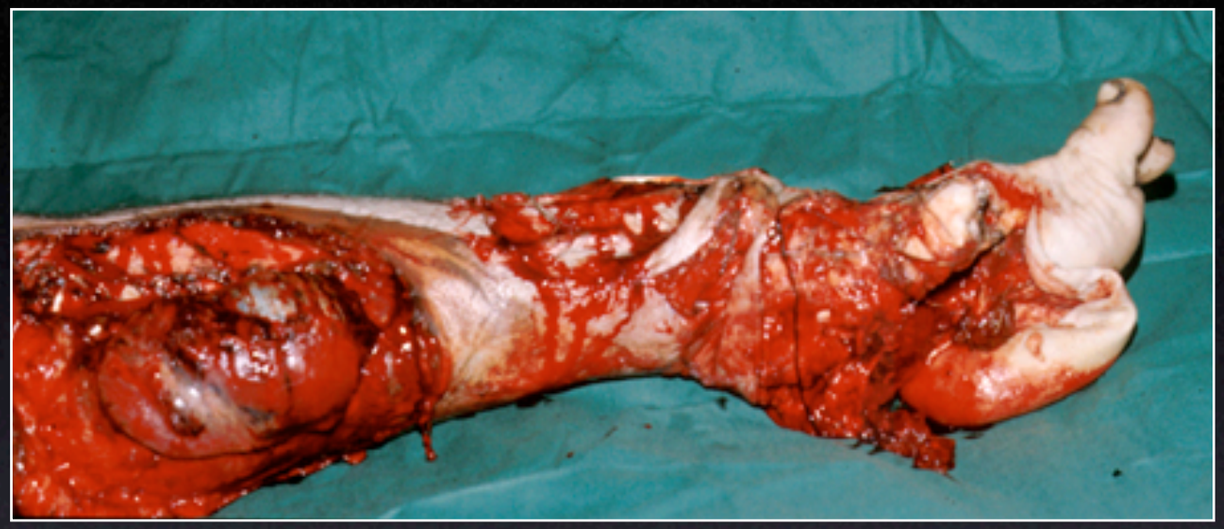

Risque de « crush injury »

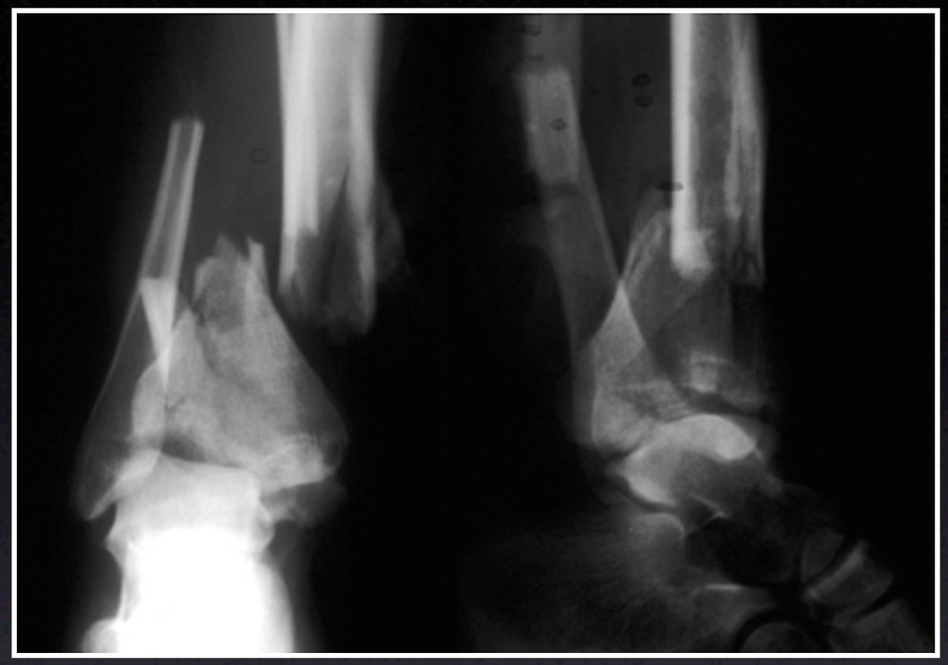

Fractures

- Ouvertes / Fermées
- Non déplacées / Déplacées
- Articulaires / Diaphysaires

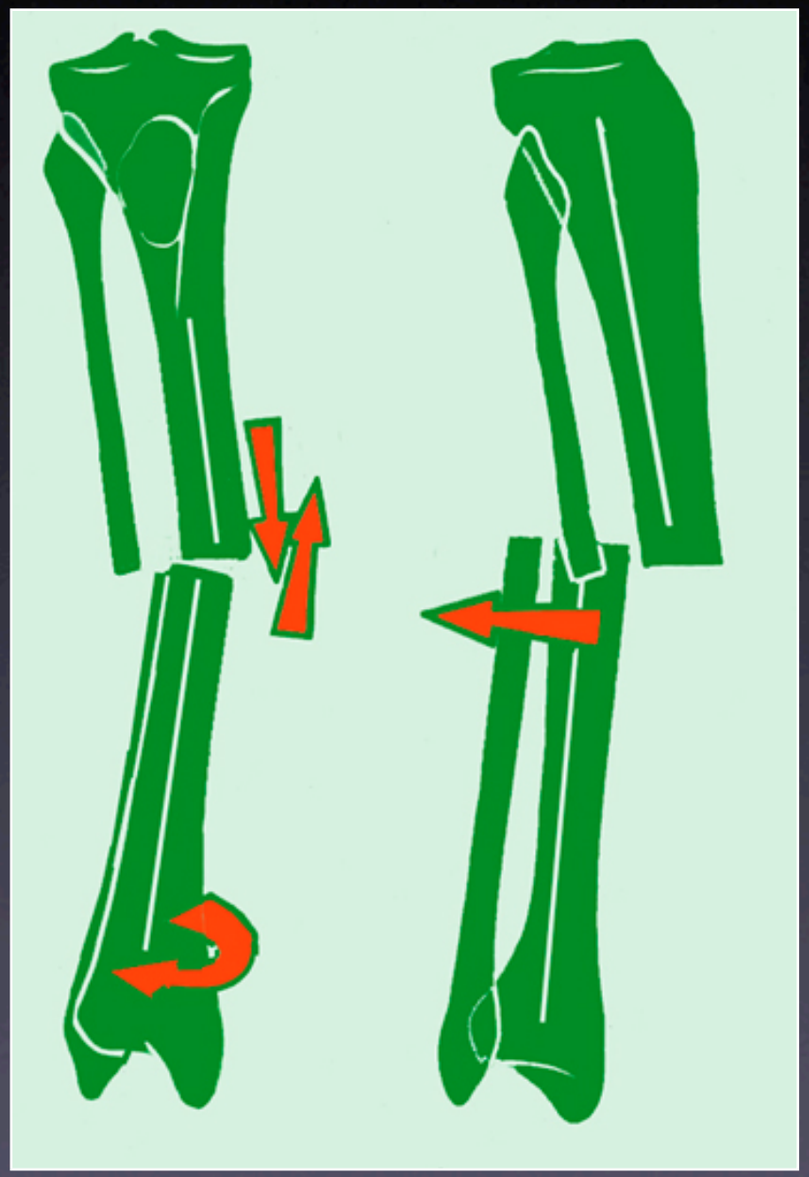

Déplacement

- Angulation
- Rotation
- Translation
- Chevauchement

Fracture métaphysaire basse des 2 os de la jambe très déplacée

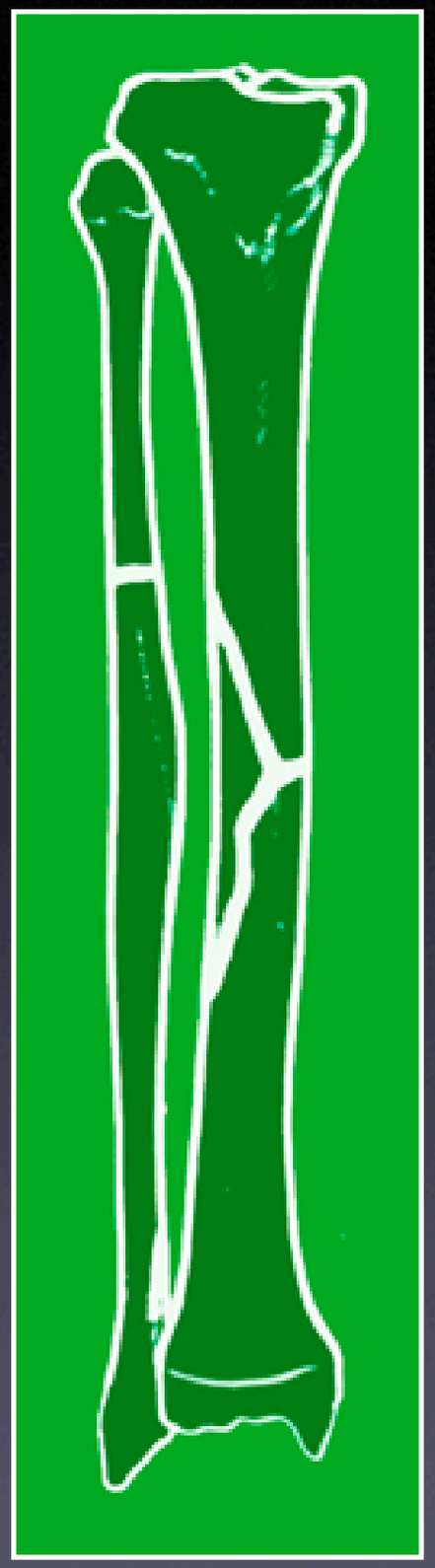



Traits de fracture ± longs - Déplacement en rotation



Chocs directs

Lésions cutanées

Lésions des parties molles :

muscles

vaisseaux

nerfs


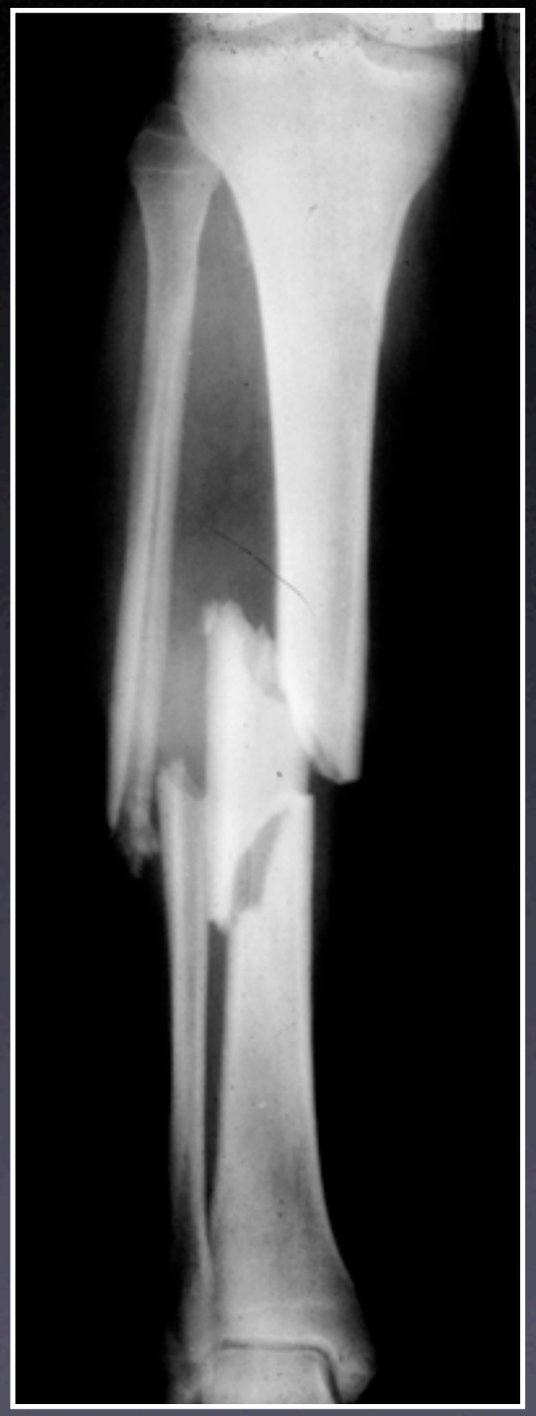

[0701]Cheville, Profil
DRR: E:0.1 S:0.1 K:201 W/L:52/52 G:1
1.6 MODE: A 0003
TRAORE, DROFILA [M]
1903050501
01-mar-1977

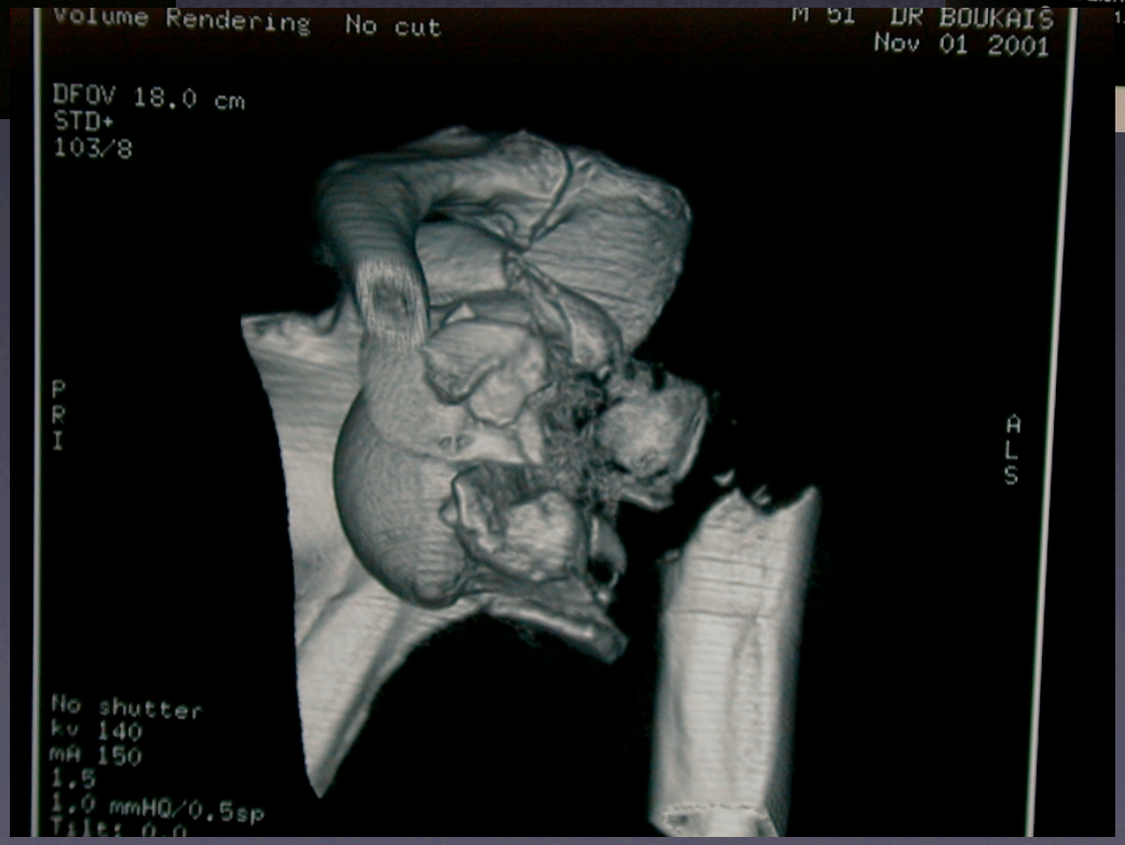
Volume Rendering No cut
M 51 DR BOUKAIS
Nov 01 2001
DFOV 18.0 cm
STD+
103/8
P
R
I
A
L
S
No shutter
kv 140
mA 150
1.5
1.0 mmHQ/0.5sp

Fractures métaphysaires

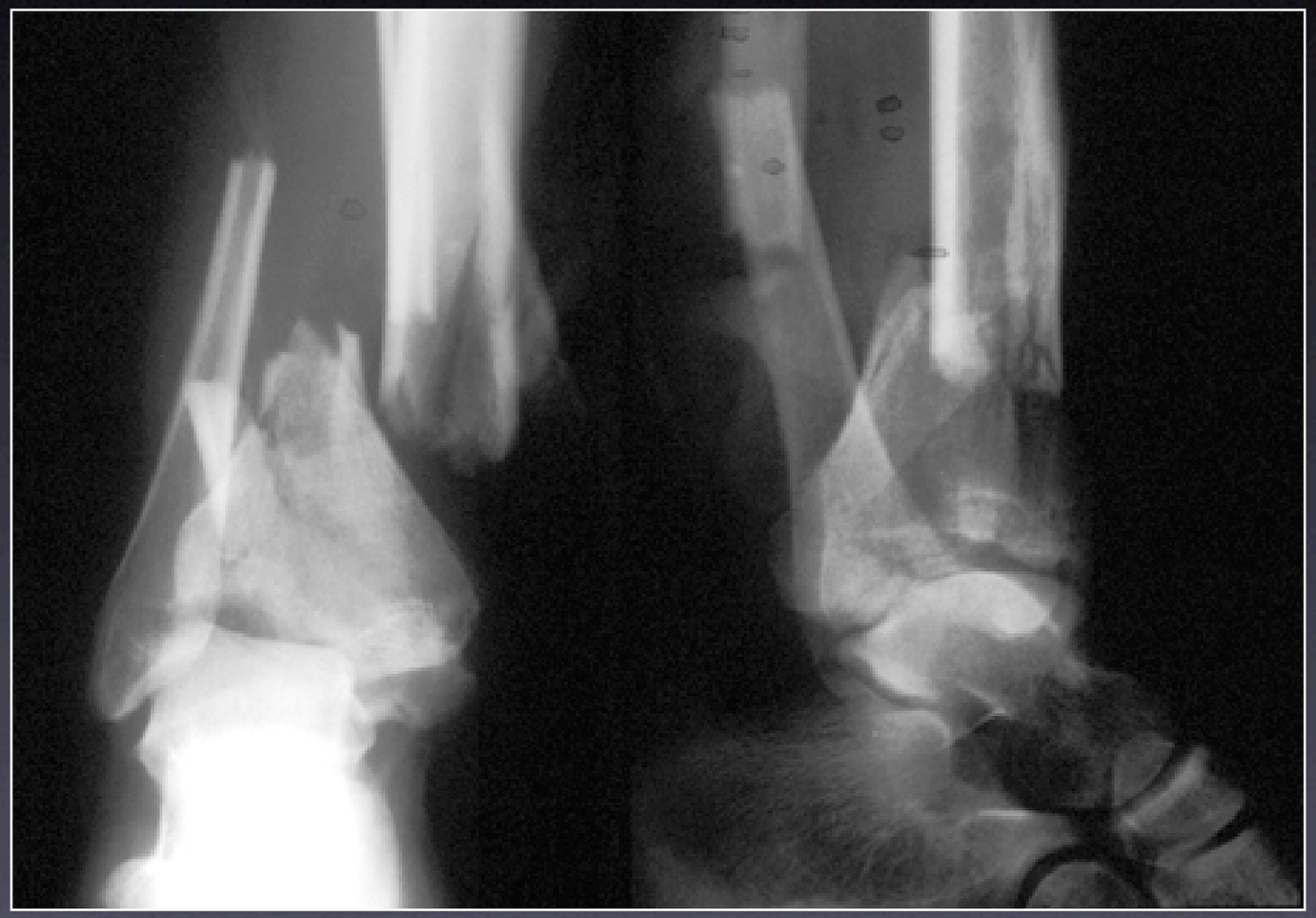

- Ouvertes / Fermées
- Non déplacées / Déplacées
- Articulaires / Diaphysaires

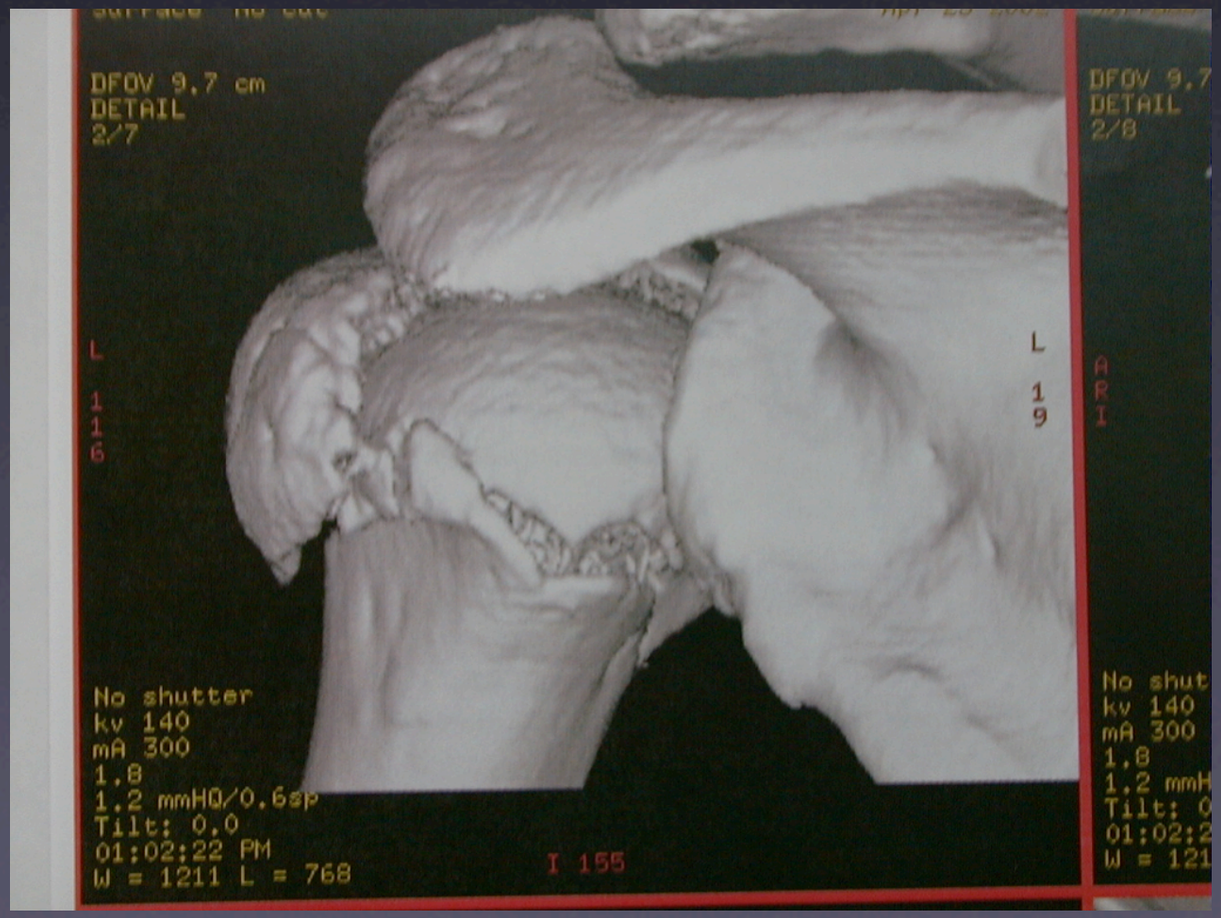

Fractures

- Articulaires
  - Retentissement fonctionnel (raideur, arthrose), peu de problèmes de consolidation
- Diaphysaires
  - Difficulté (+/- grande) de consolidation

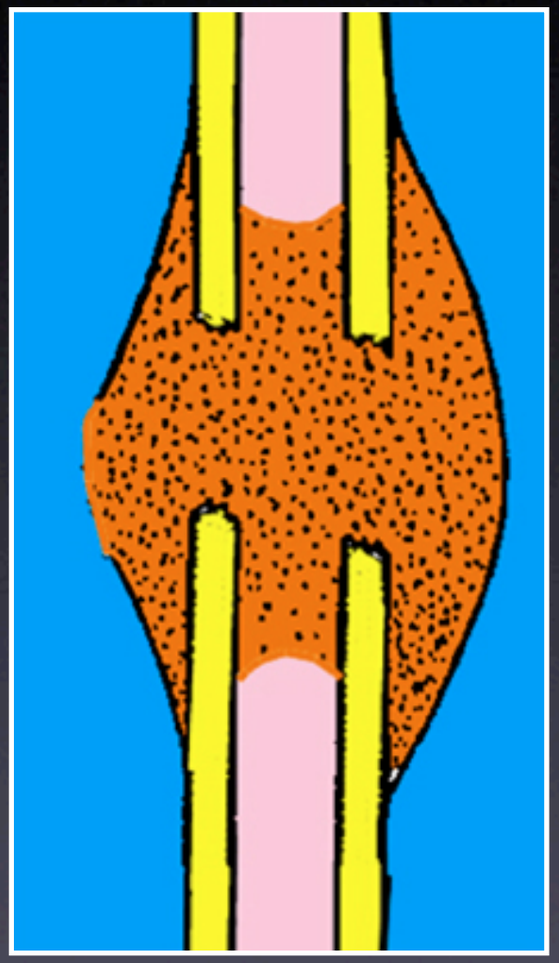



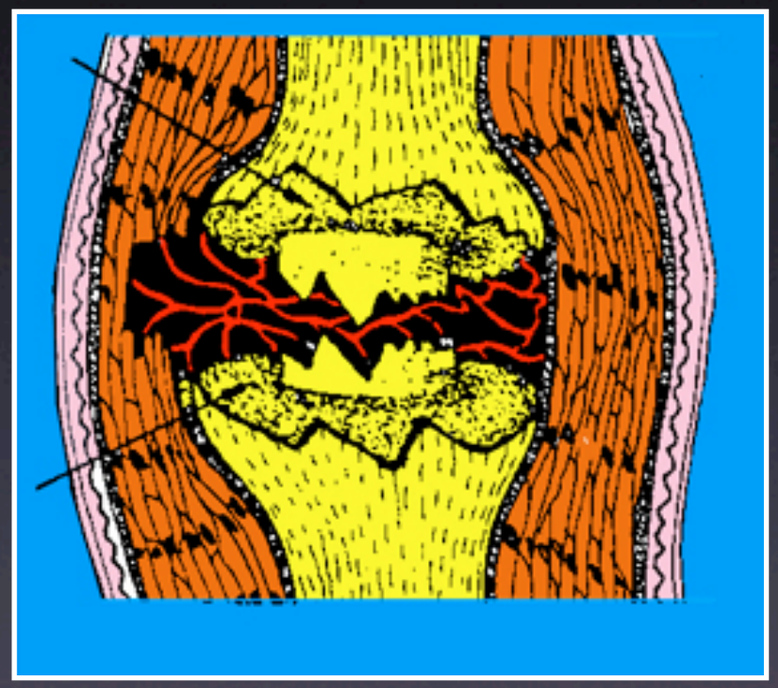



1- Hématome

Réaction inflammatoire

2- Cal conjonctif

Apport vasculaire

3- Ossification du cal

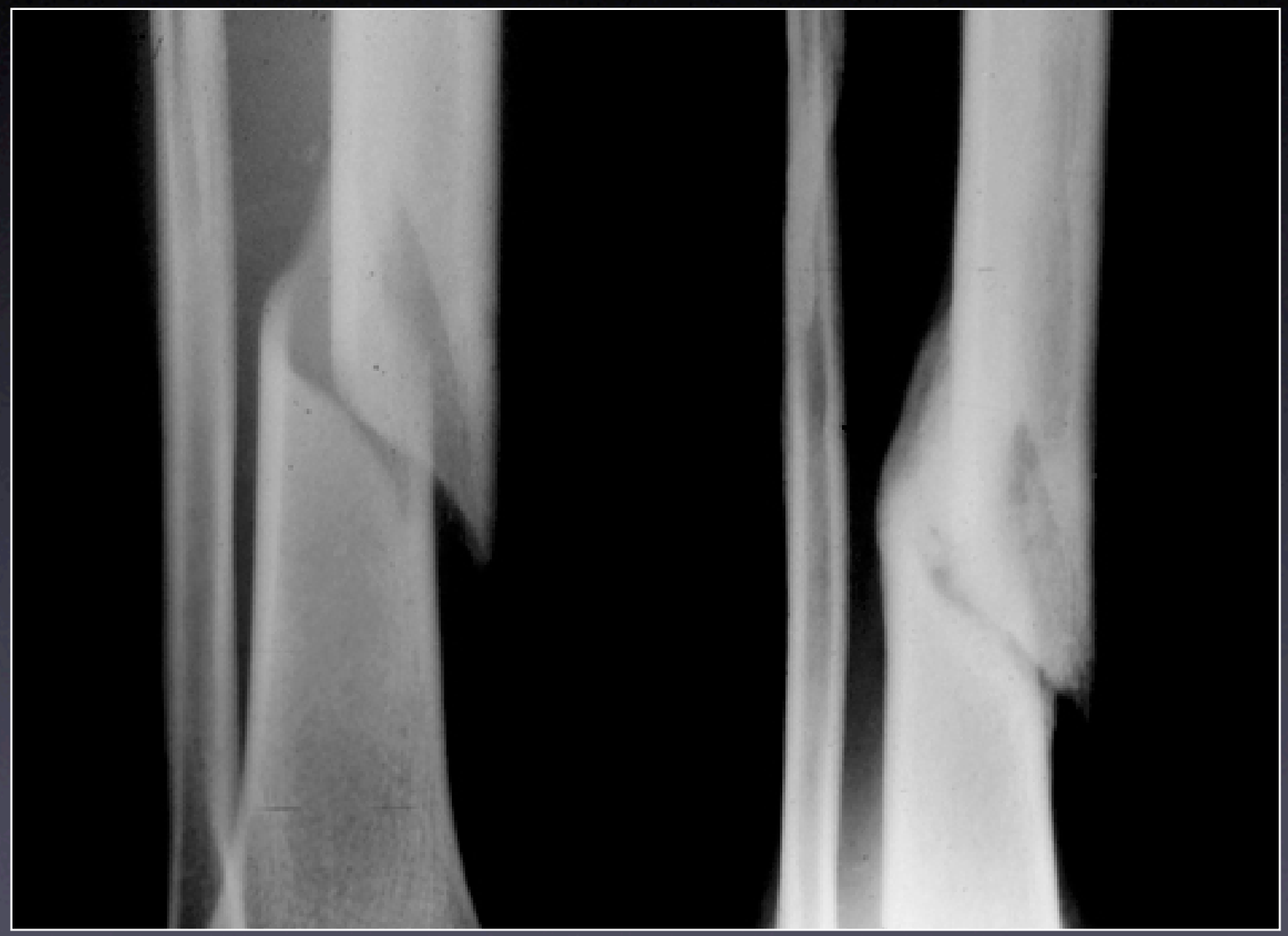

Facteurs limitant la consolidation

- **L'âge**
- **La localisation à la diaphyse**
- **L'ouverture cutanée**
- **L'évacuation de l'hématome péri-fracturaire**
- **L'immobilisation insuffisante du foyer**
- **L'interposition musculaire**

Plaies des parties molles

- Plaies des nerfs
- Plaies des vaisseaux
- Plaies des tendons
- Plaies des muscles
- Lésions cutanées

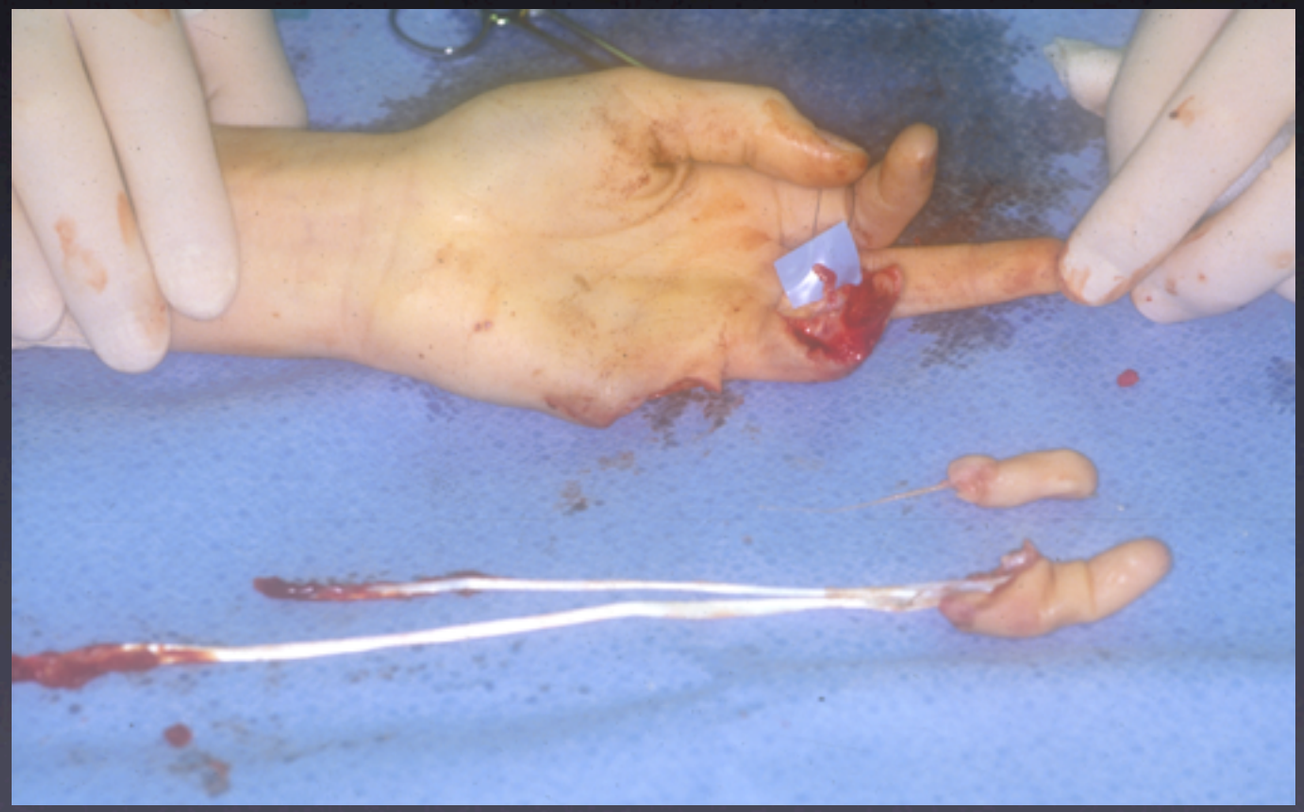

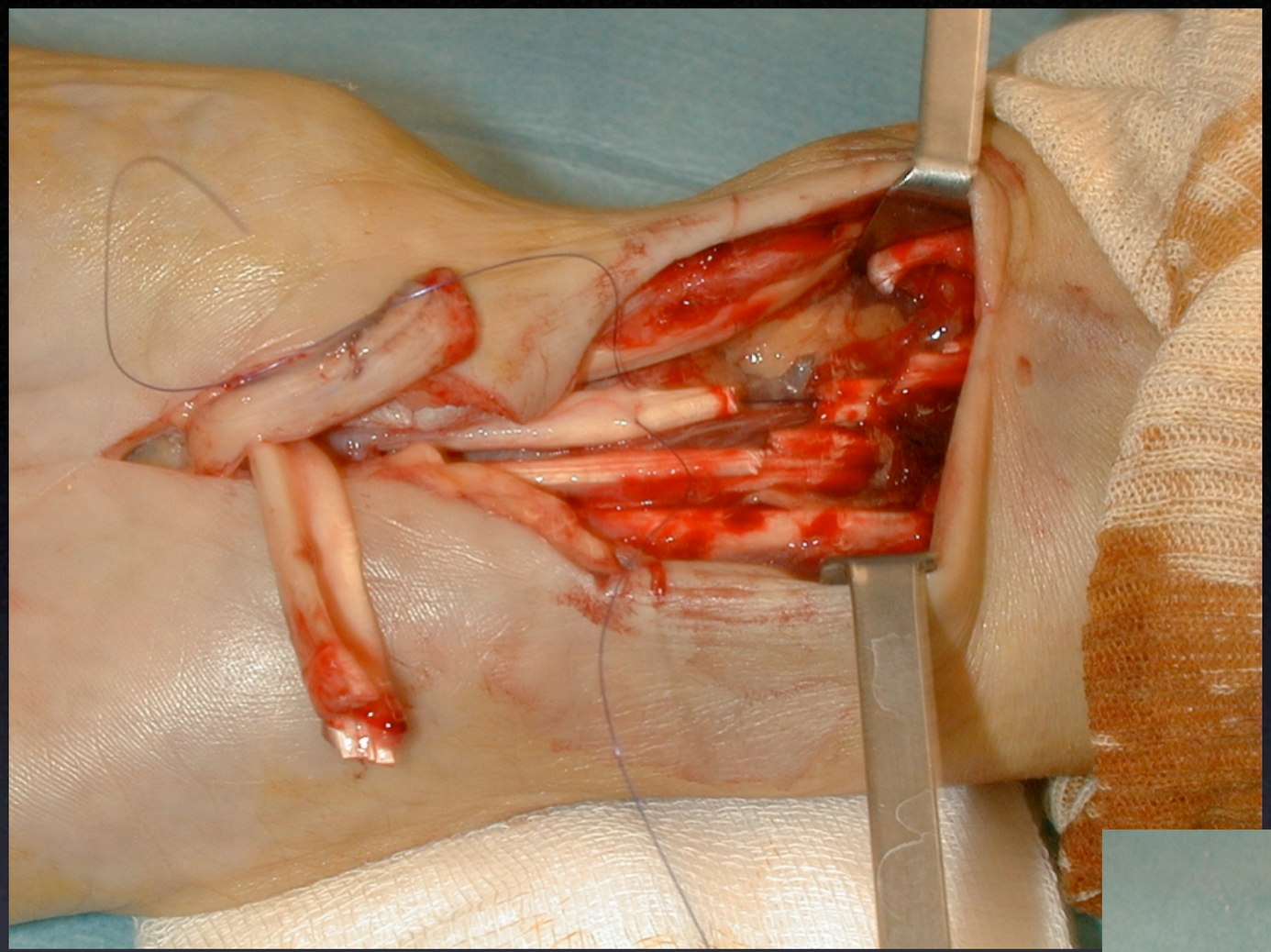

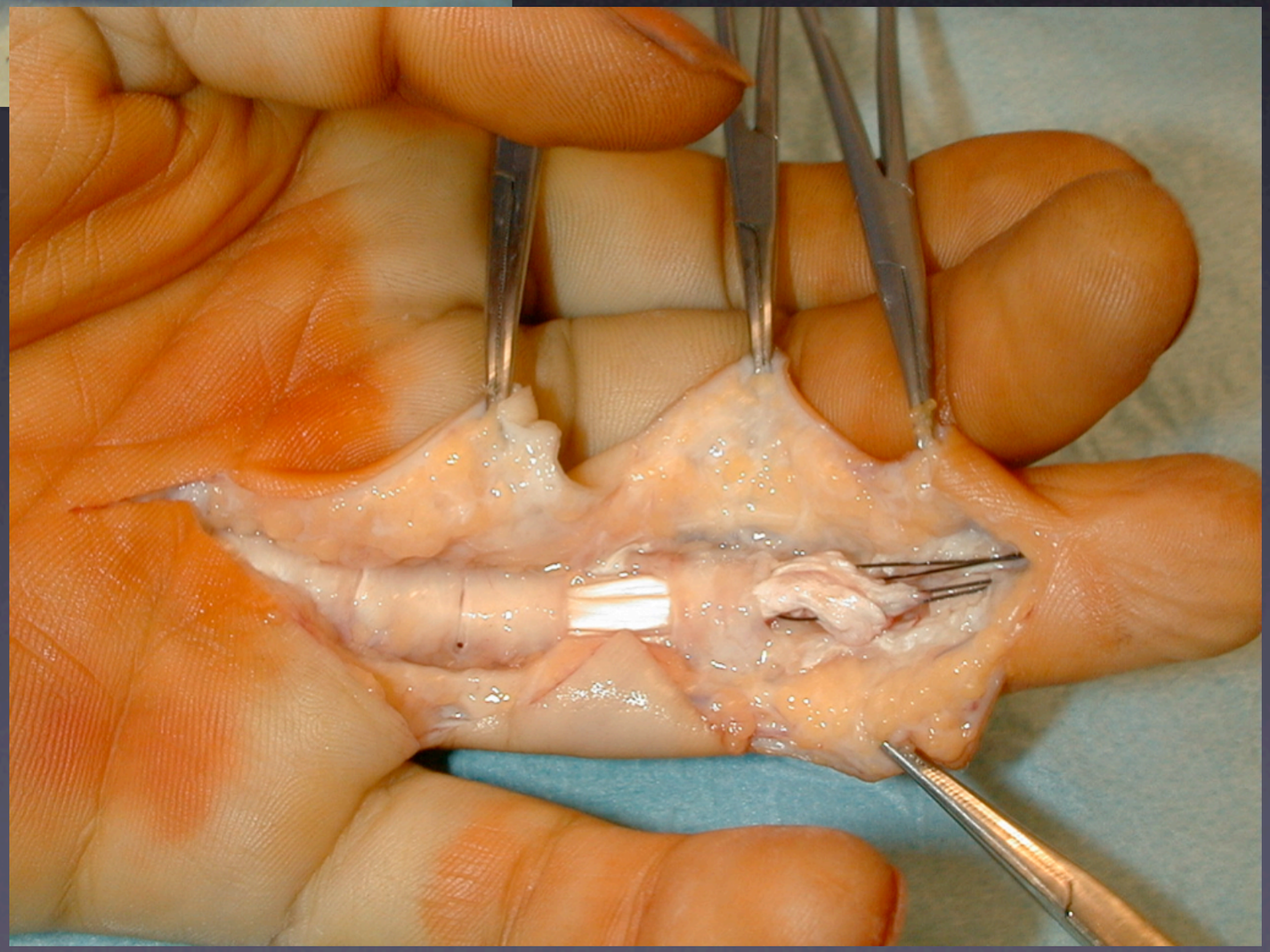

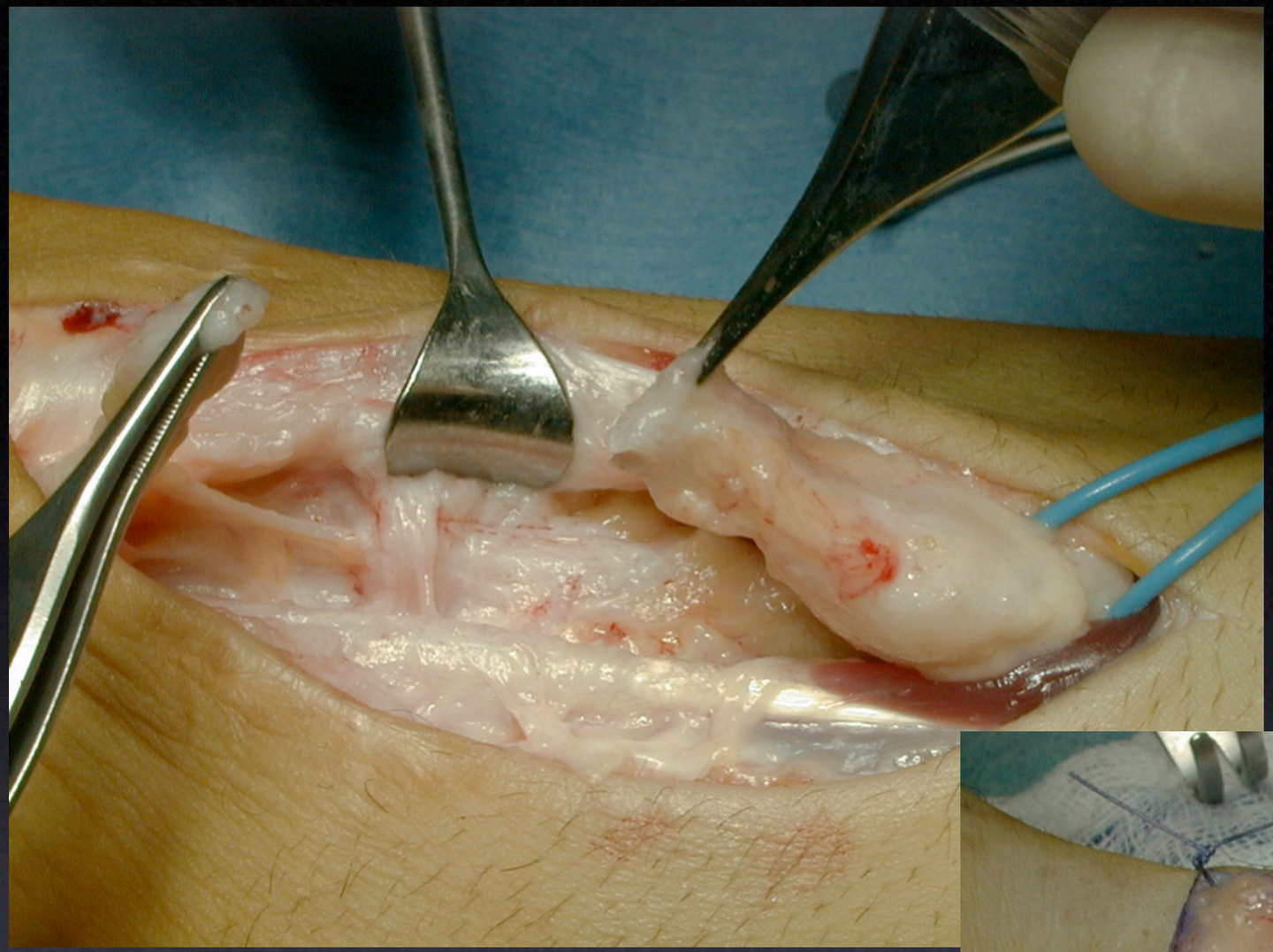

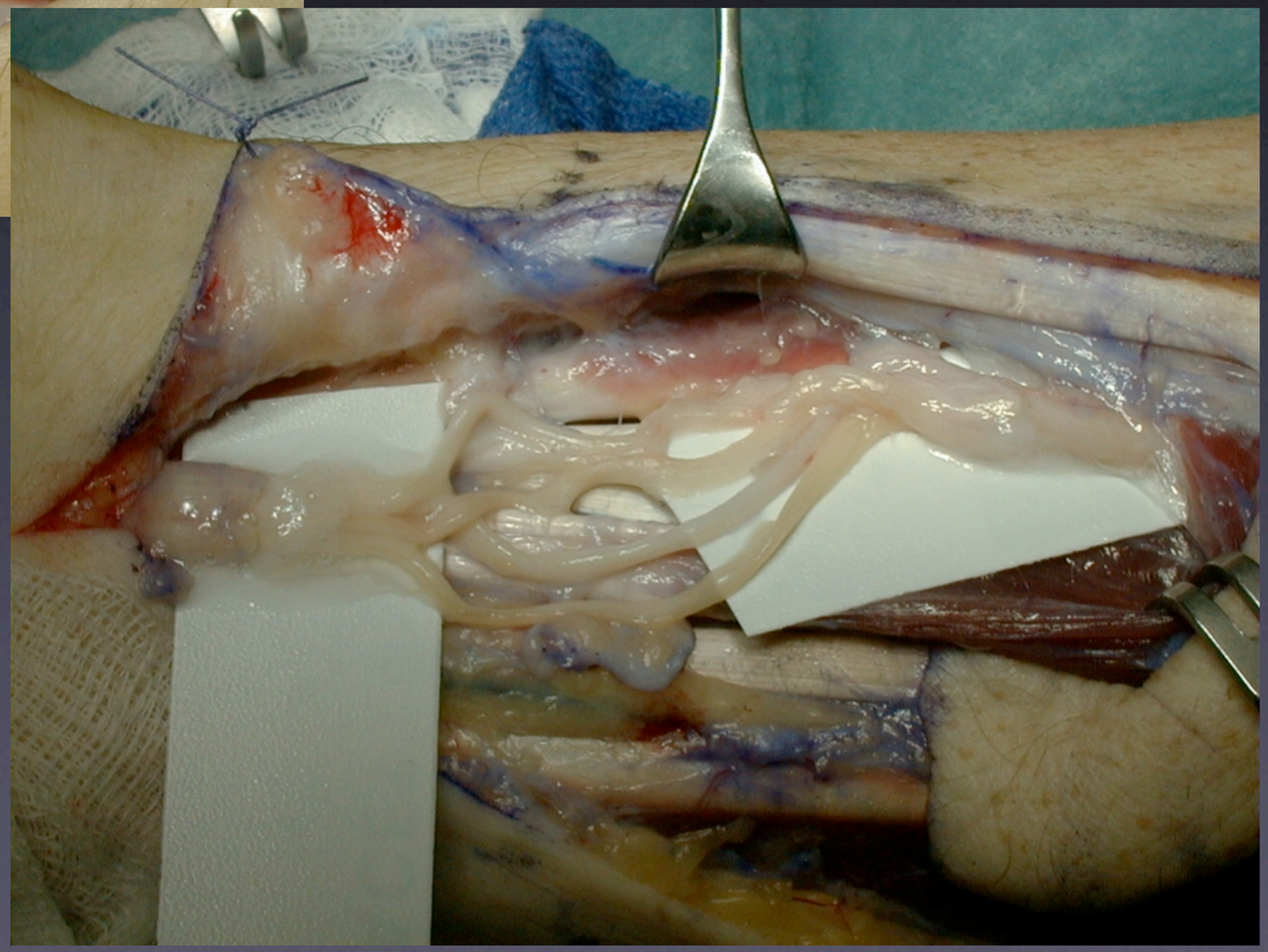

Les traitements en orthopédie

- Fonctionnel : la rééducation
- Médicamenteux
- Orthopédiques (semelles, attelles, orthèses, plâtre,...)
- Chirurgicaux (sutures des parties molles, ostéosynthèse, prothèses)

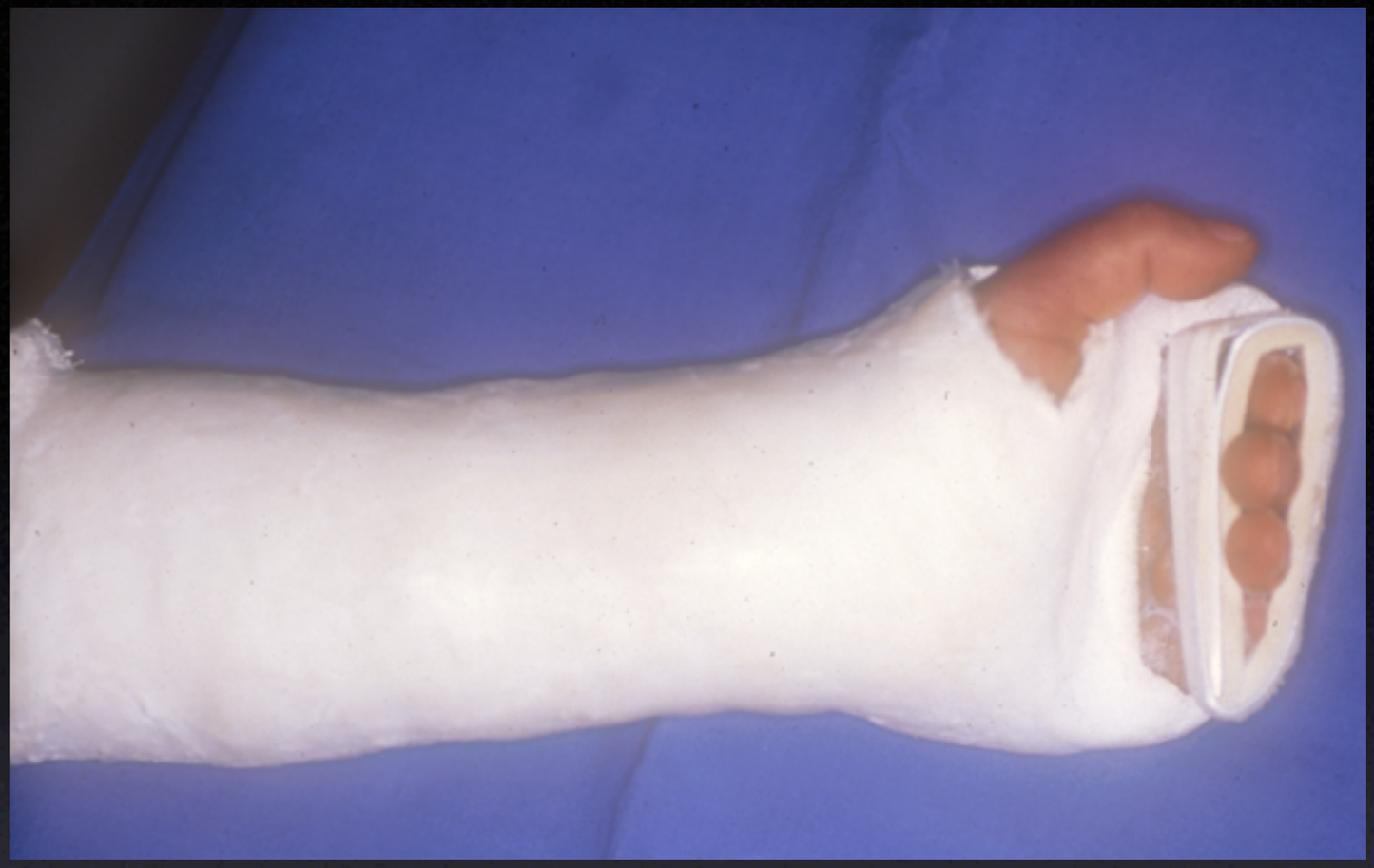

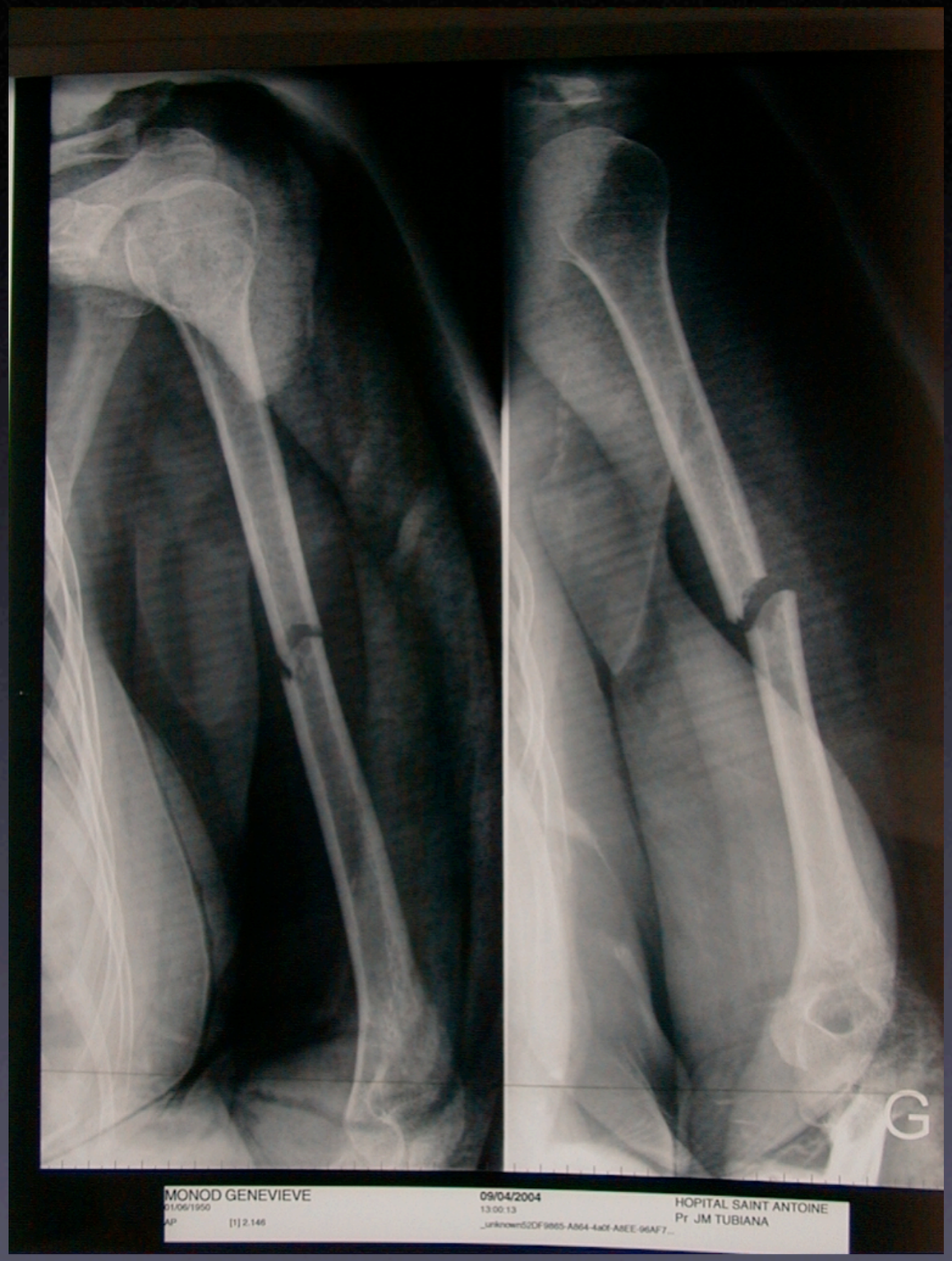
G
MONOD GENEVIEVE
01/06/1950
AP
[1] 2.146
09/04/2004
13:00:13
HOPITAL SAINT ANTOINE
Pr JM TUBIANA

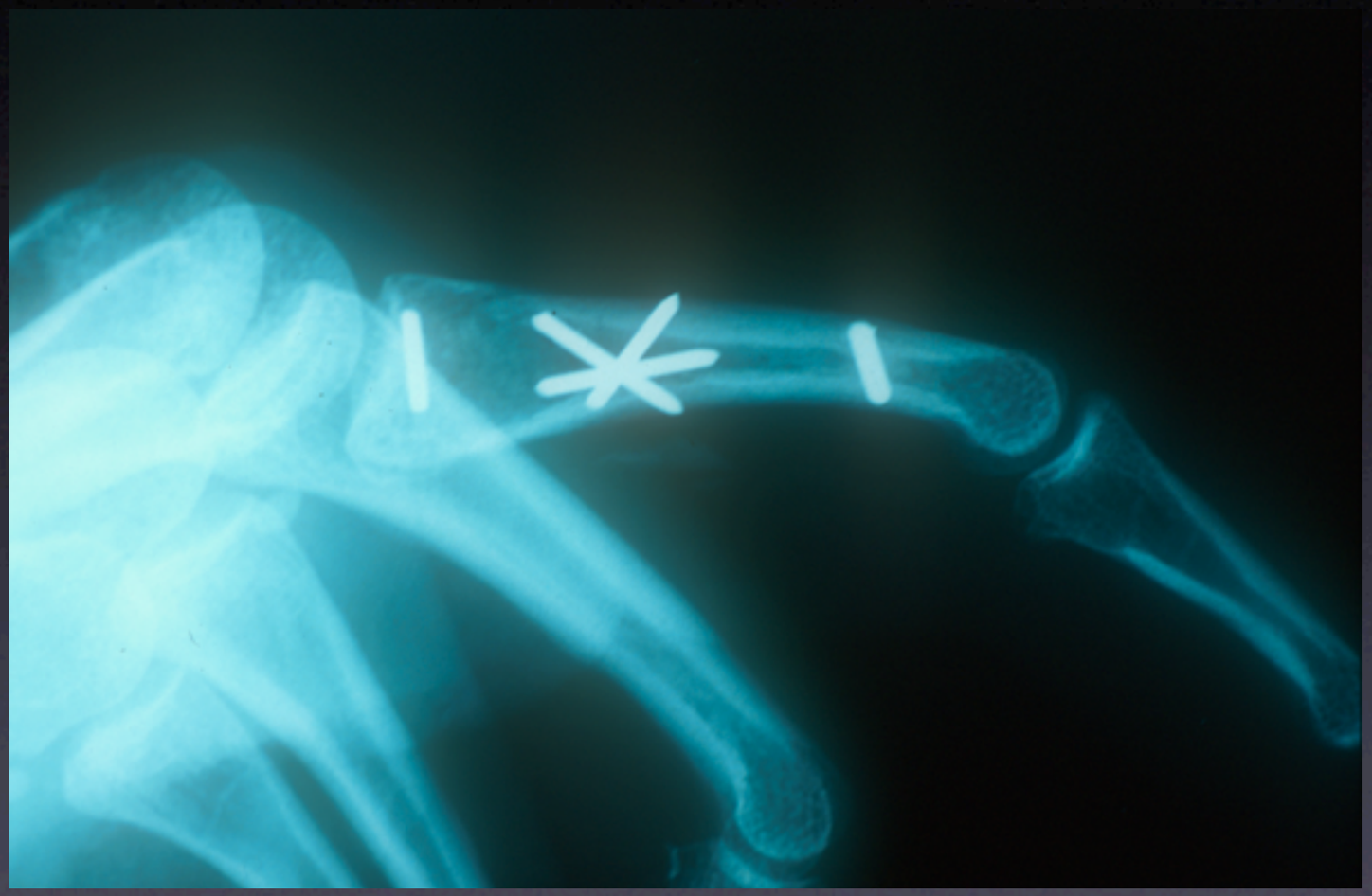

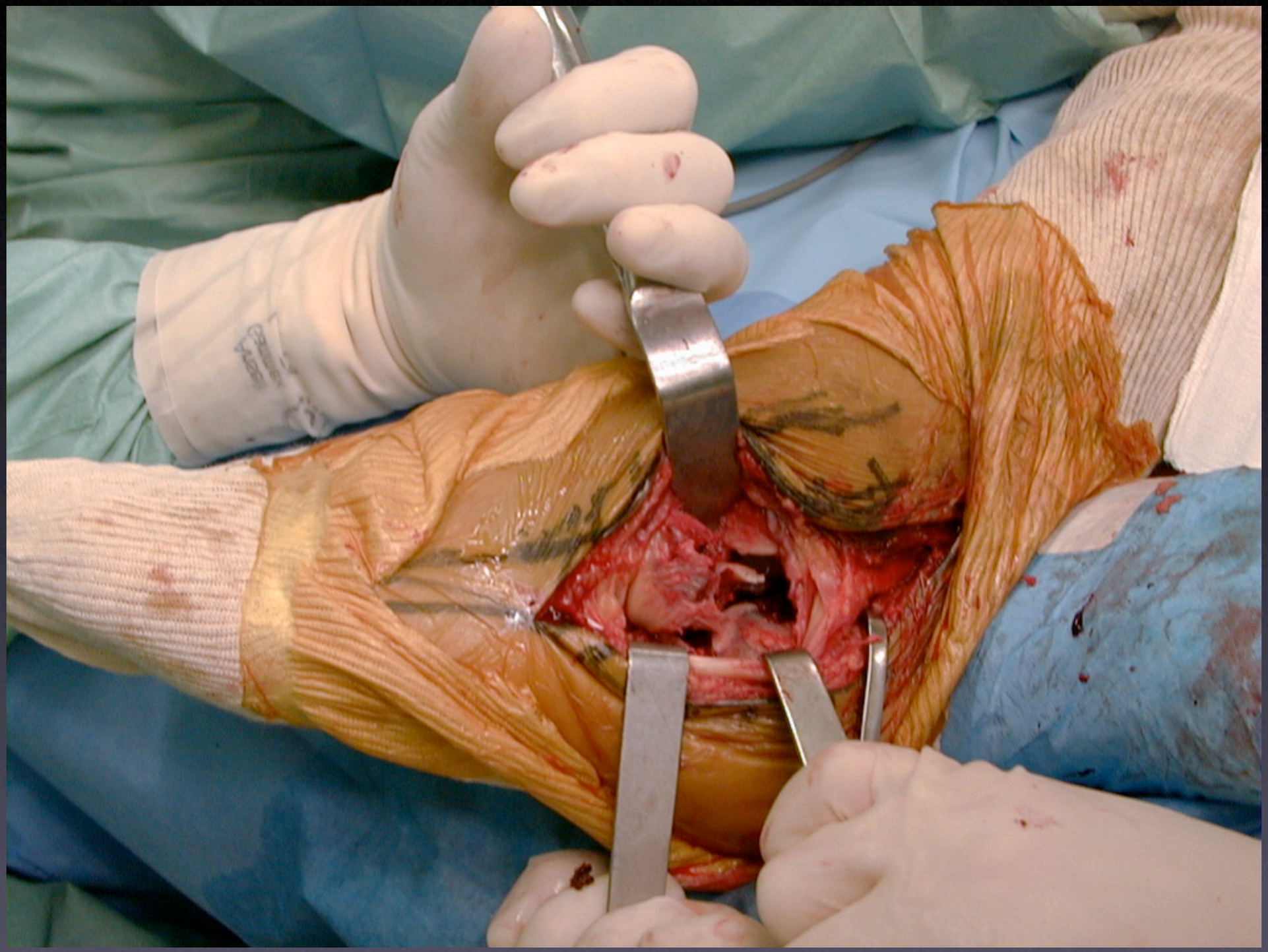

Vis utilisées pour les ostéosynthèses. Le filet est différent pour l’os cortical et pour l’os spongieux

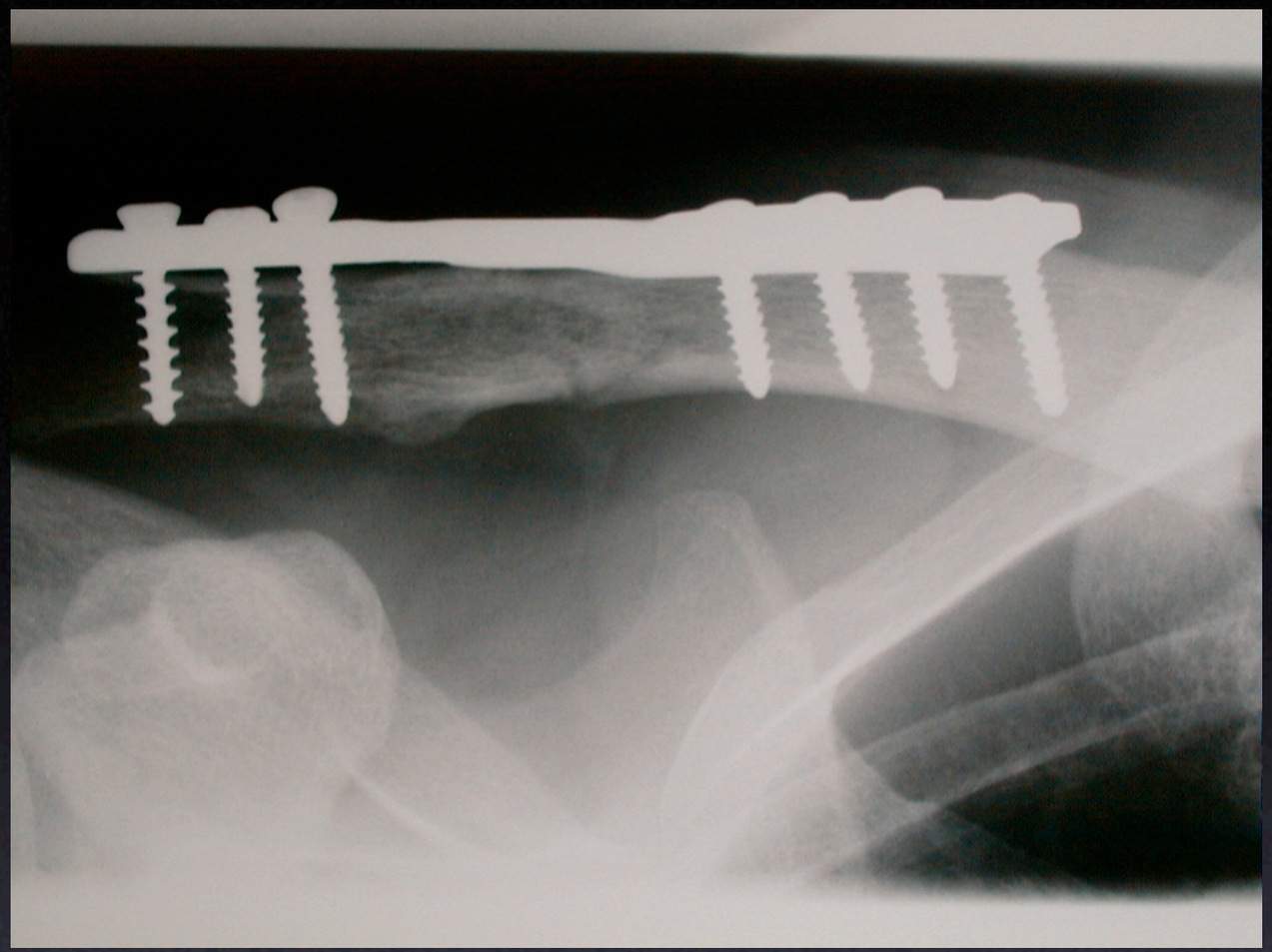

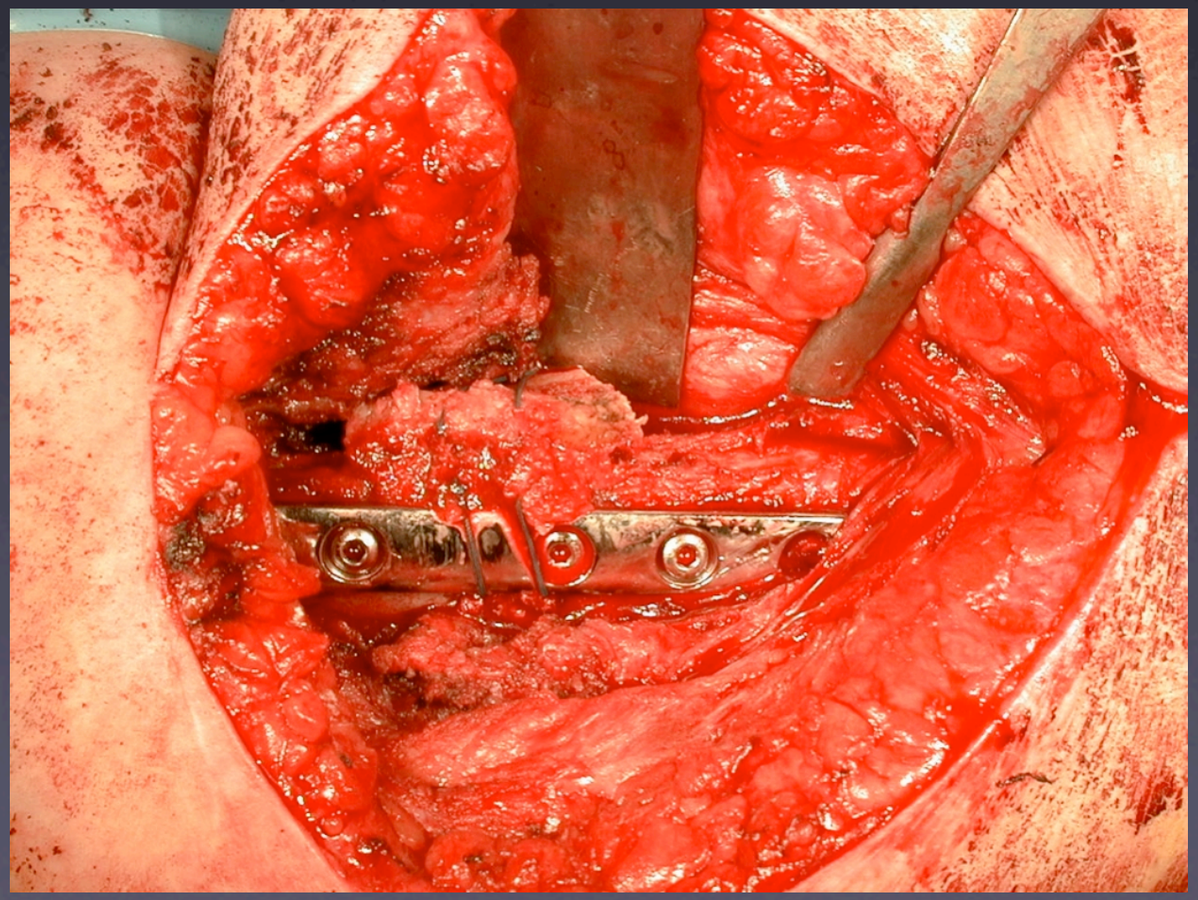

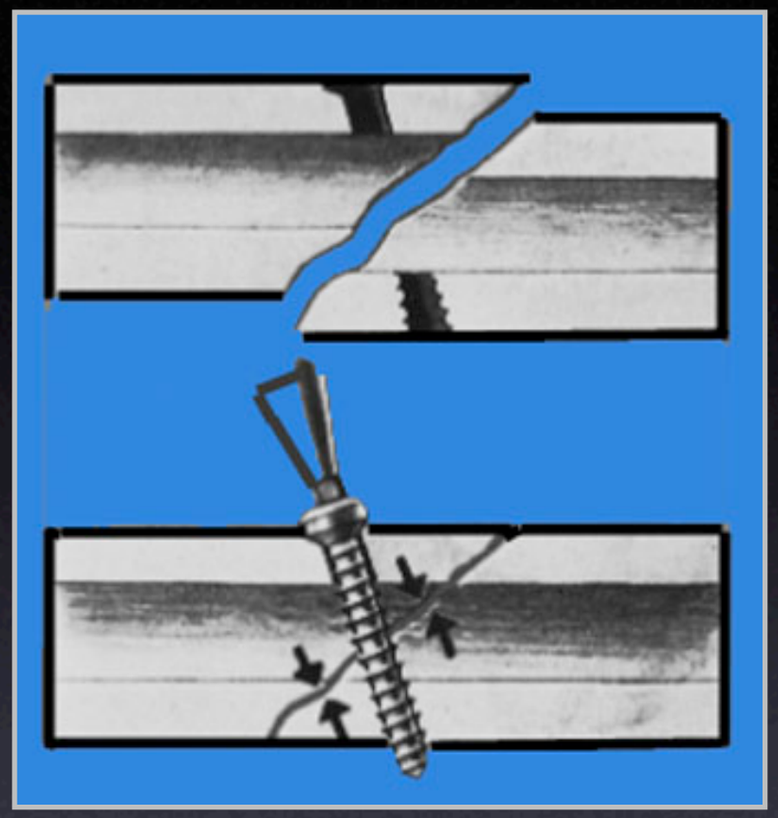



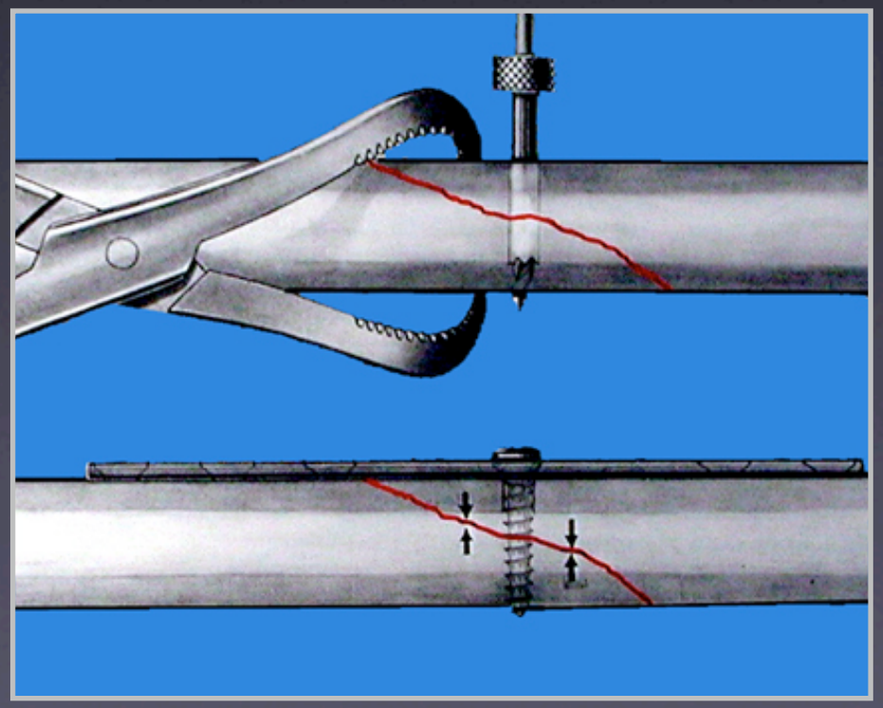

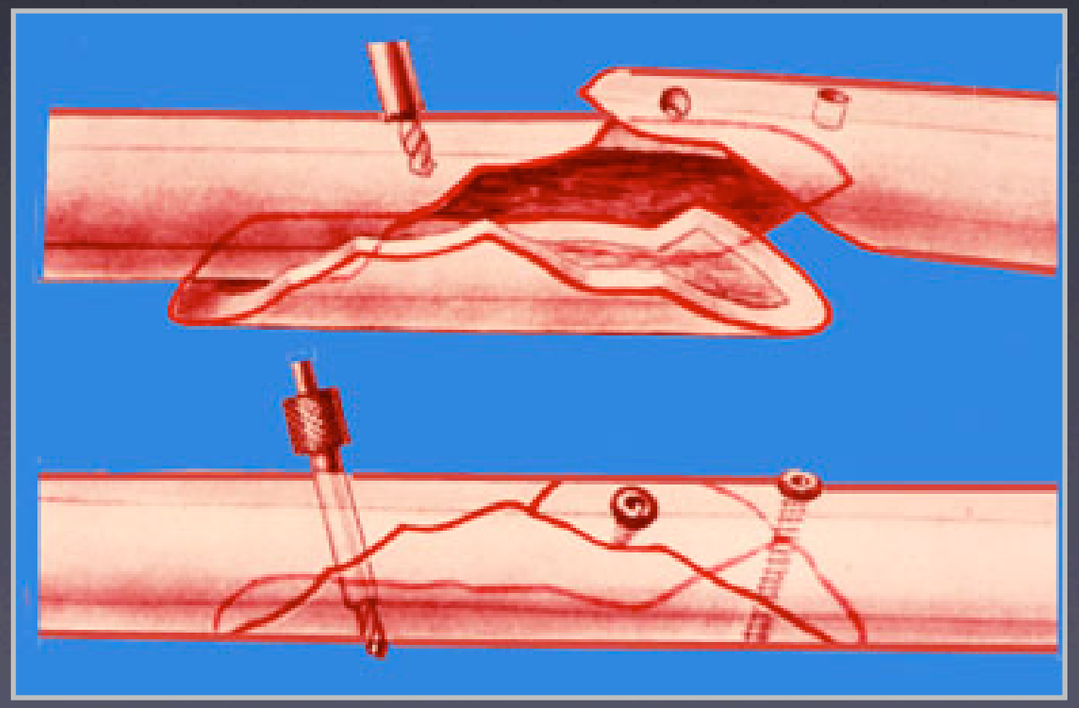







Plaques chantournées pour E inf du tibia

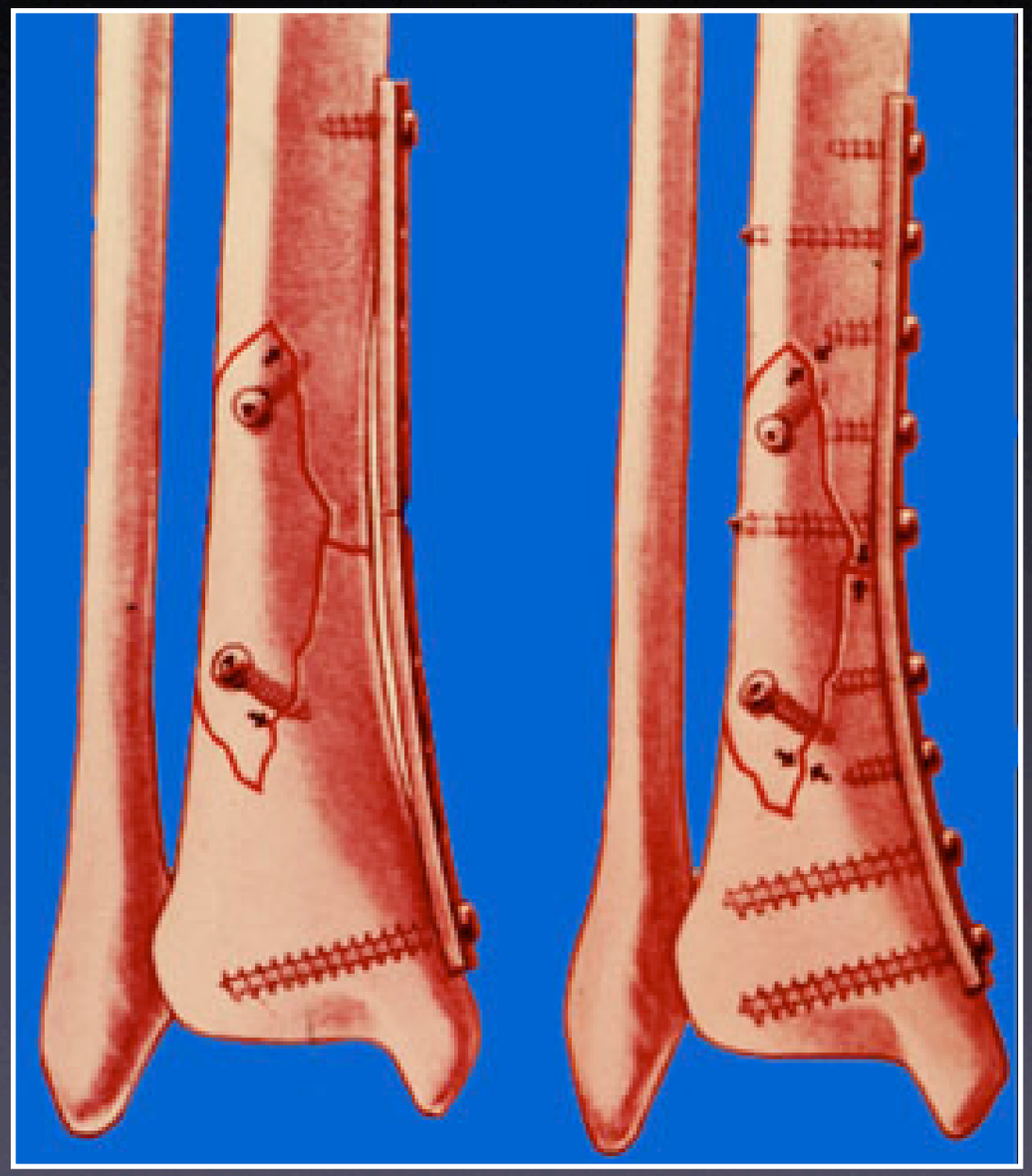

Plaque sur la corticale externe ou interne

Clou tibial

Il y a des clous pour

- Le fémur
- Le tibia
- L’humérus

- Le plus souvent possible on réalise l’enclouage sans ouvrir le foyer de fracture :

Lorsque les 2 extrémités sont verrouillées, le montage est dit « statique »

Lorsqu'il n'y a q'une vis, le montage est « dynamique » l'appui favorise le contact des fragments

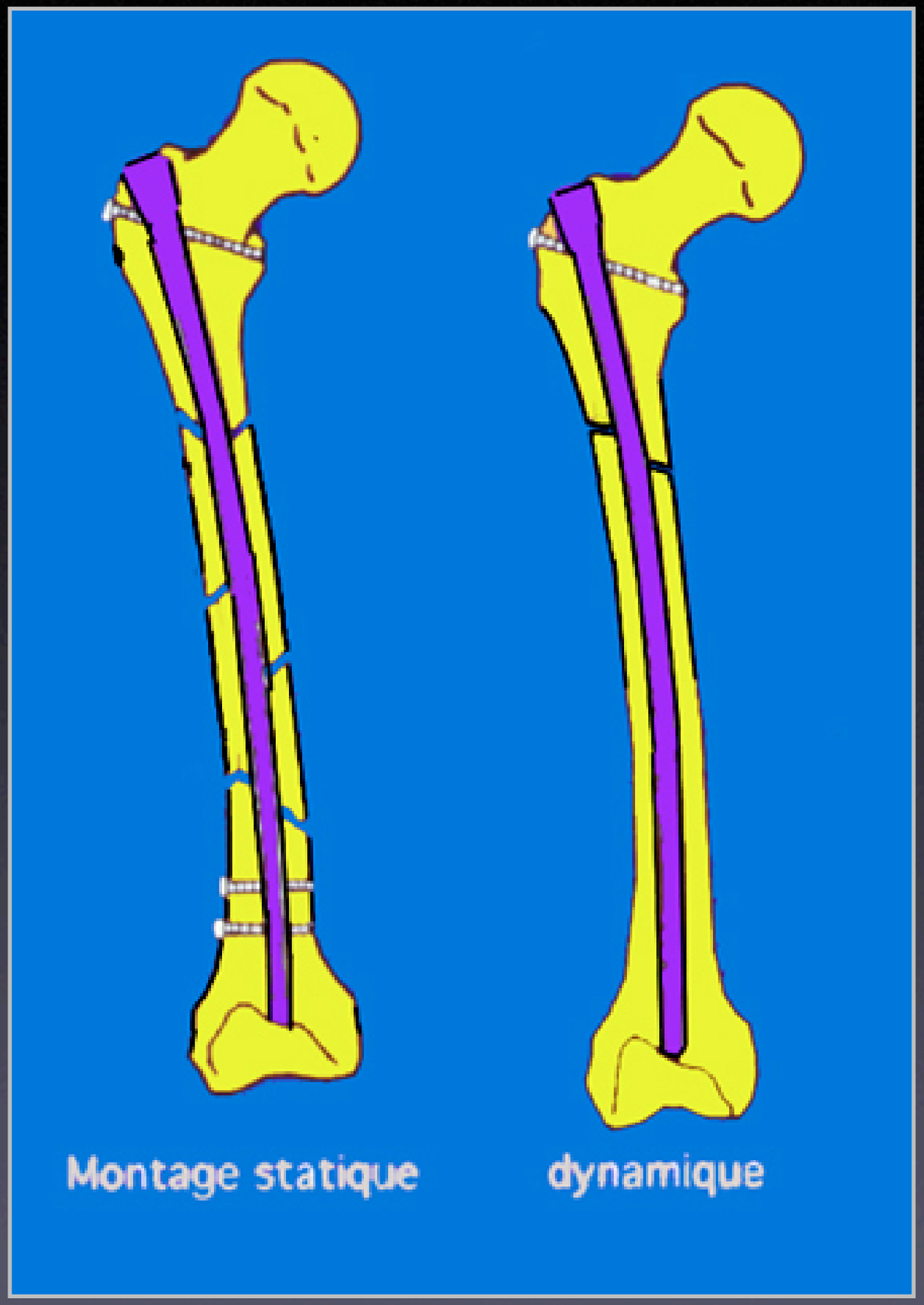

Formation d’un gros cal grâce à l’hématome périfracturaire préservé

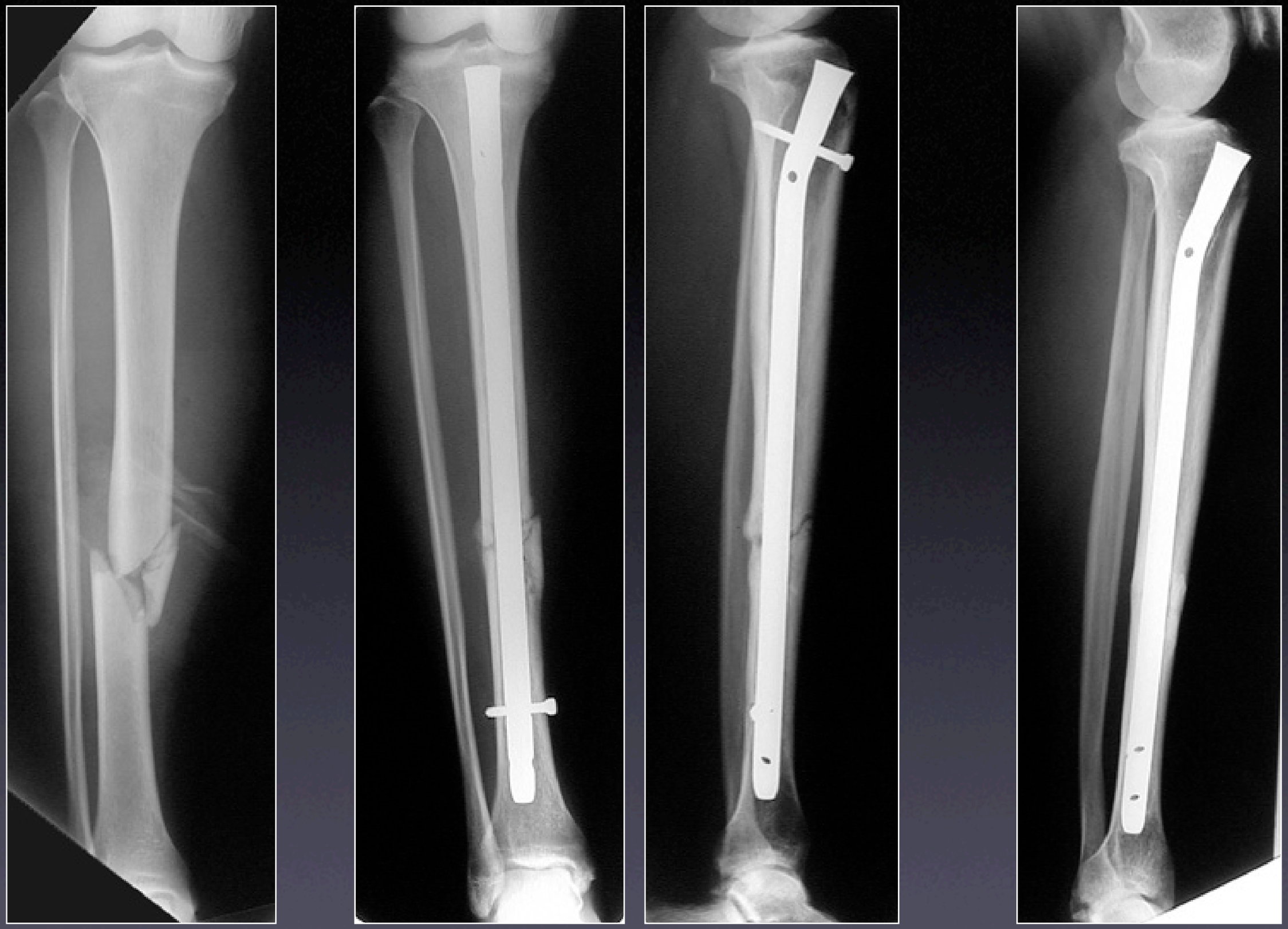

Clou à foyer fermé verrouillé Vis enlevées à 3 mois

Guérison 6 mois

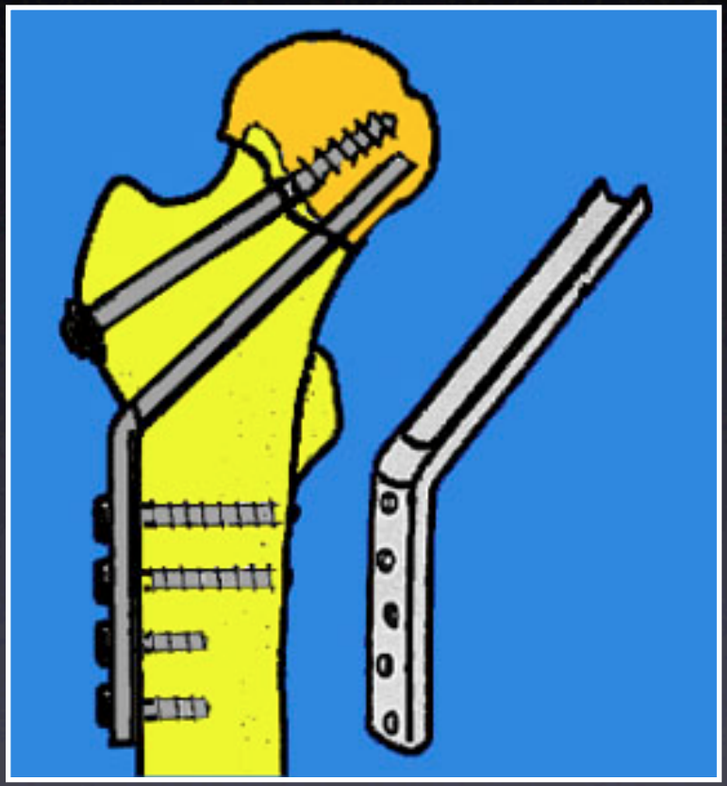

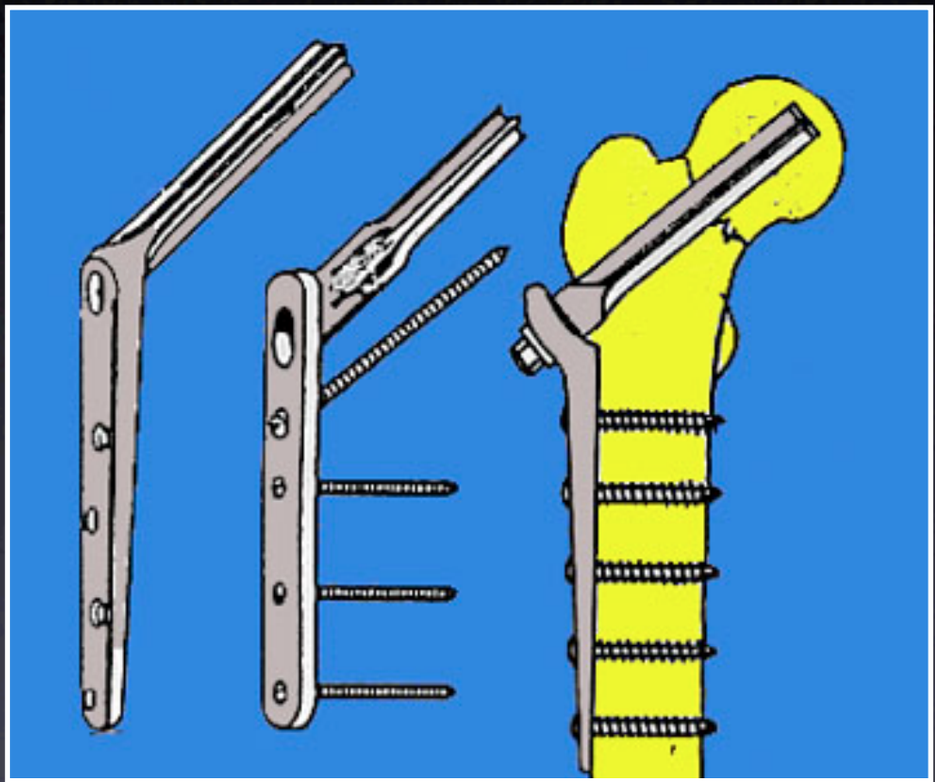

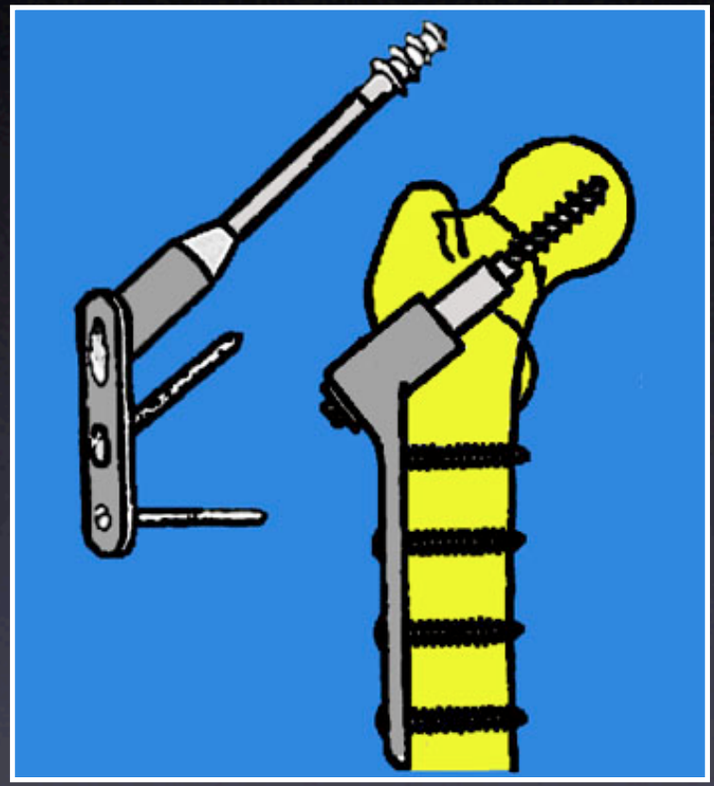

Lame-plaque AO **Clou-plaques** **Vis à compression**

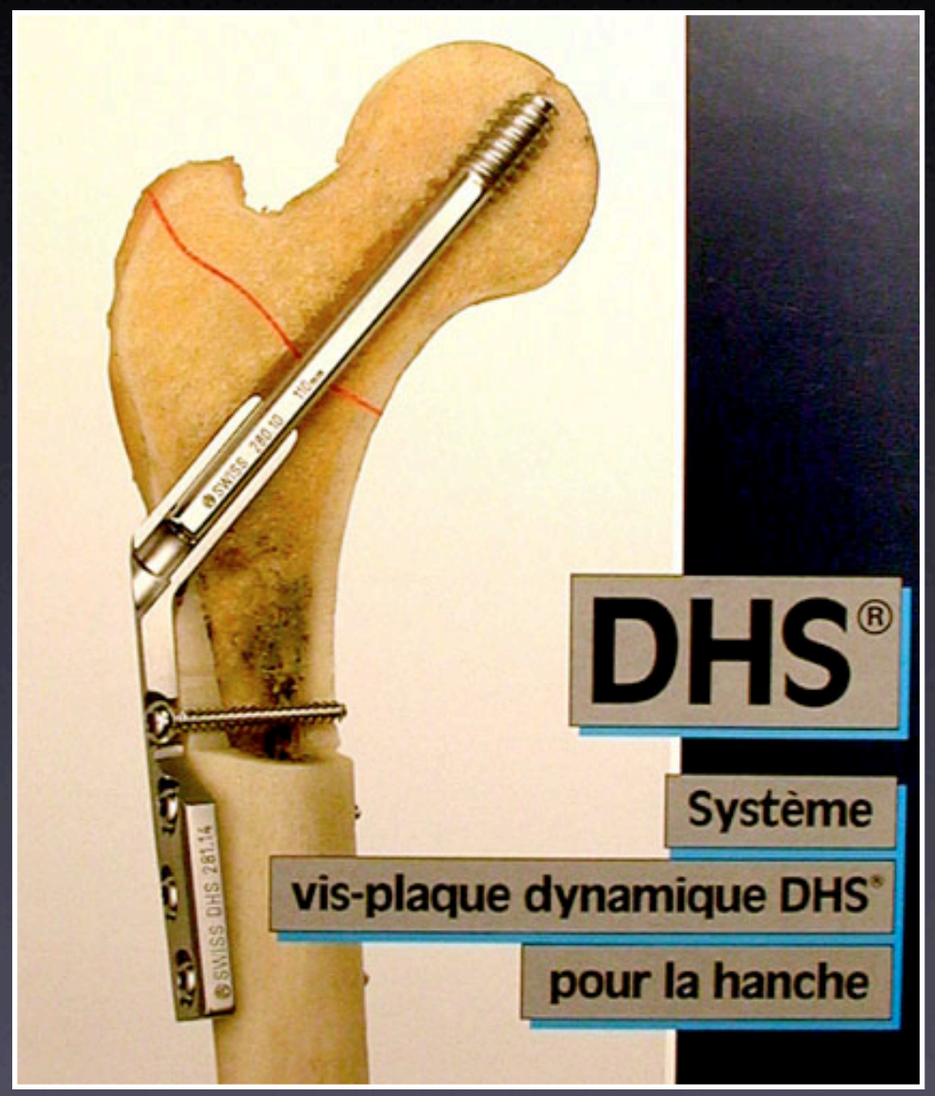
DHS®
Système
vis-plaque dynamique DHS®
pour la hanche

Traitement des fractures trochantériennes

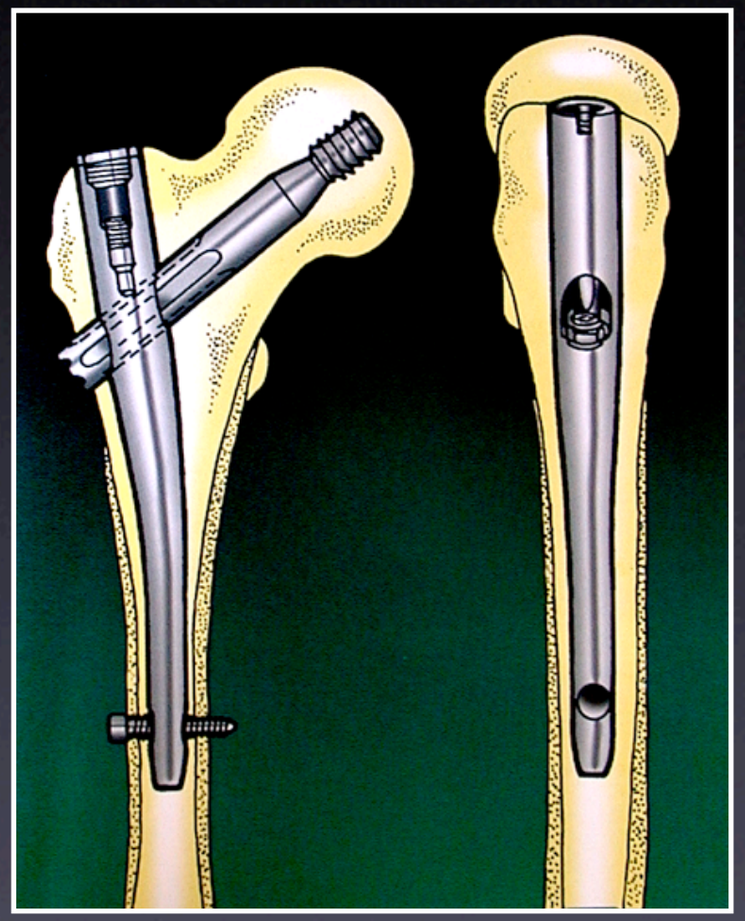

Clou Gamma

DROIT

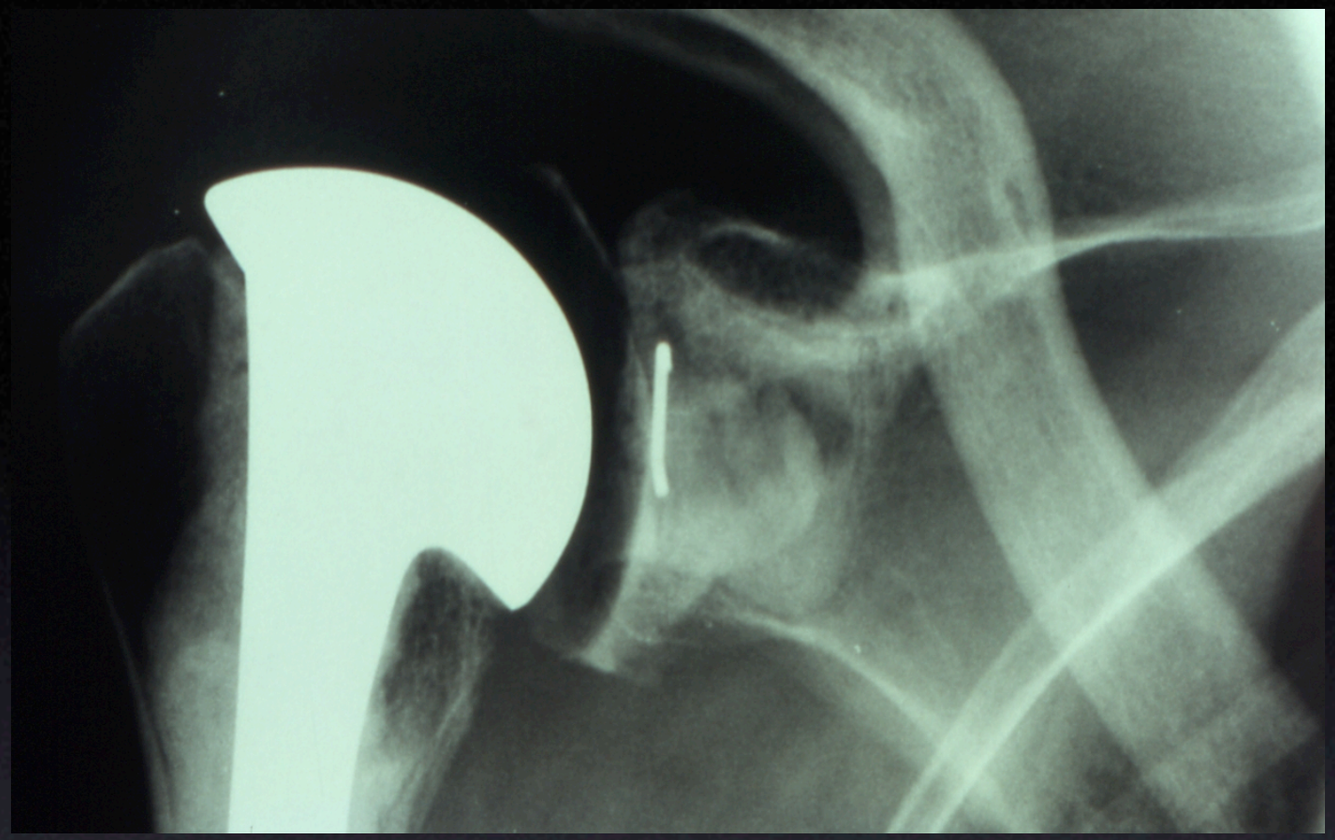

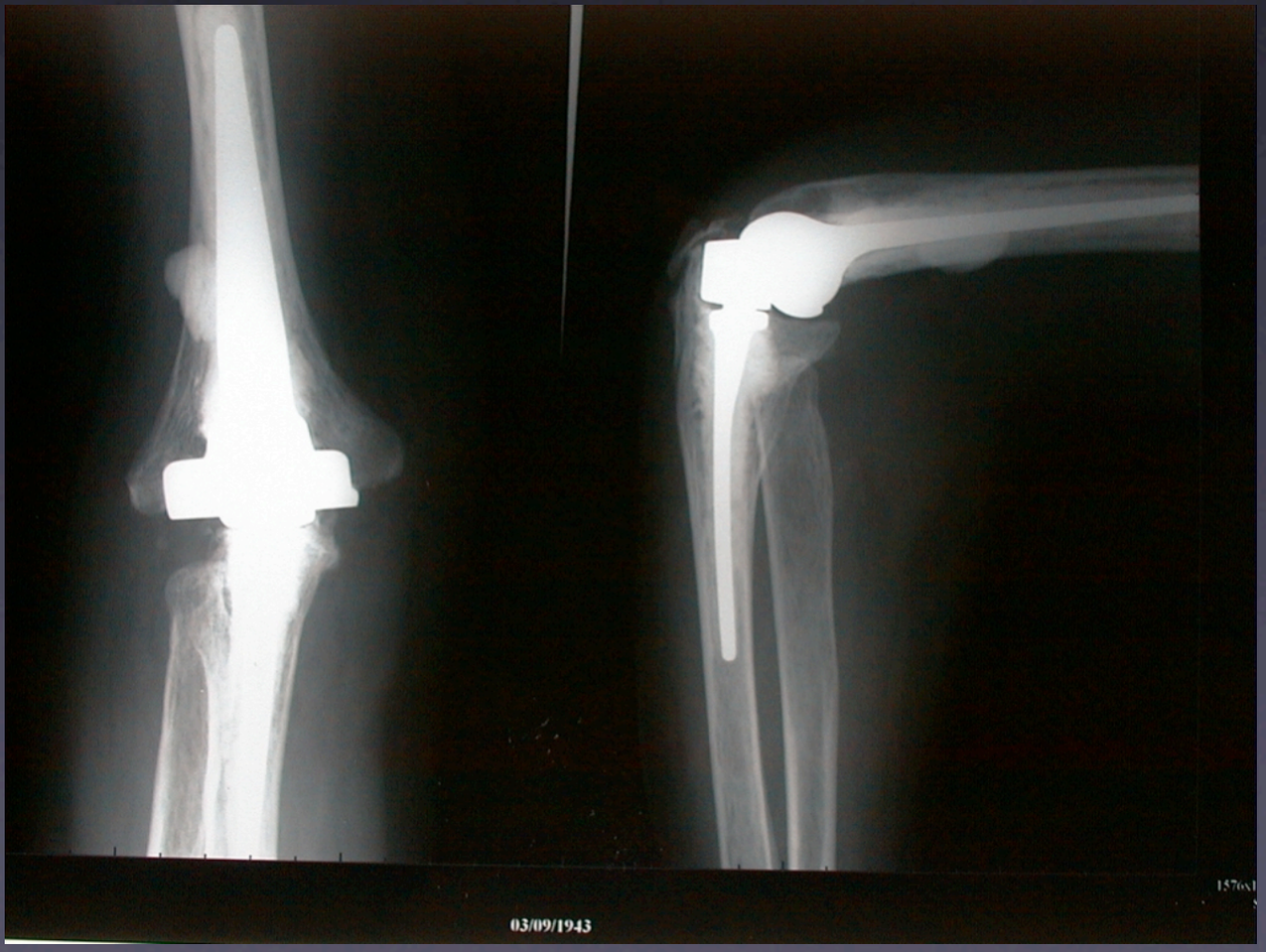
03/09/1943

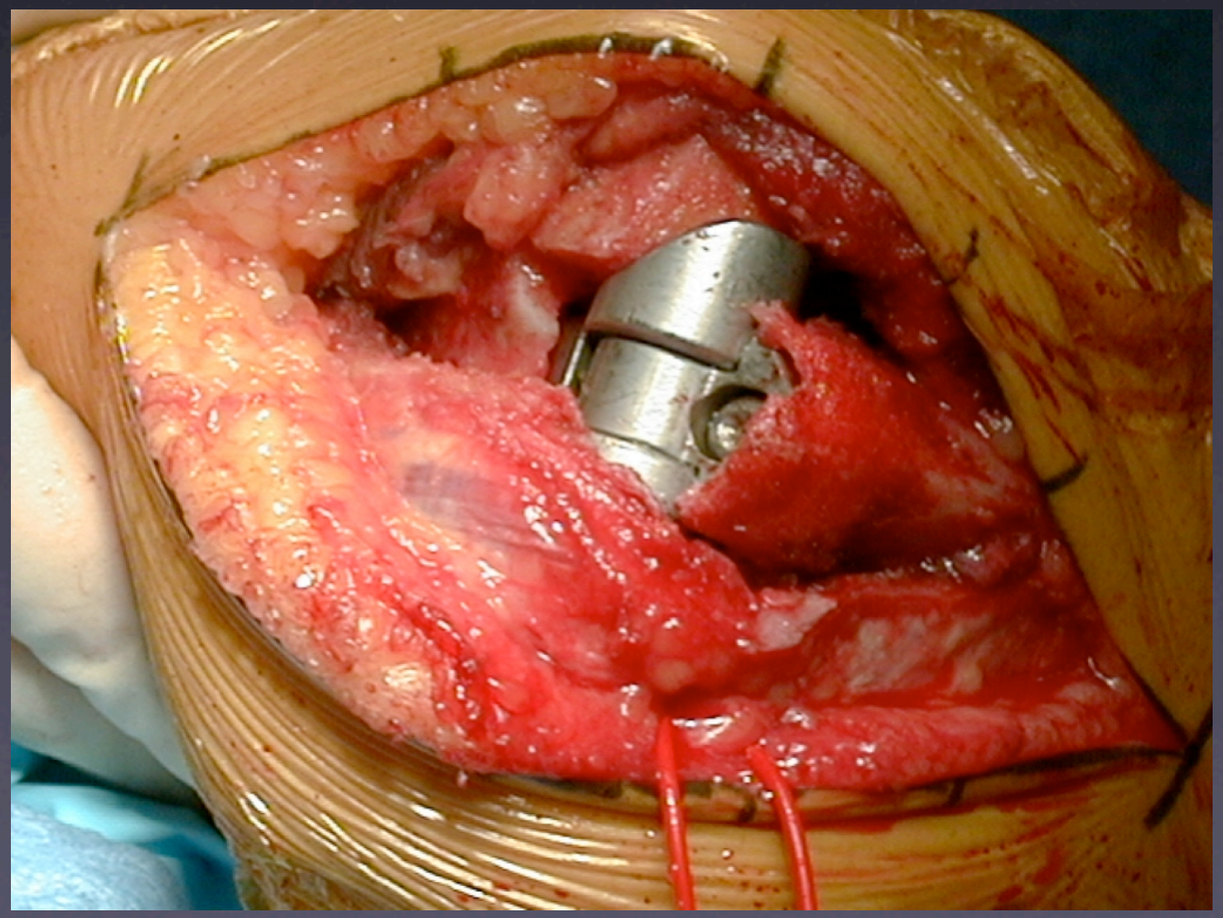

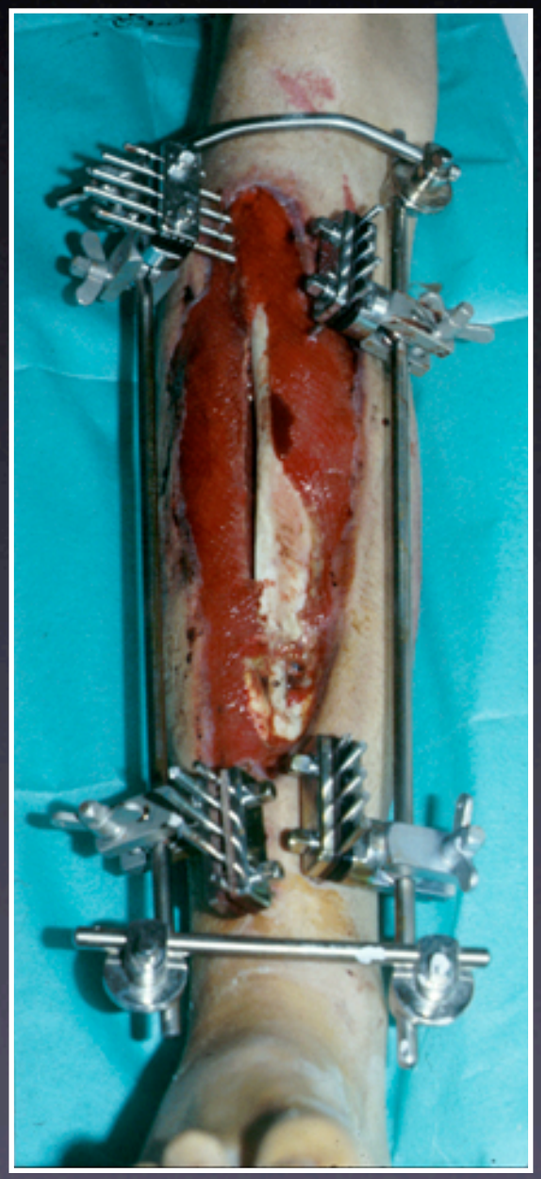

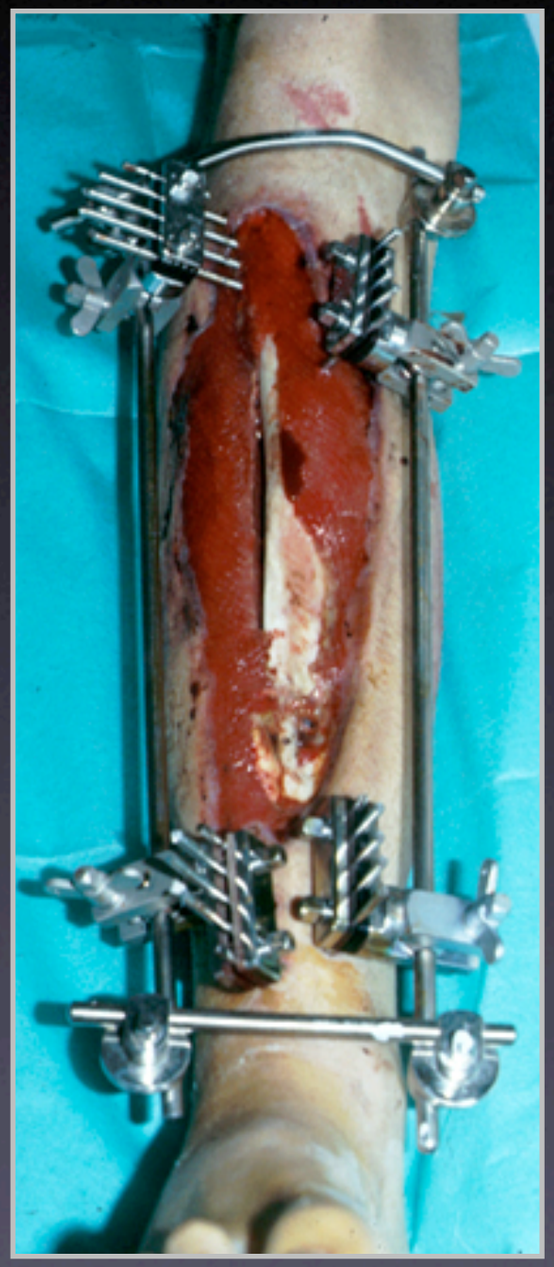





Hofmann Ilizarov **Fixateur sans broches**

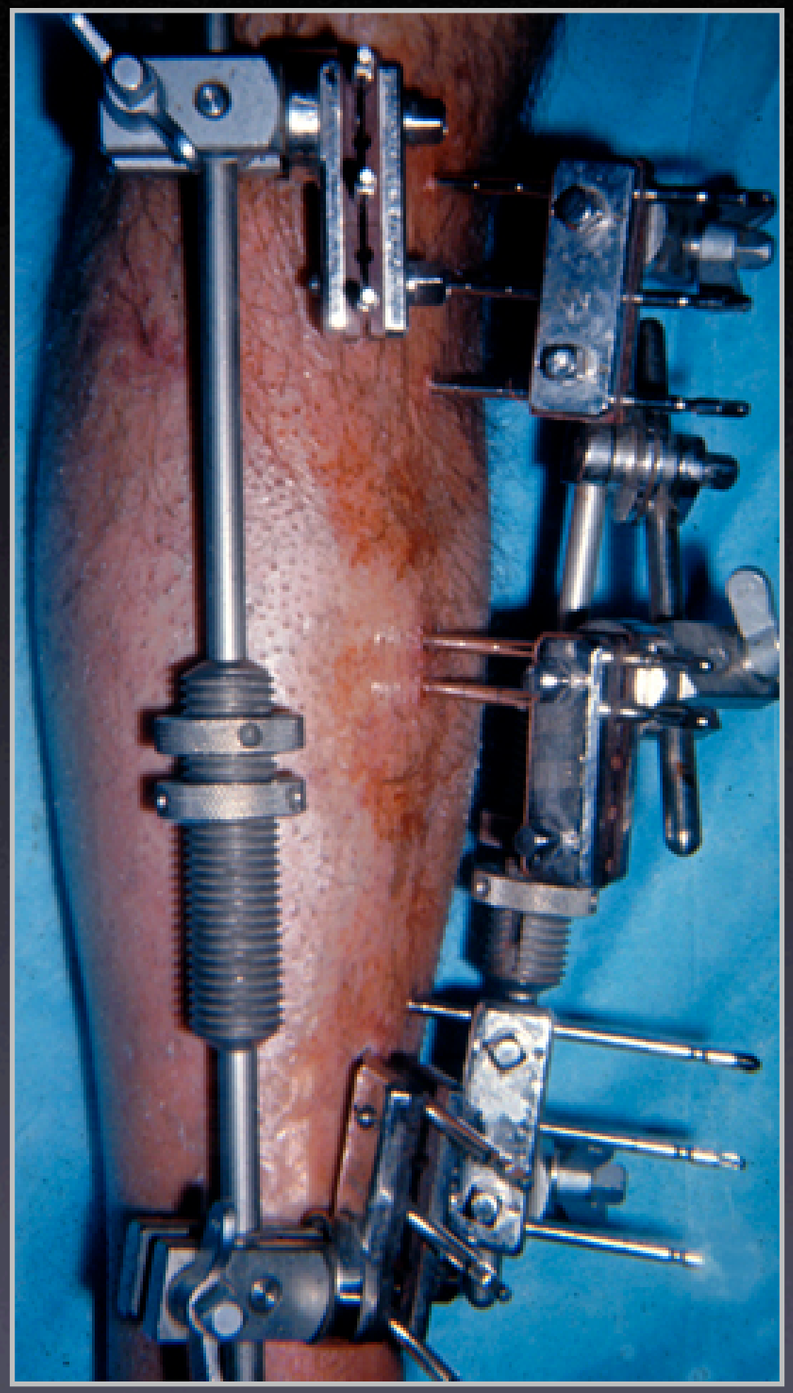

Traitement d'une fracture à double étage par fixateur externe avec montage sur le fragment intermédiaire

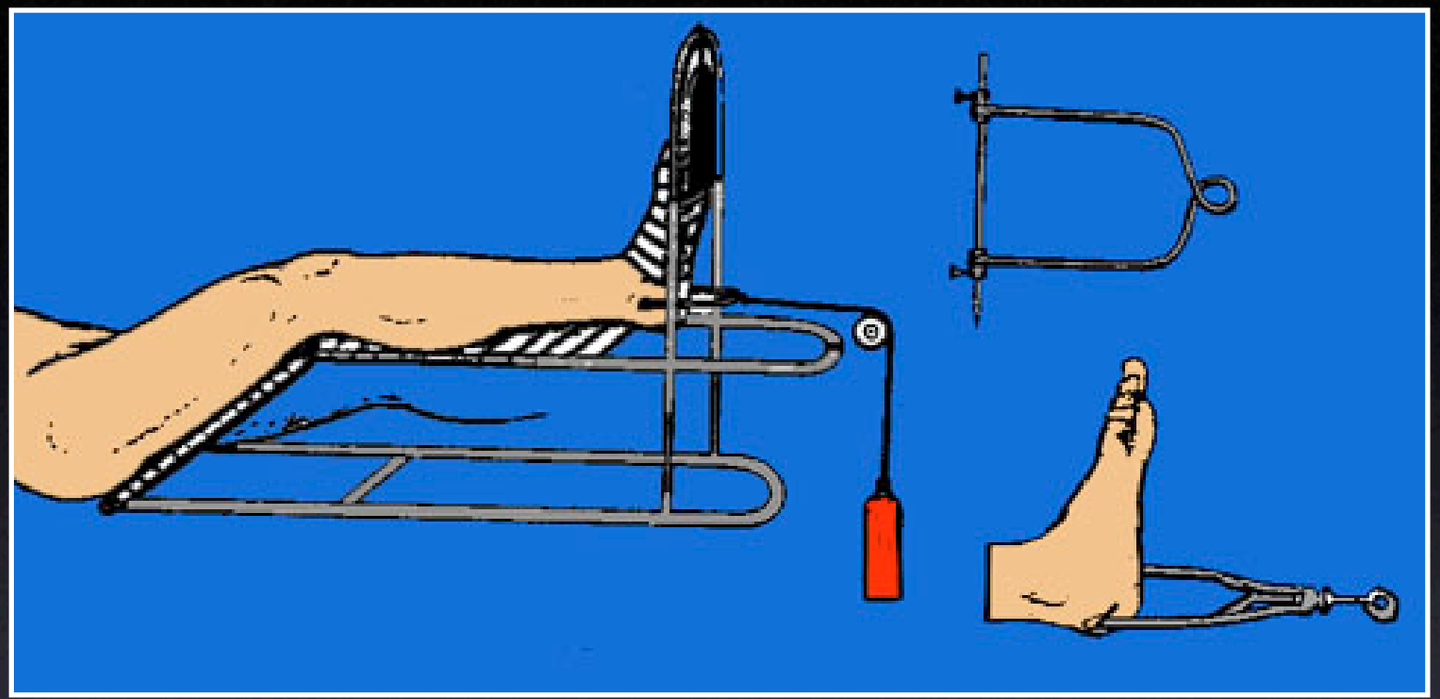

<u>Traction au lit sur attelle</u>

Traitement d'attente (contre-indication temporaire à l'opération)

Rarement traitement complet

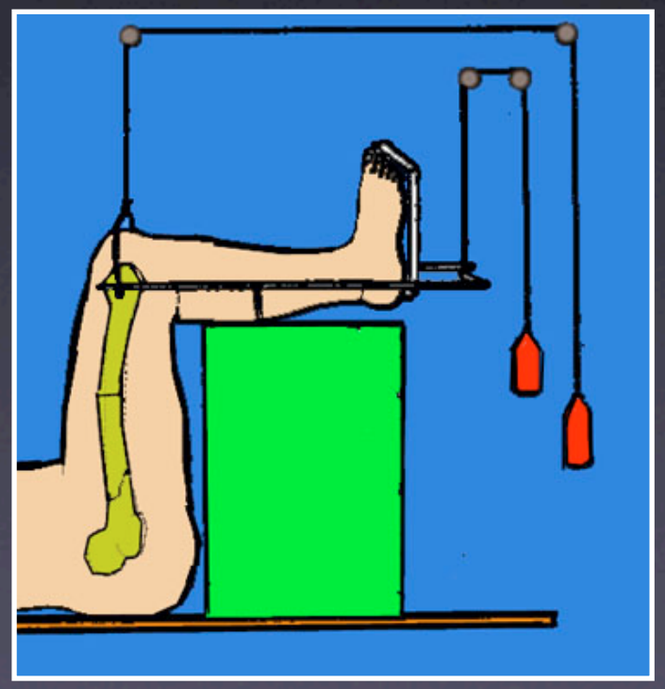

Traction verticale (au zénith) pour fracture de la diaphyse du fémur

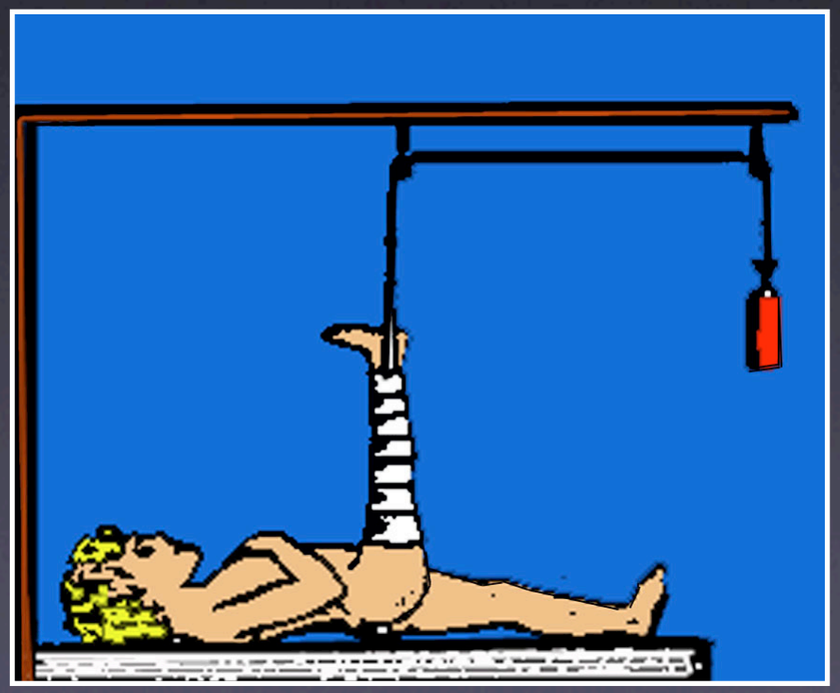

Traction collée (chez le jeune enfant)

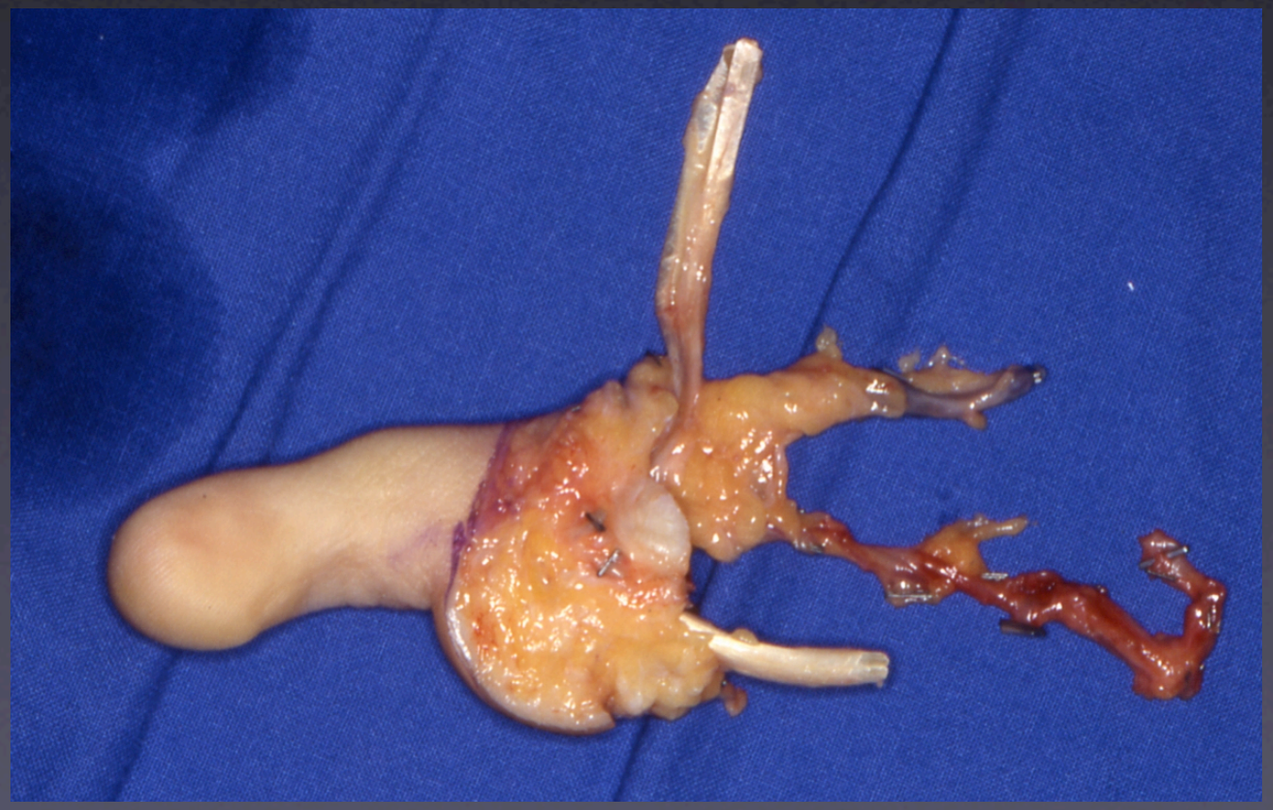

16 6'02

L'image des orthopédistes

- Pas très bonne
- "Les orthopédistes sont-ils des gorilles ?"
- "Science" et une technique (*techné*) très clinique