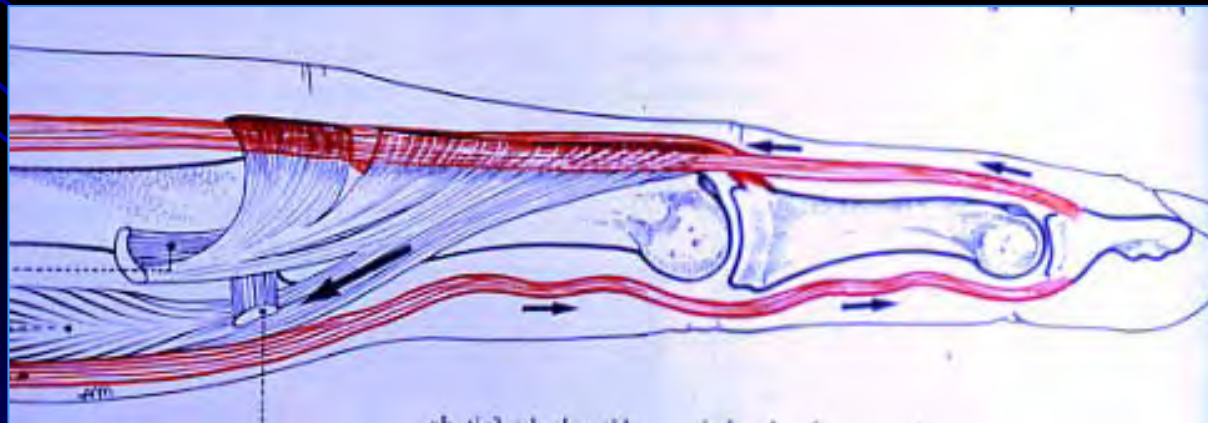
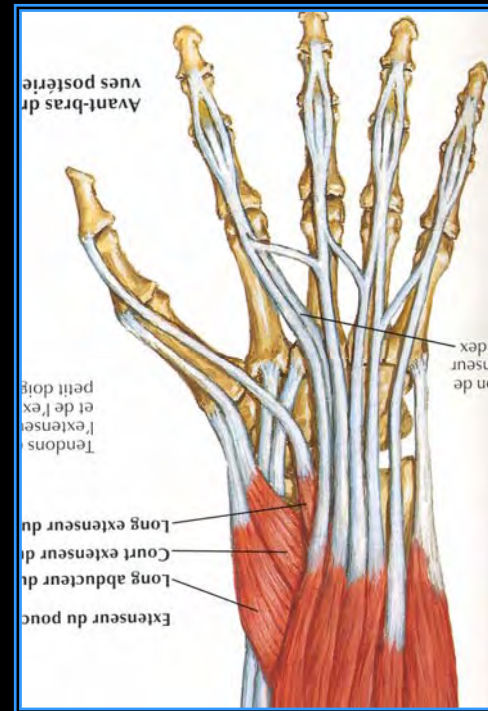
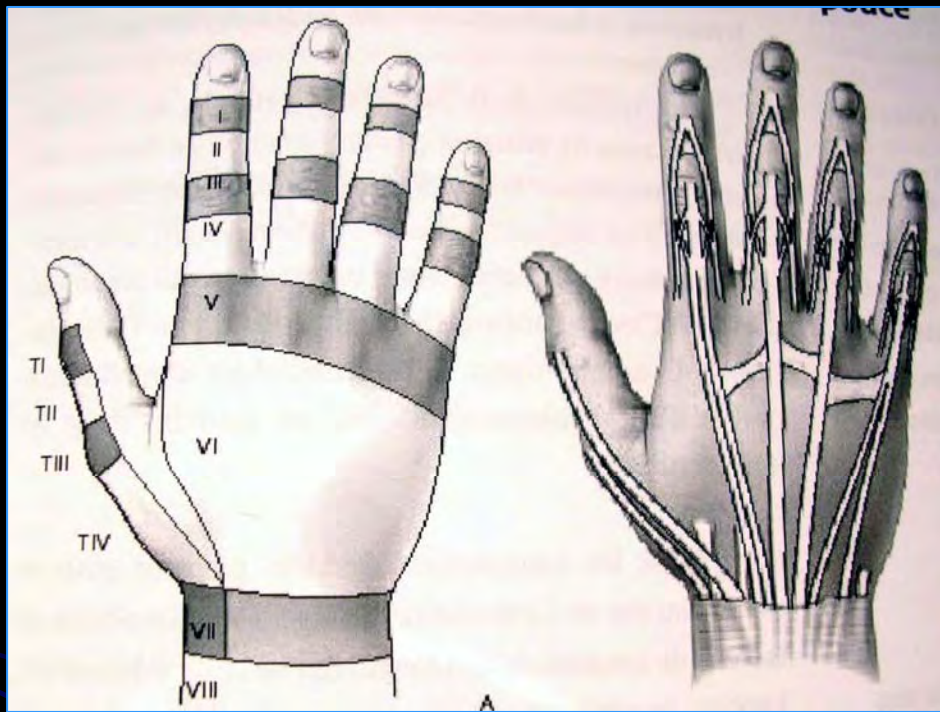


Sections tendineuses des extenseurs

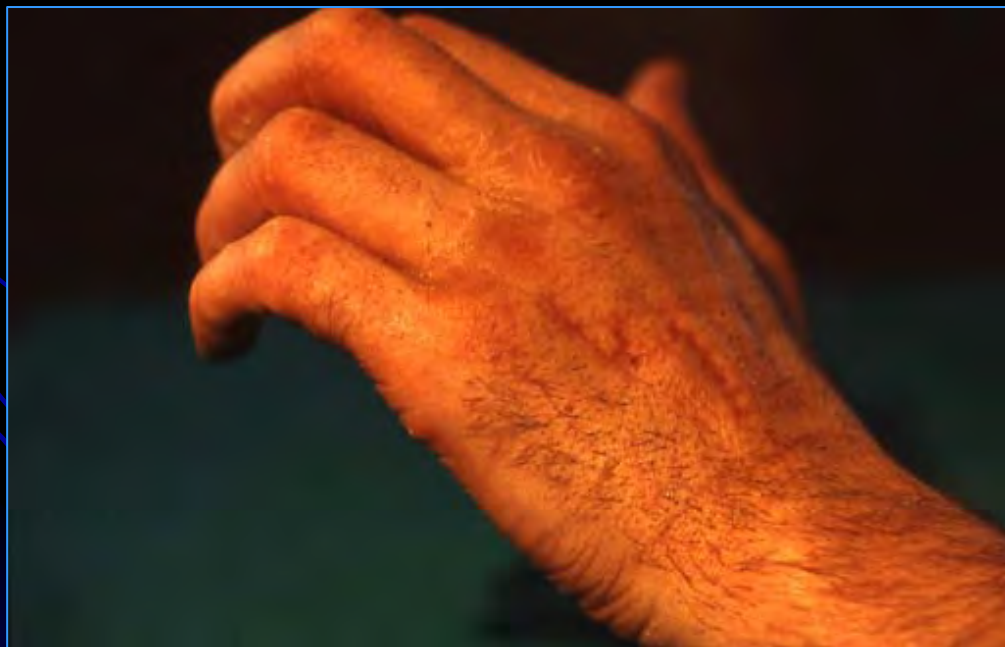
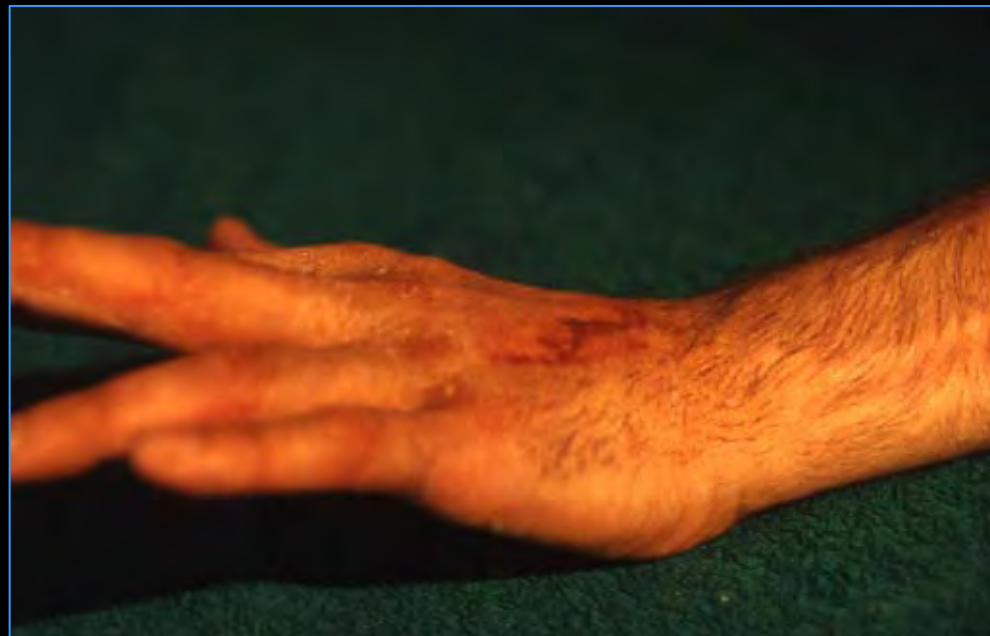
● Niveau de la lesion

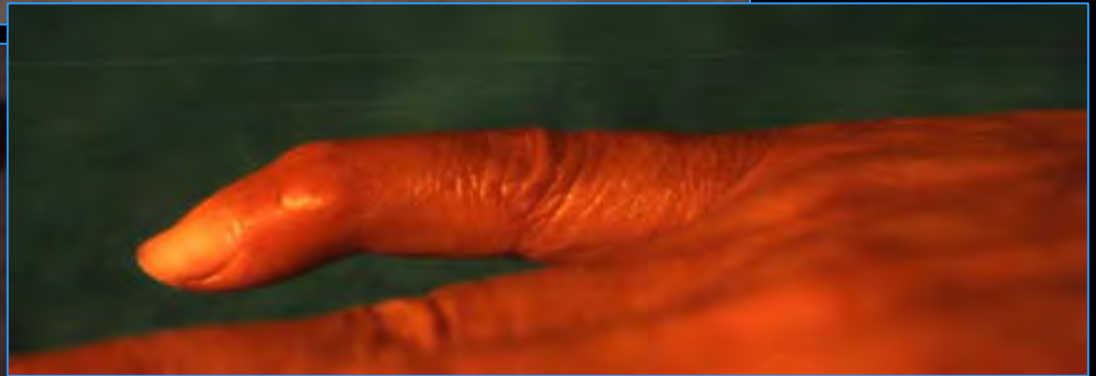
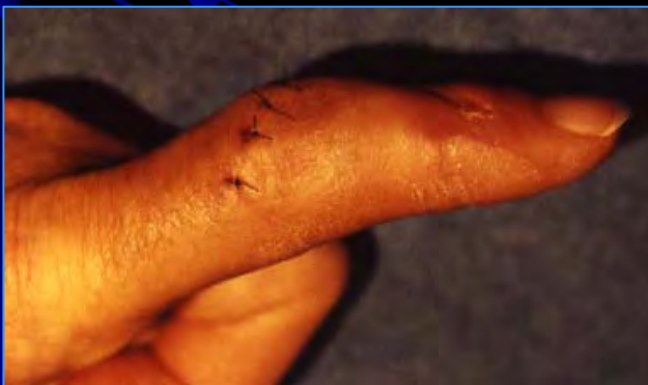
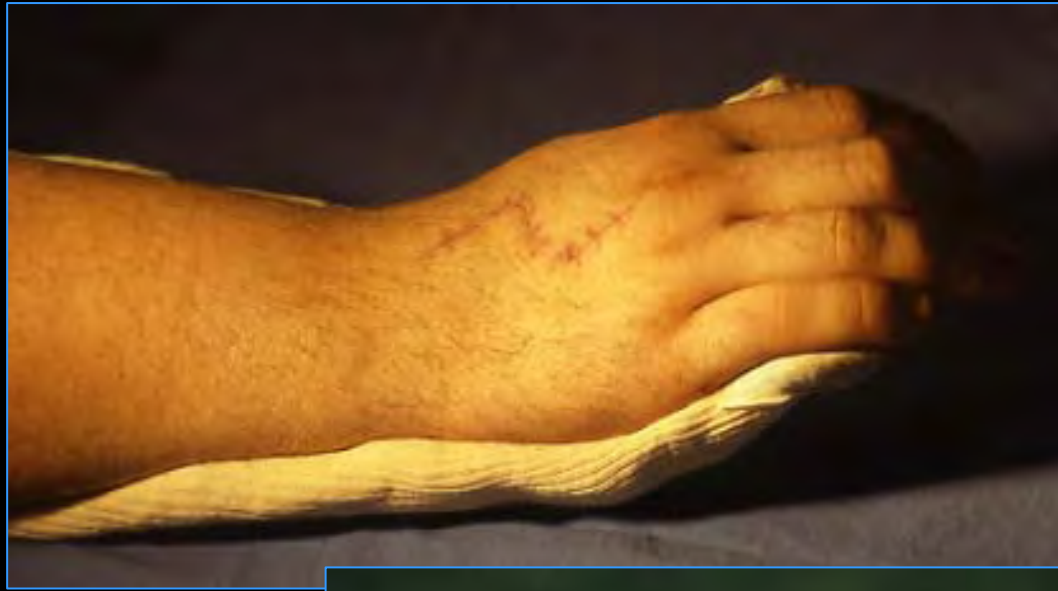Glissements

- proximal actif
- distal passif

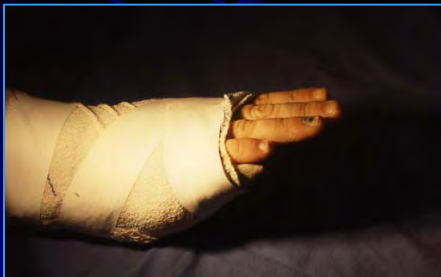
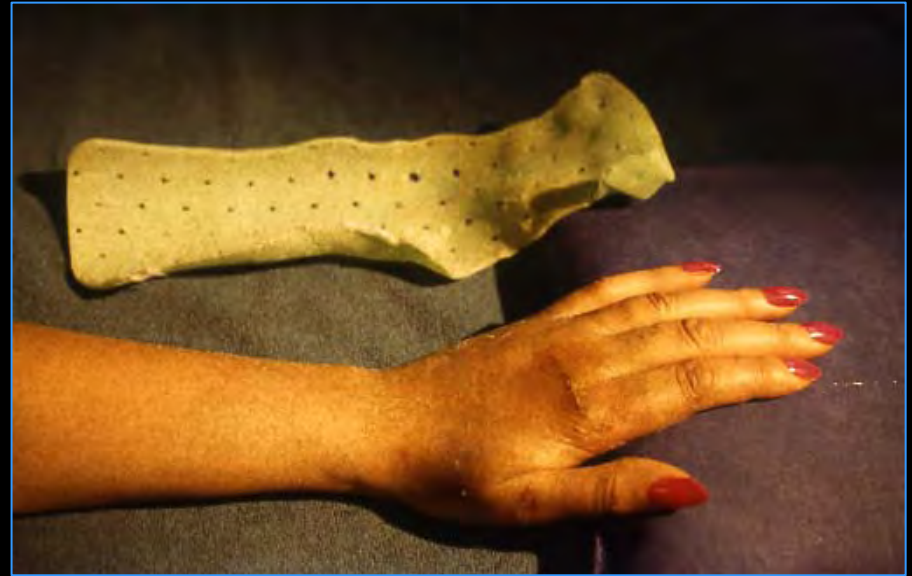
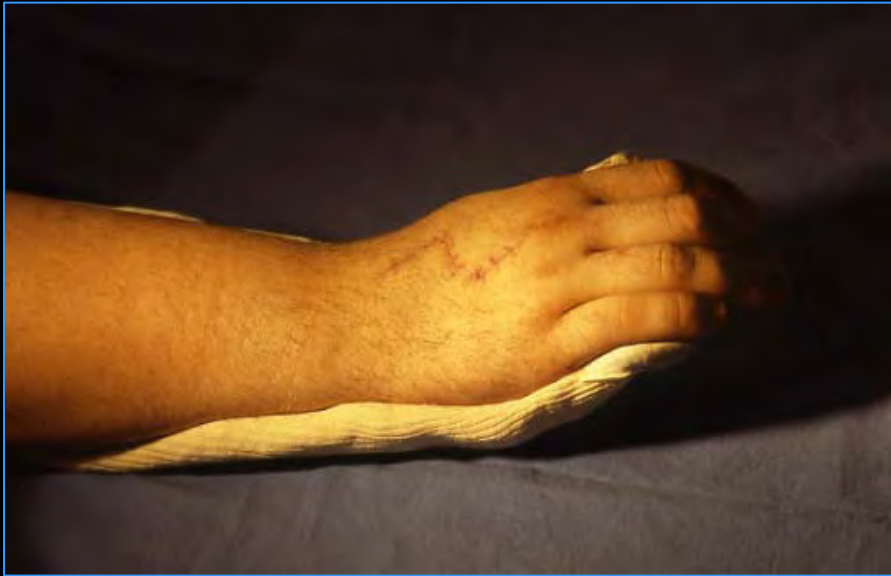3 NIVEAUX

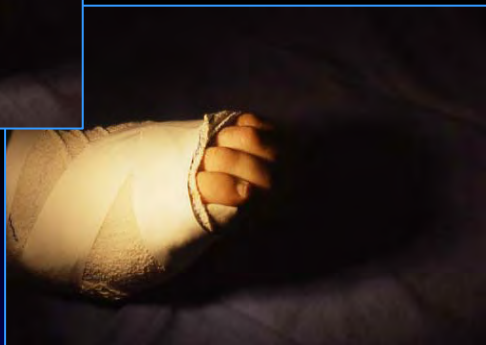

Dos de la main

immobilisation

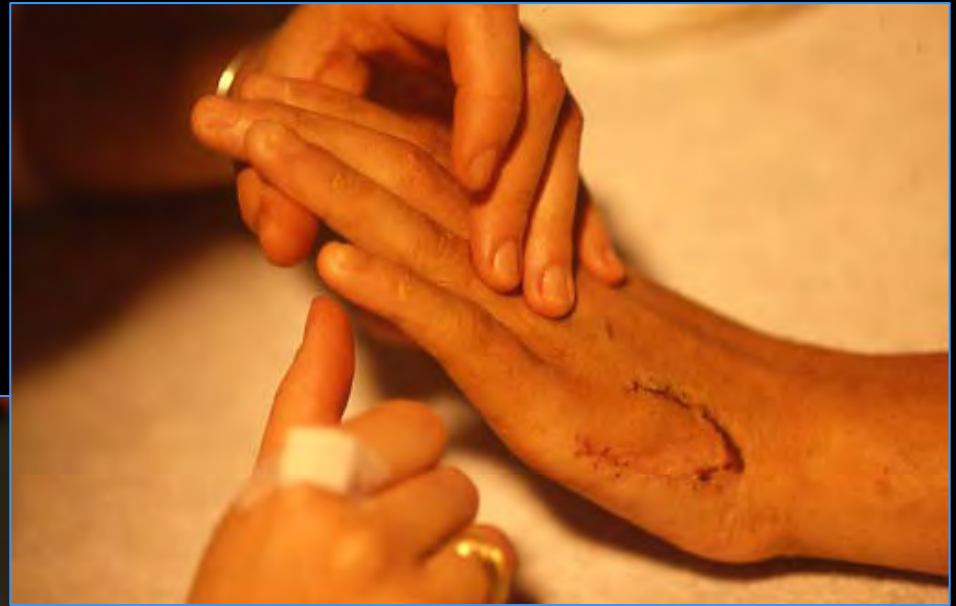

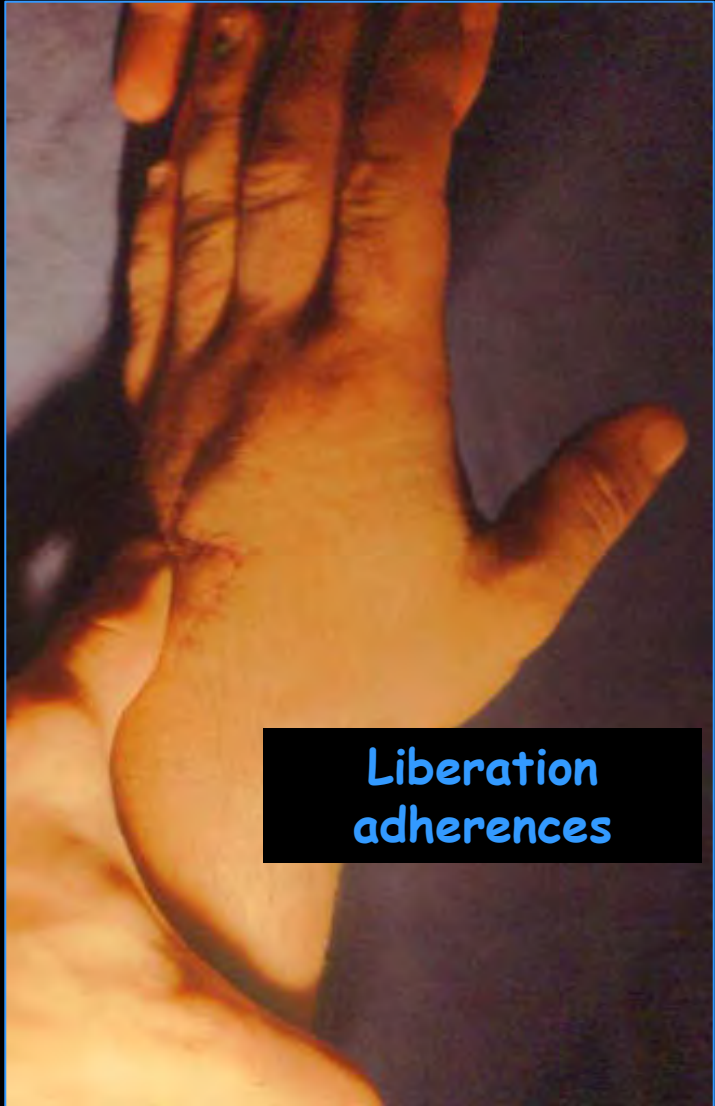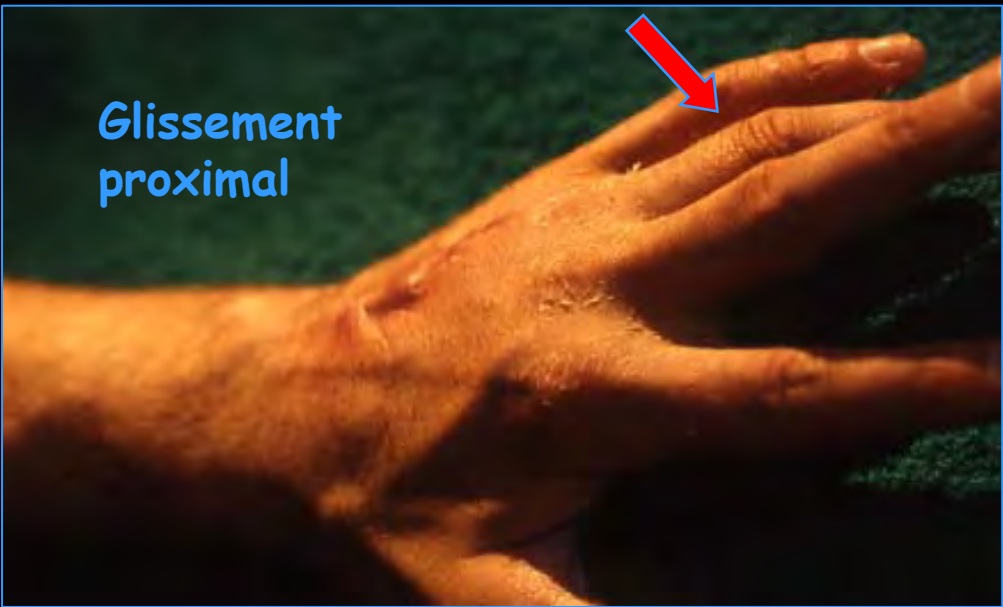Ipp libres



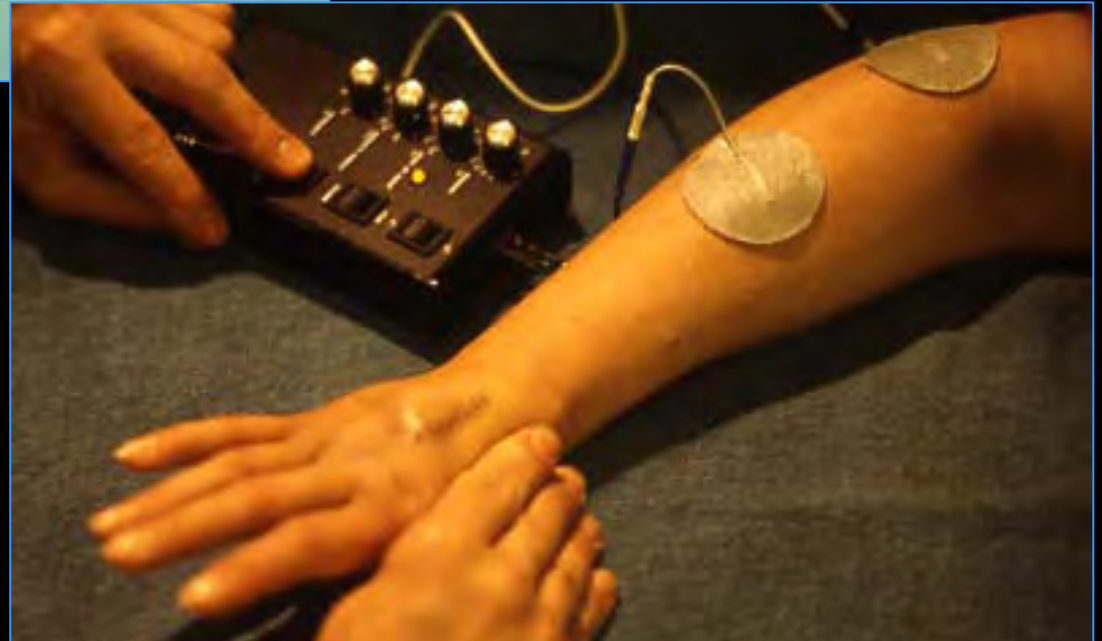
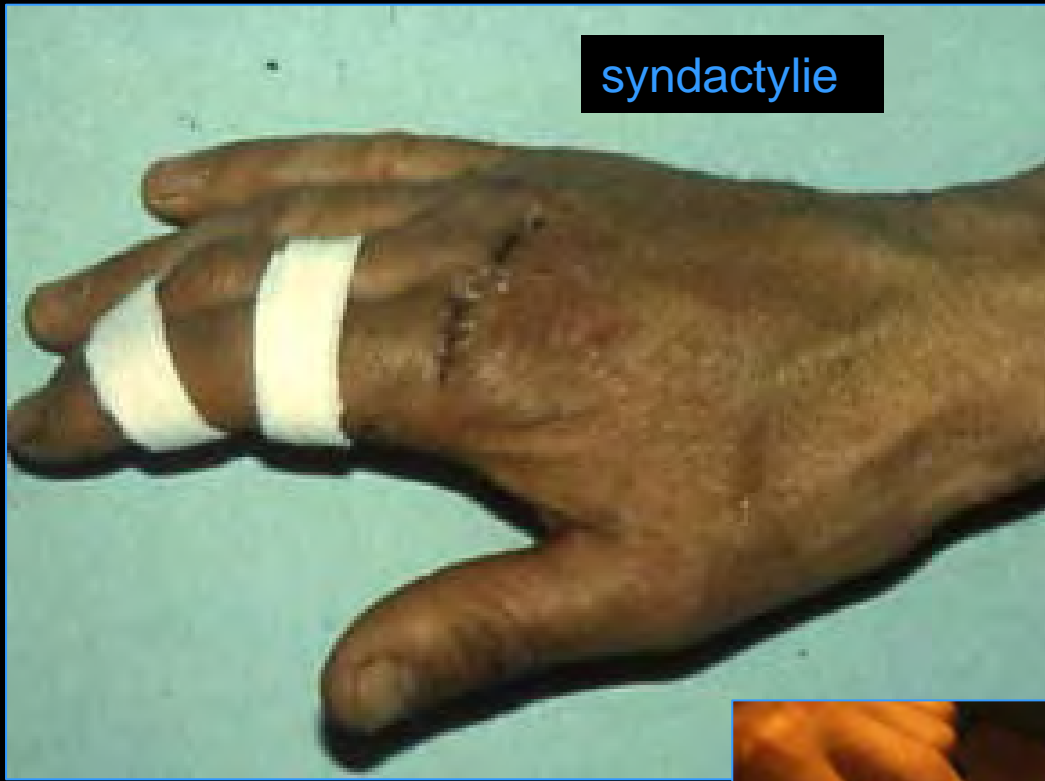KLEINERT « inversé »


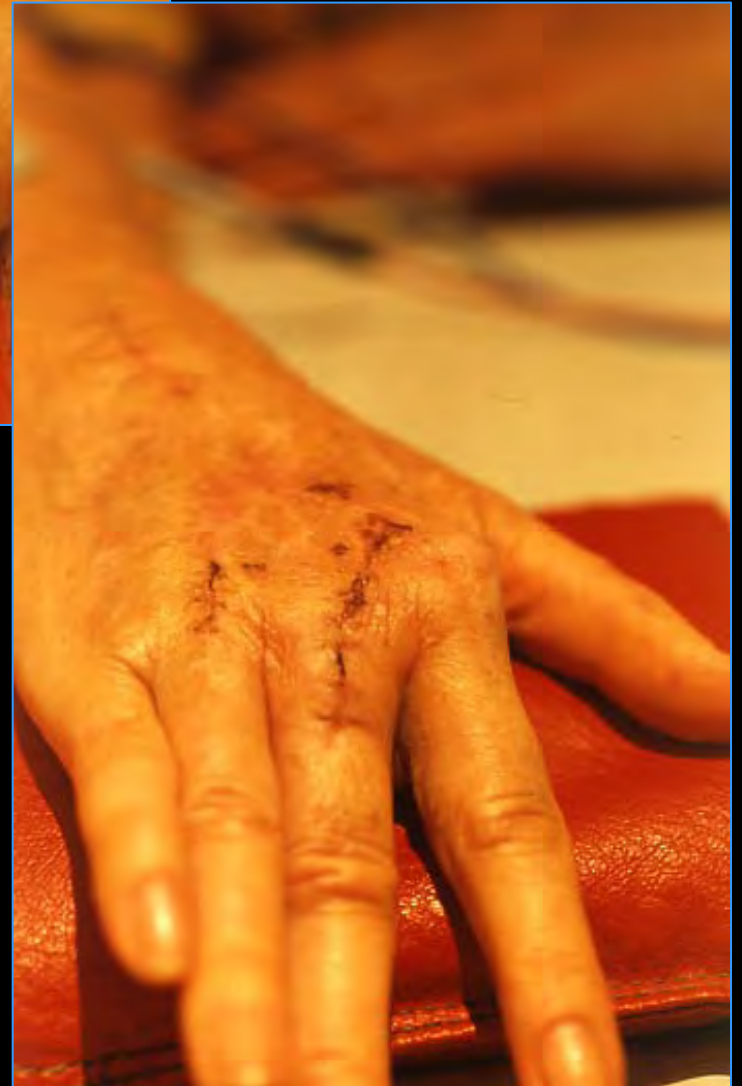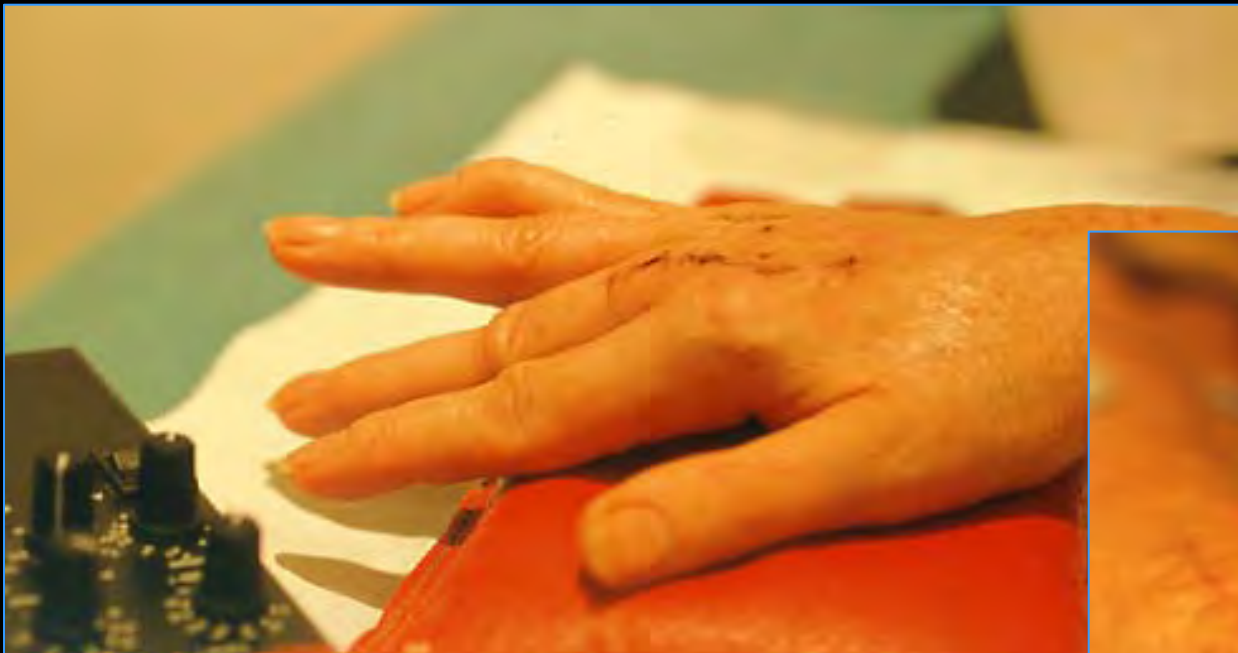
4 ème semaine





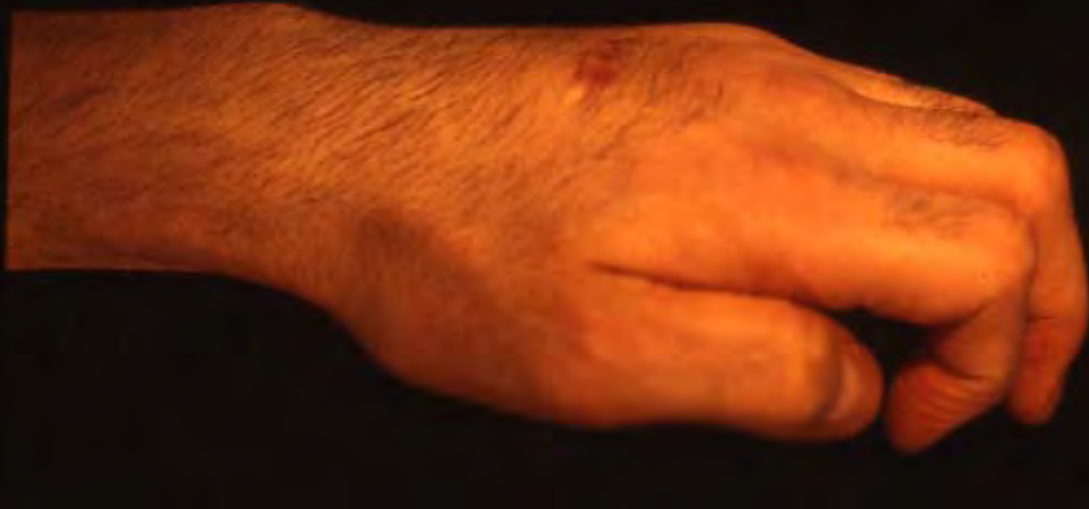syndactylie



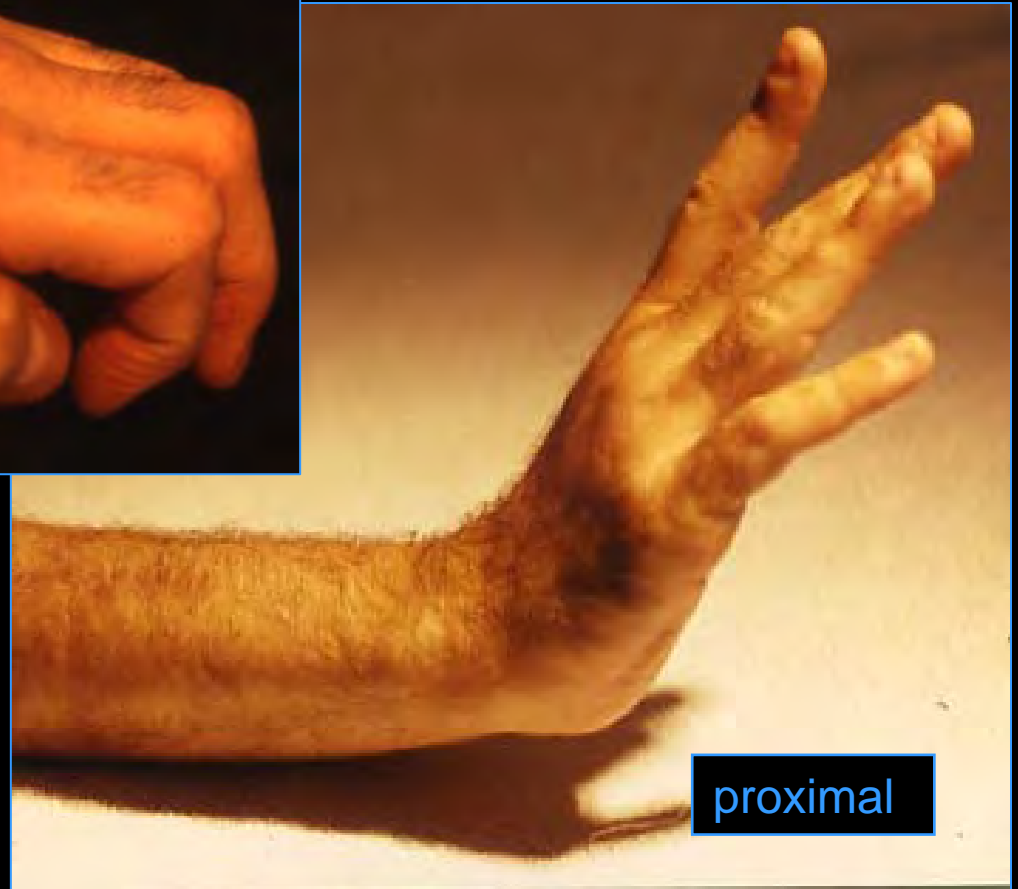


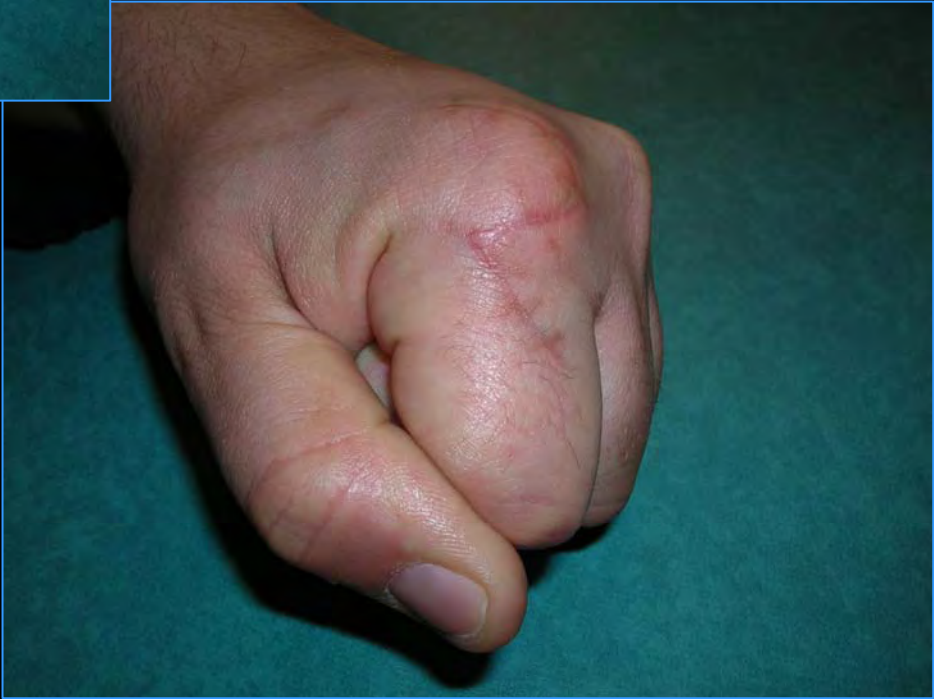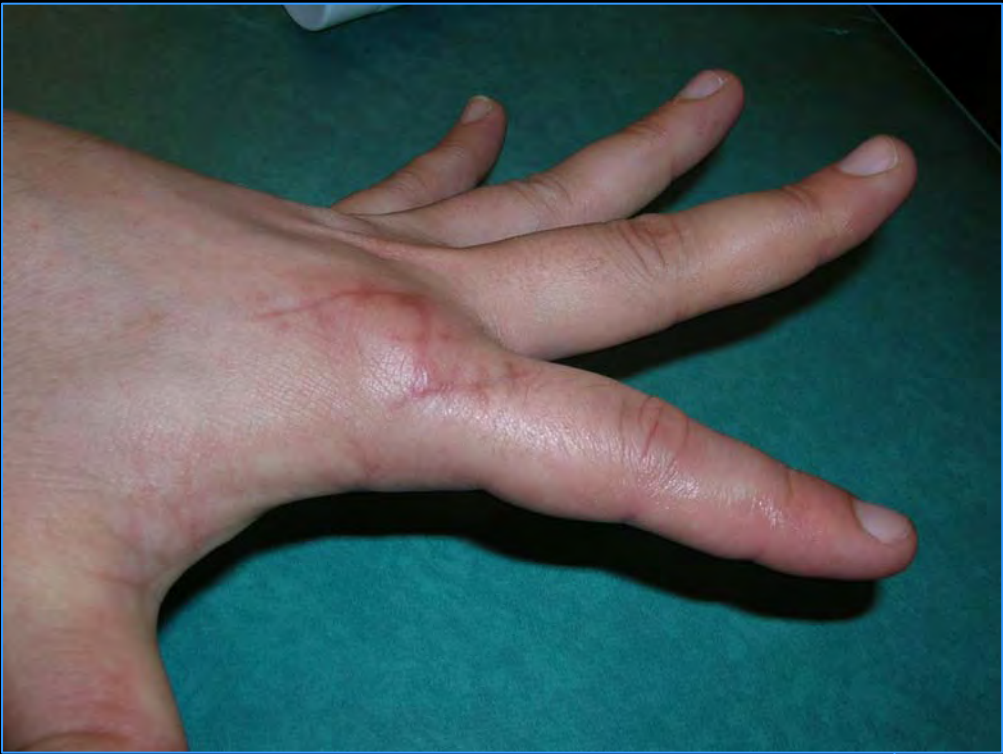Insuffisance du glissement

distal

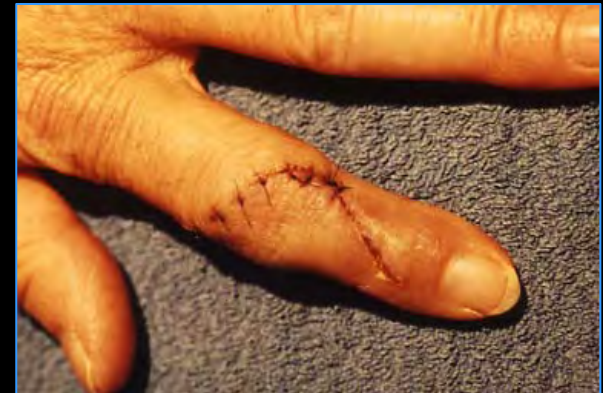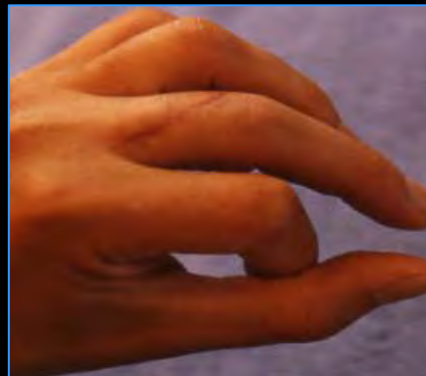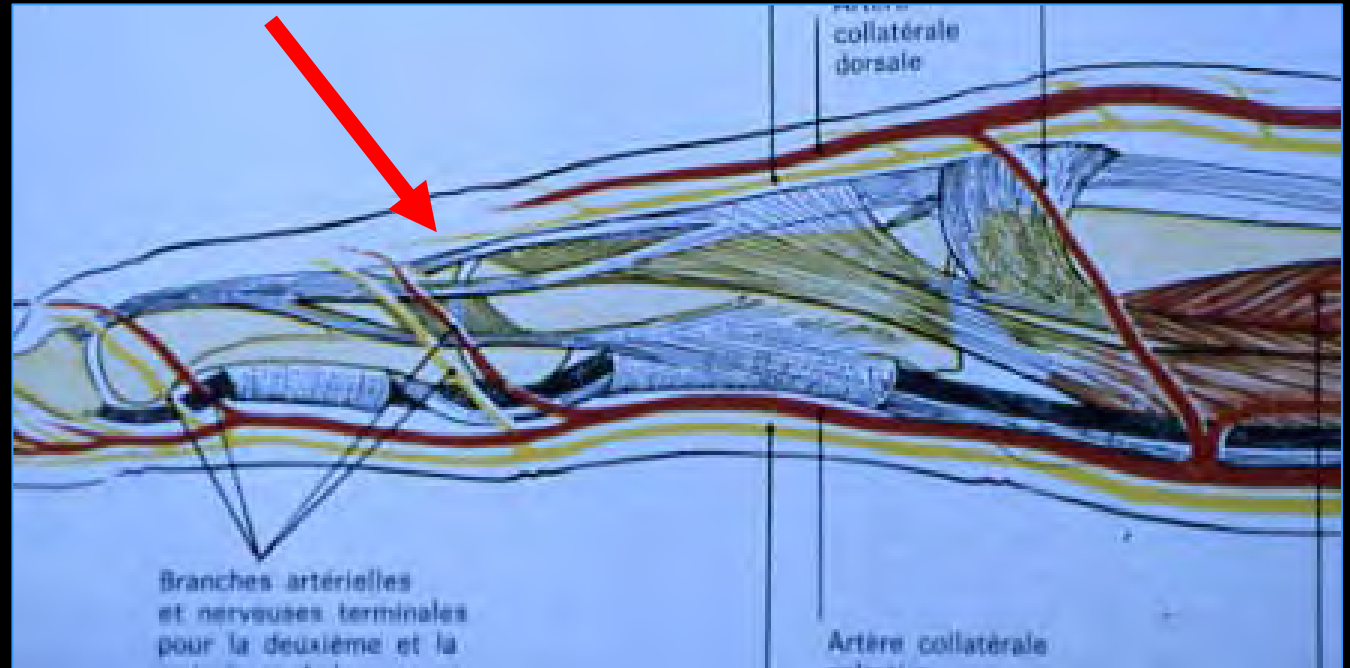


proximal

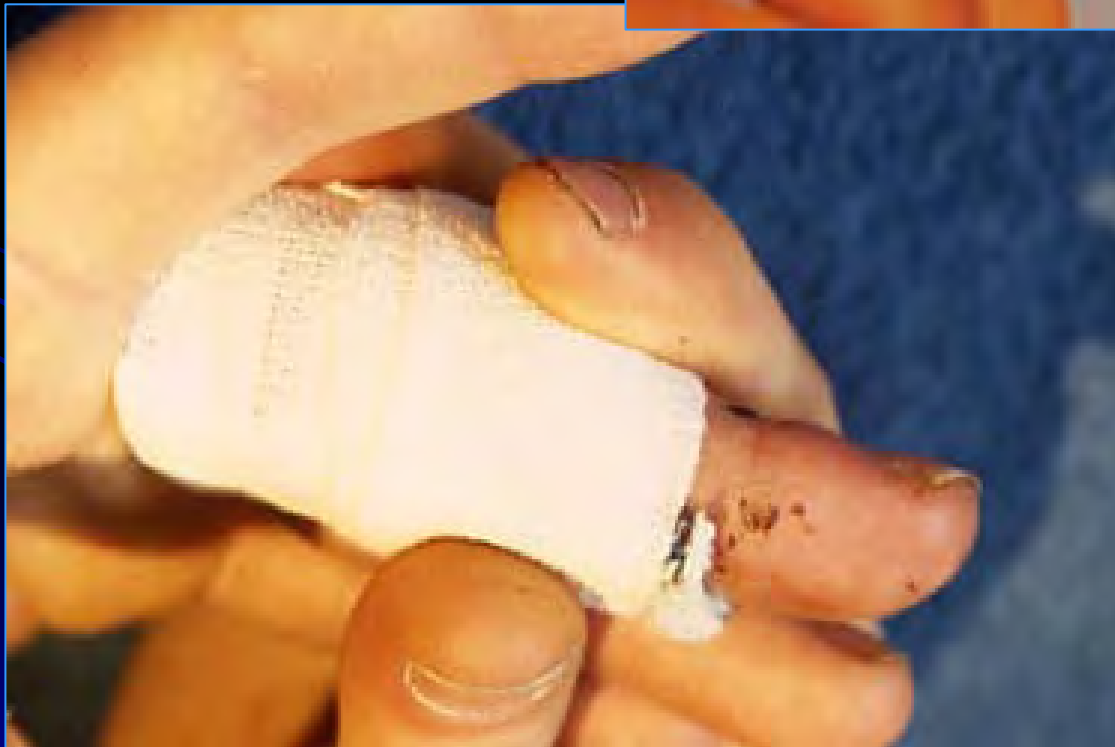
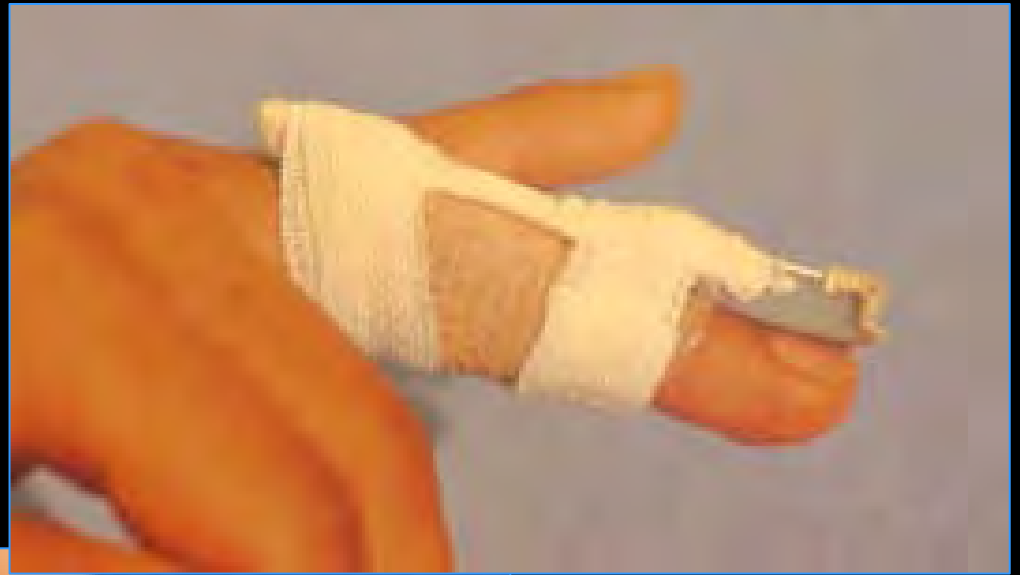


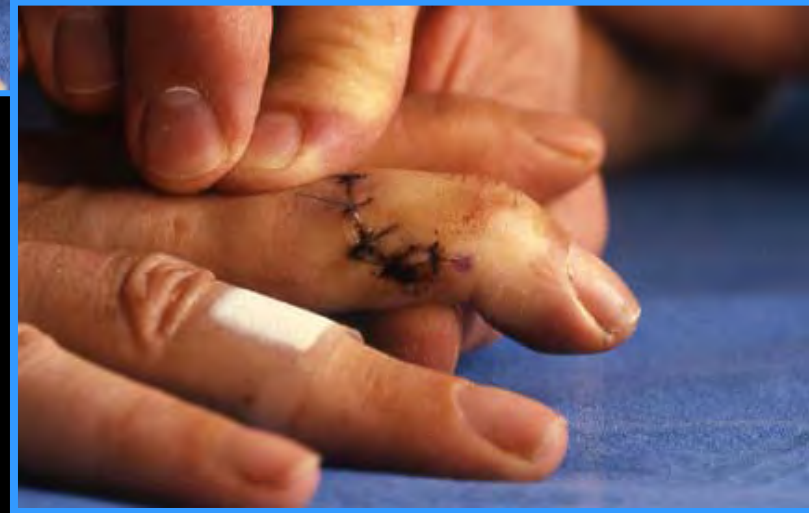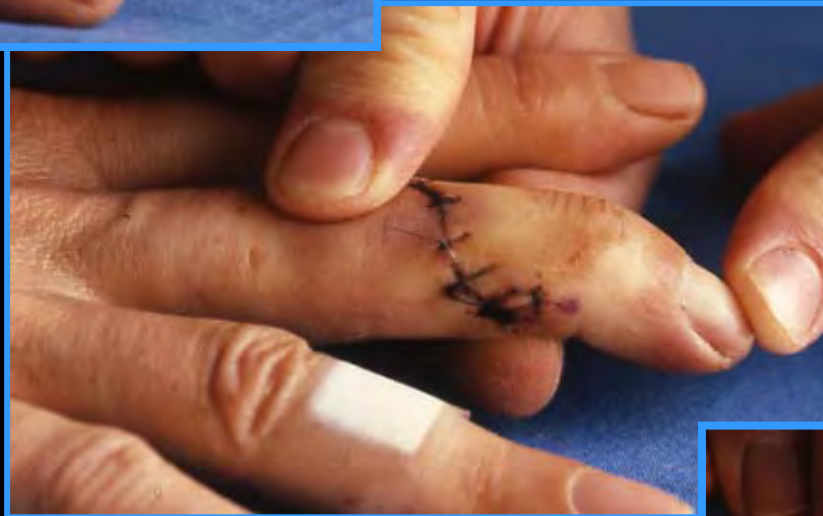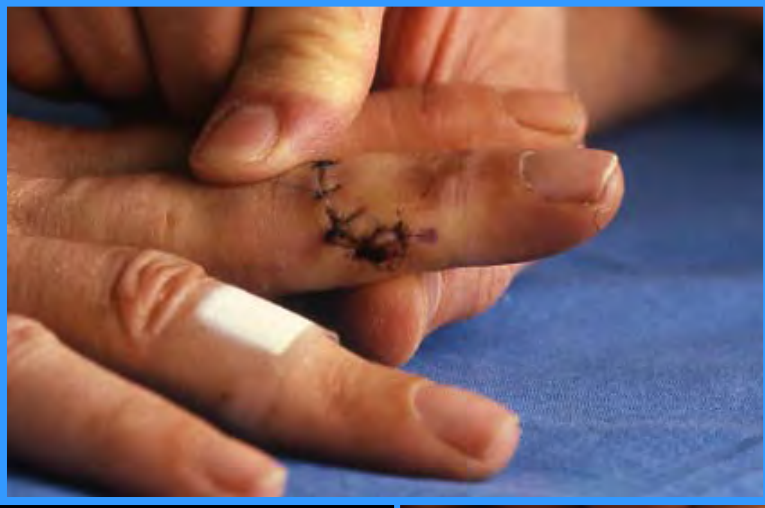Niveau IPP

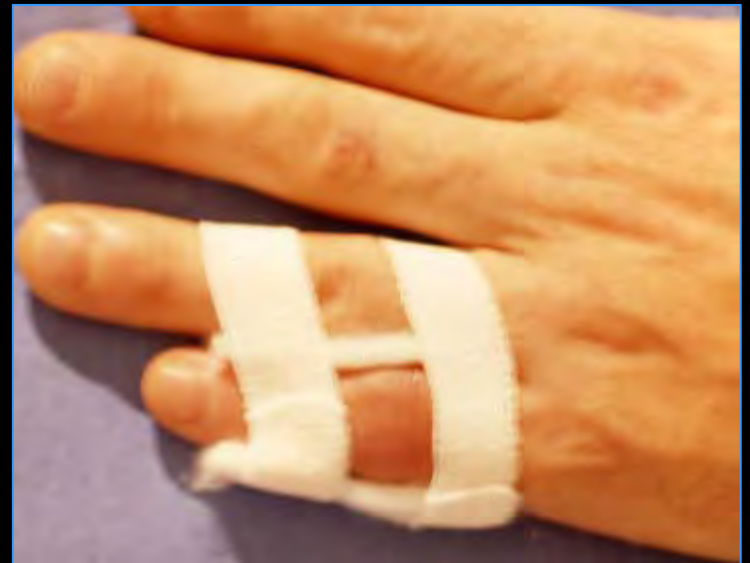
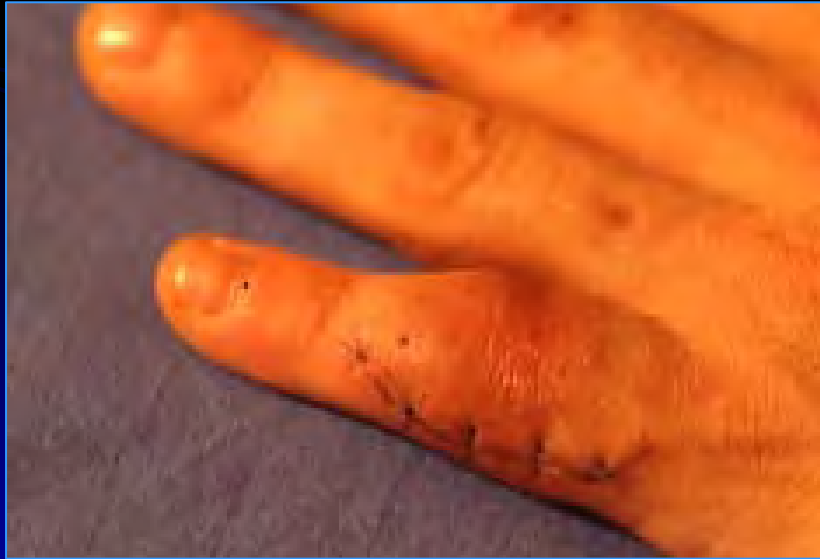
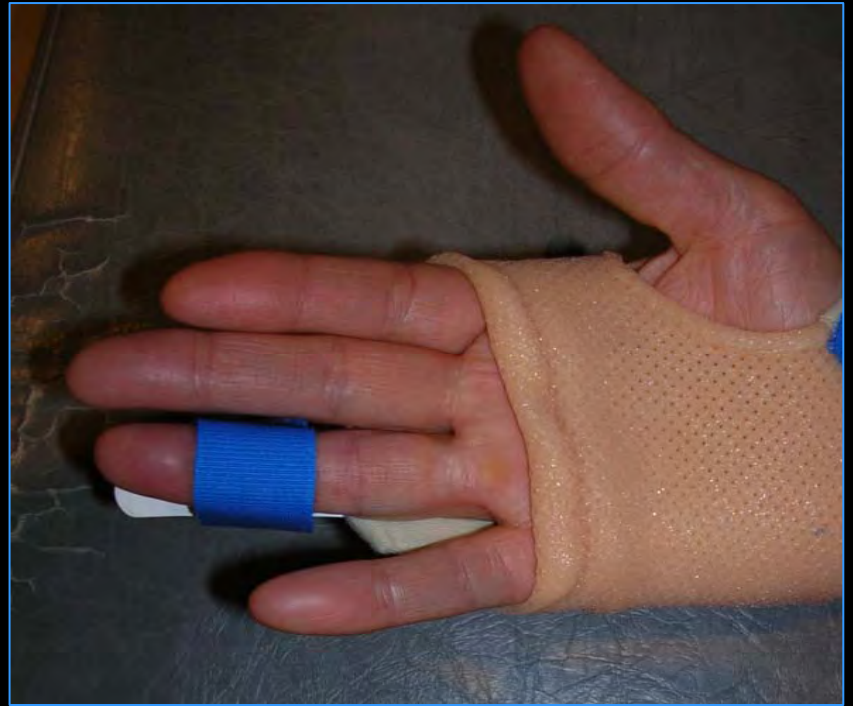
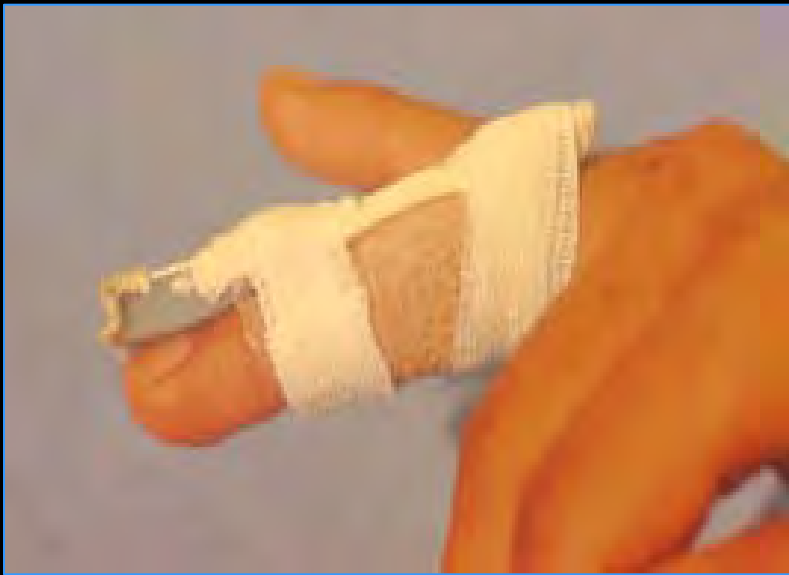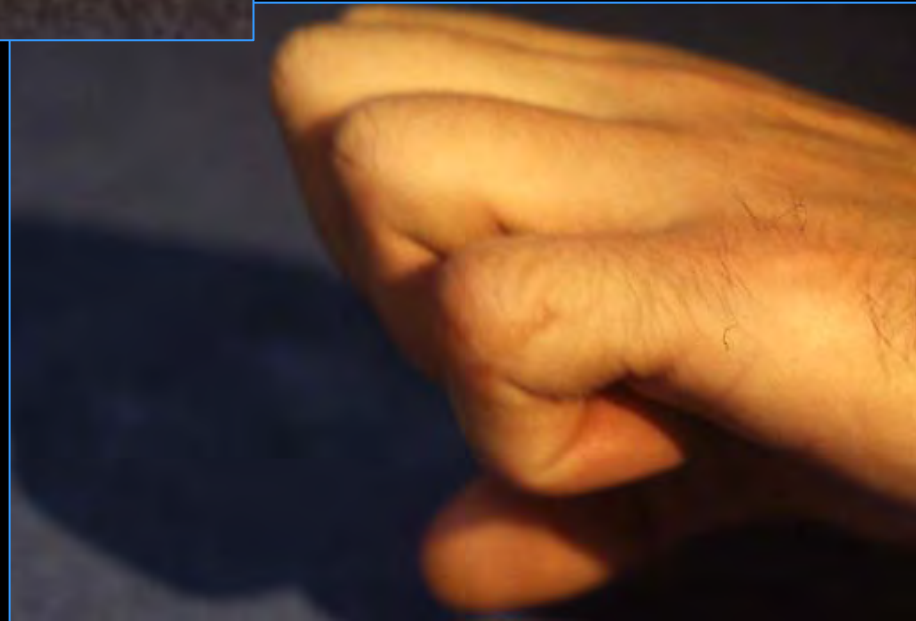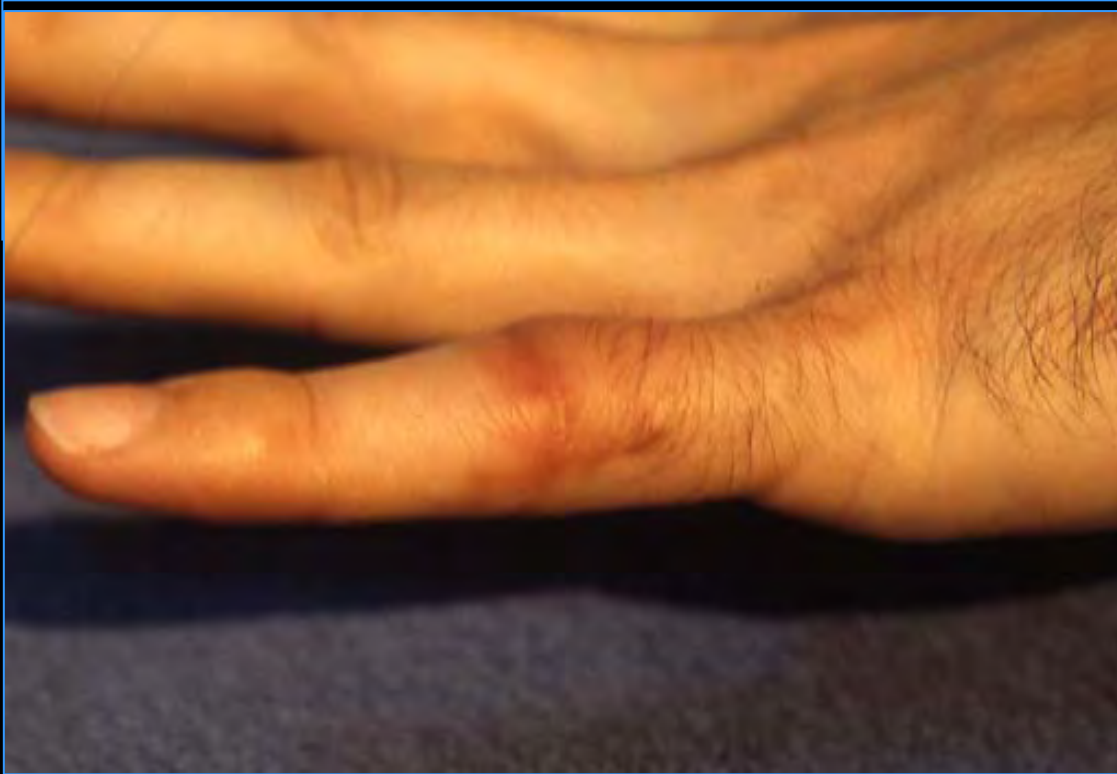IMMOBILISATION SEGMENTAIRE



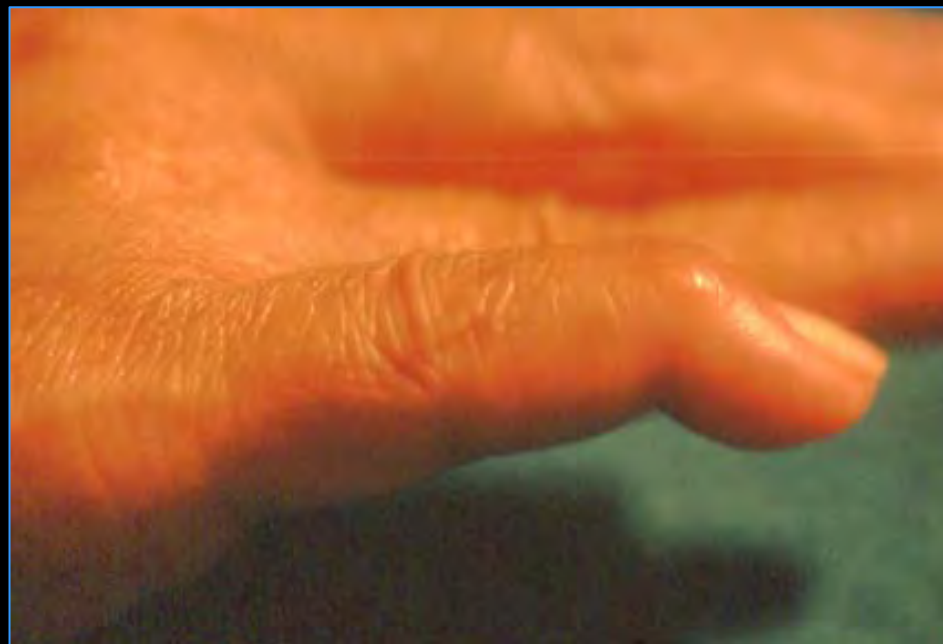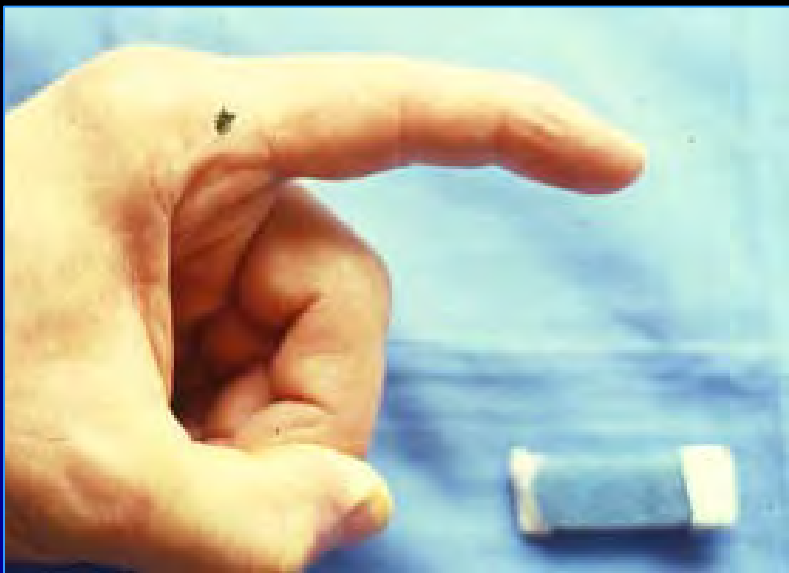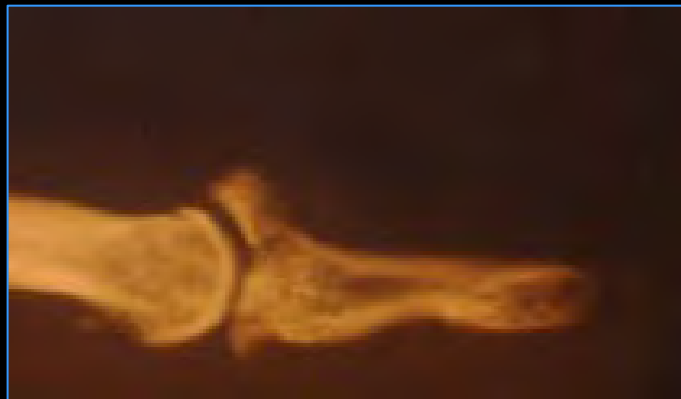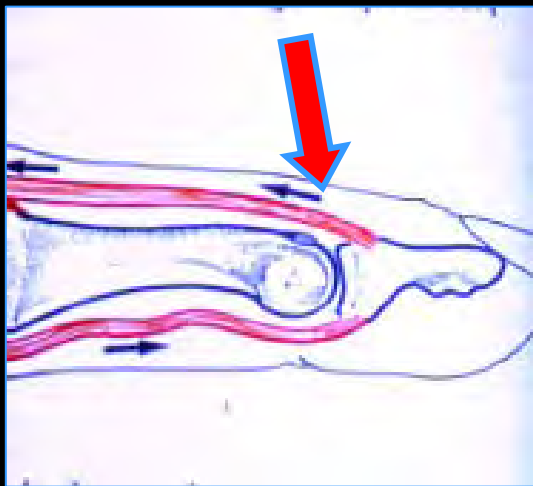
IPD +++



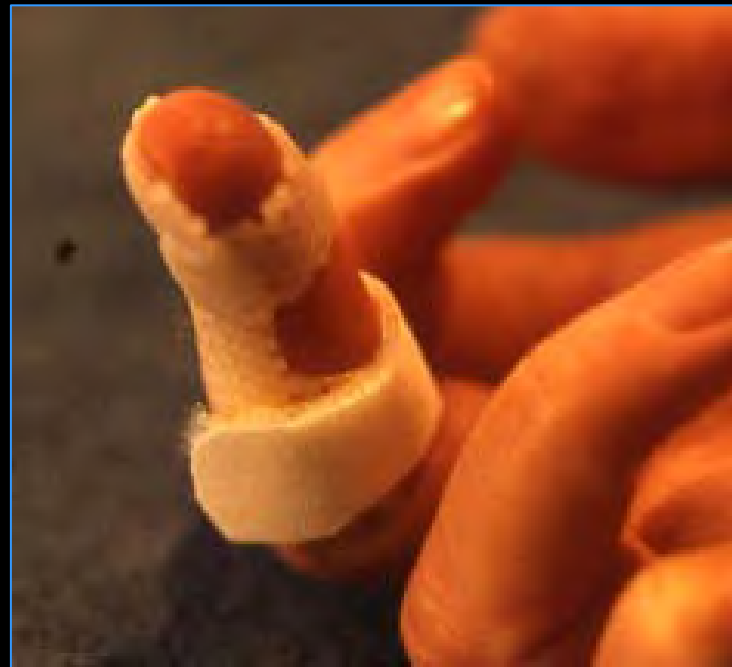
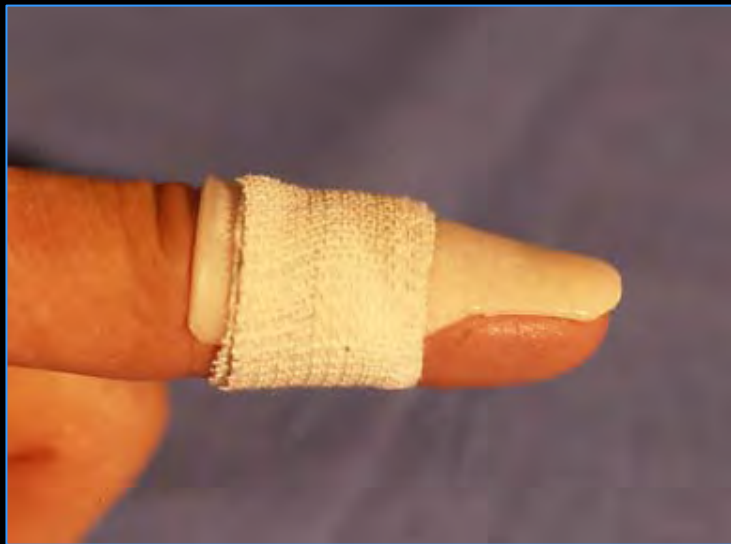


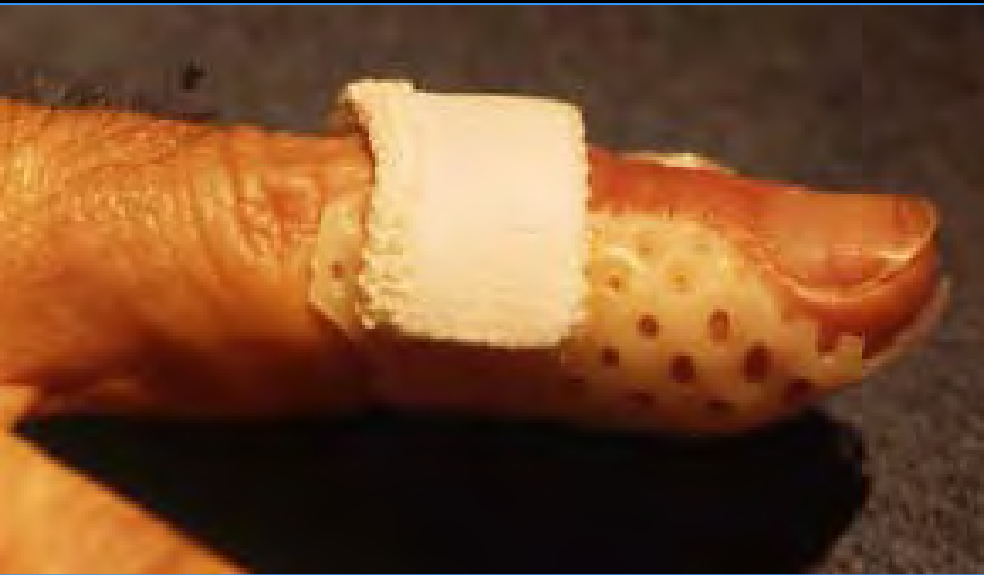
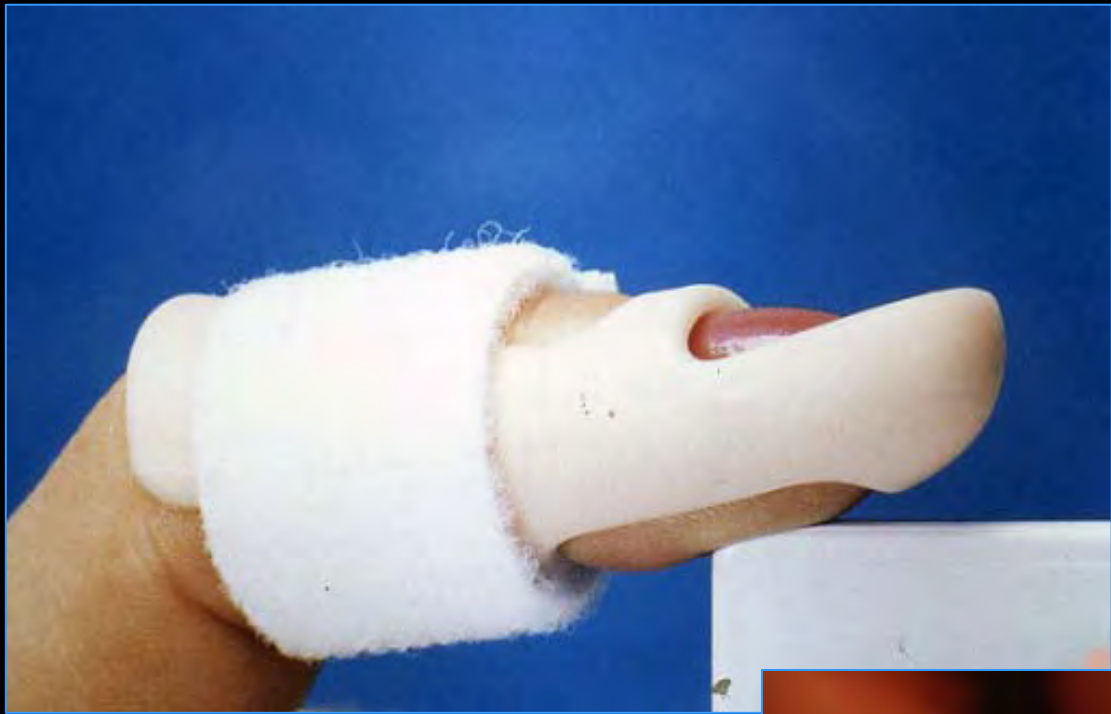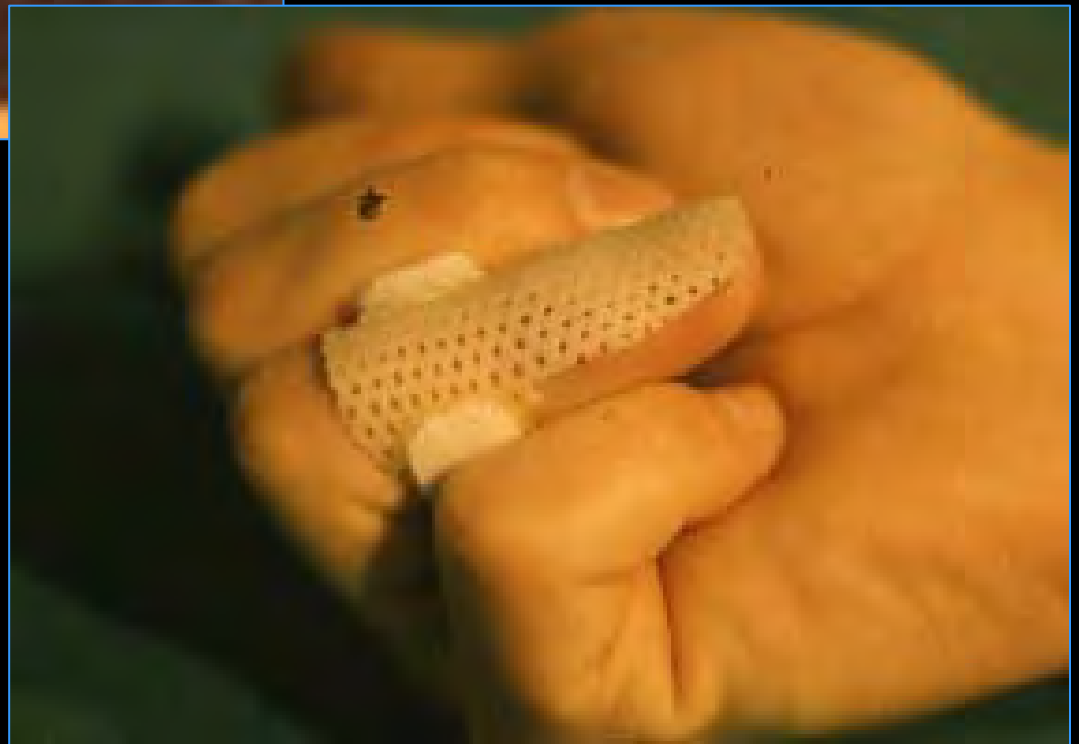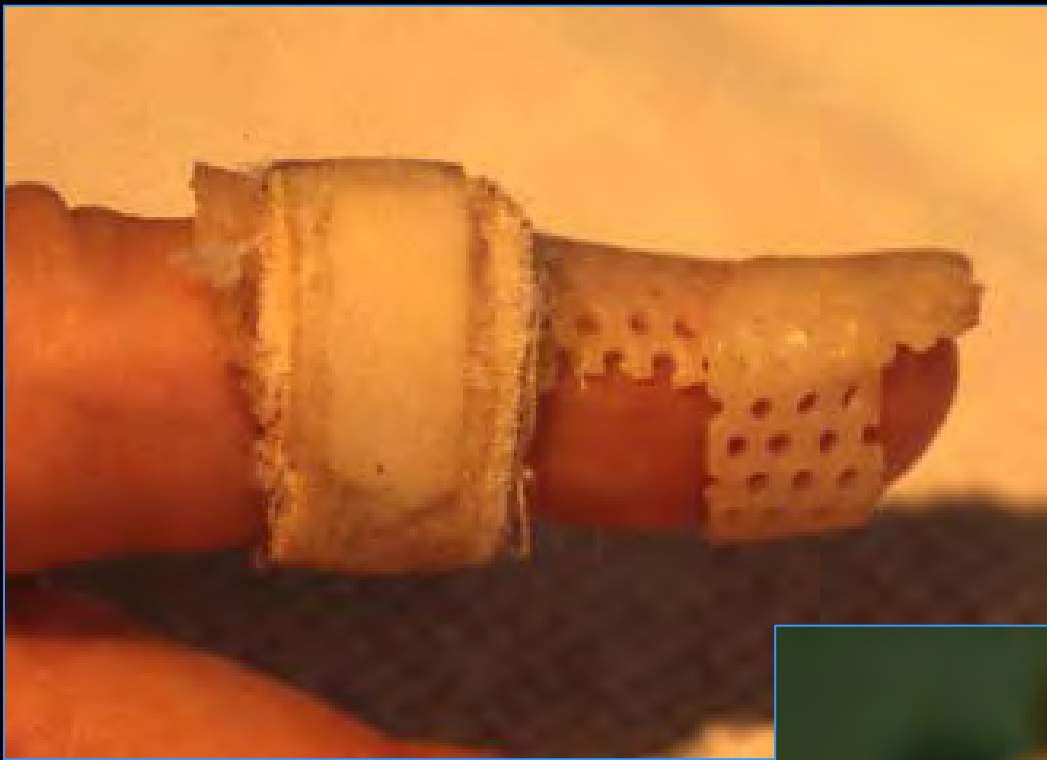Mallet finger

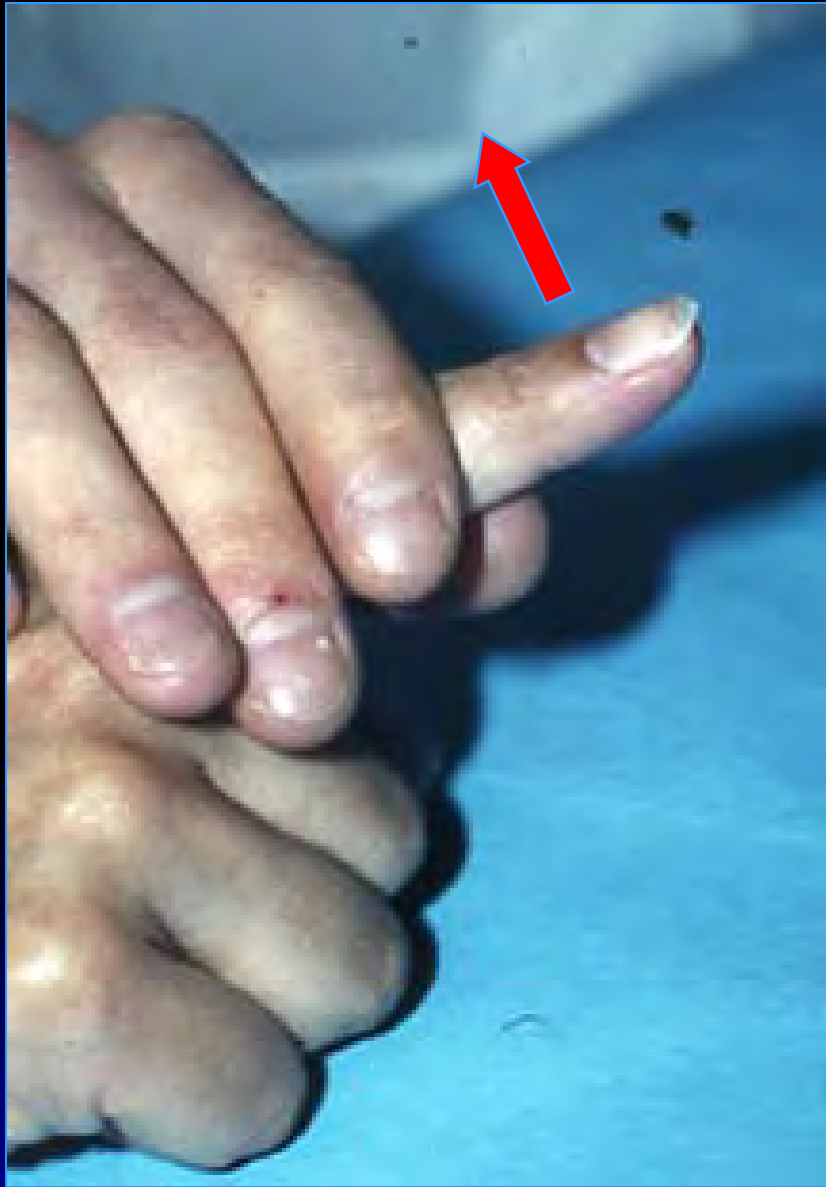


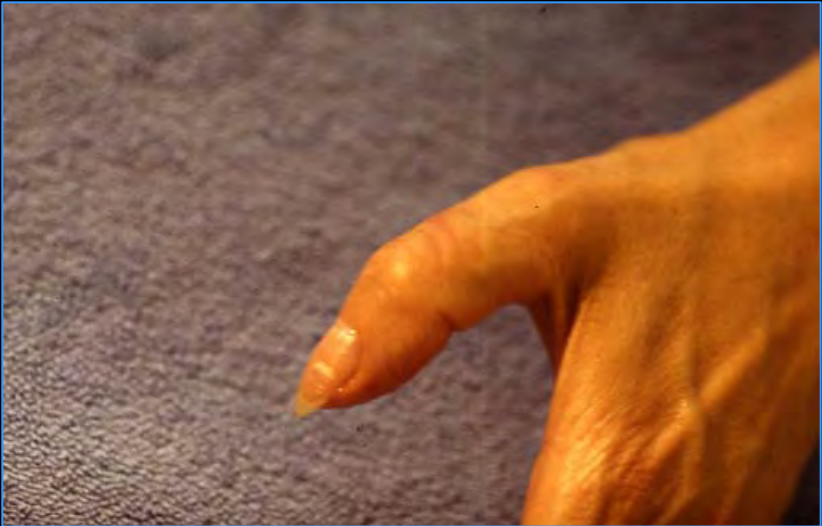
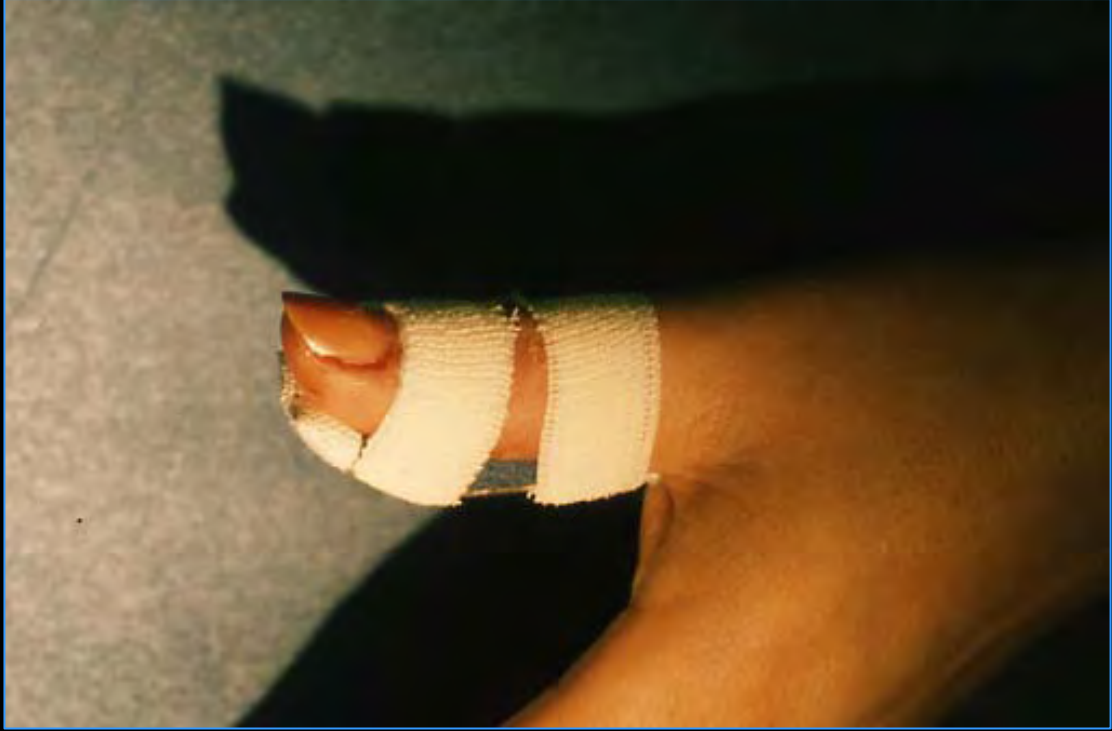
TT ORTHOPEDIQUE 6 SEM



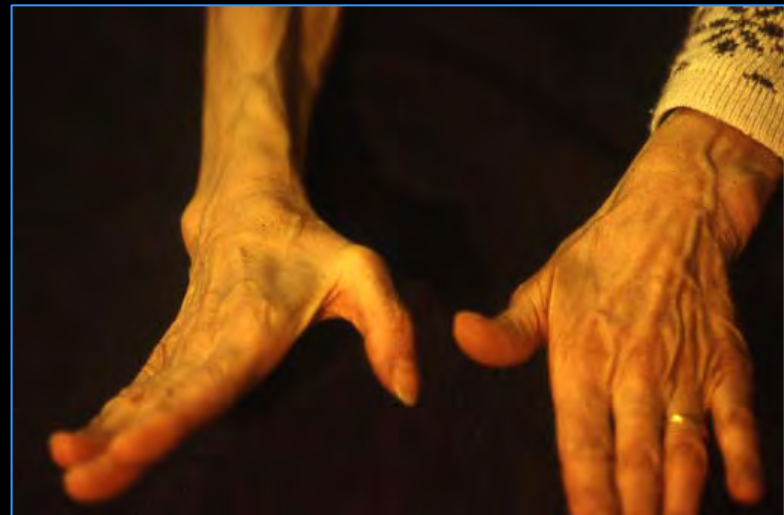


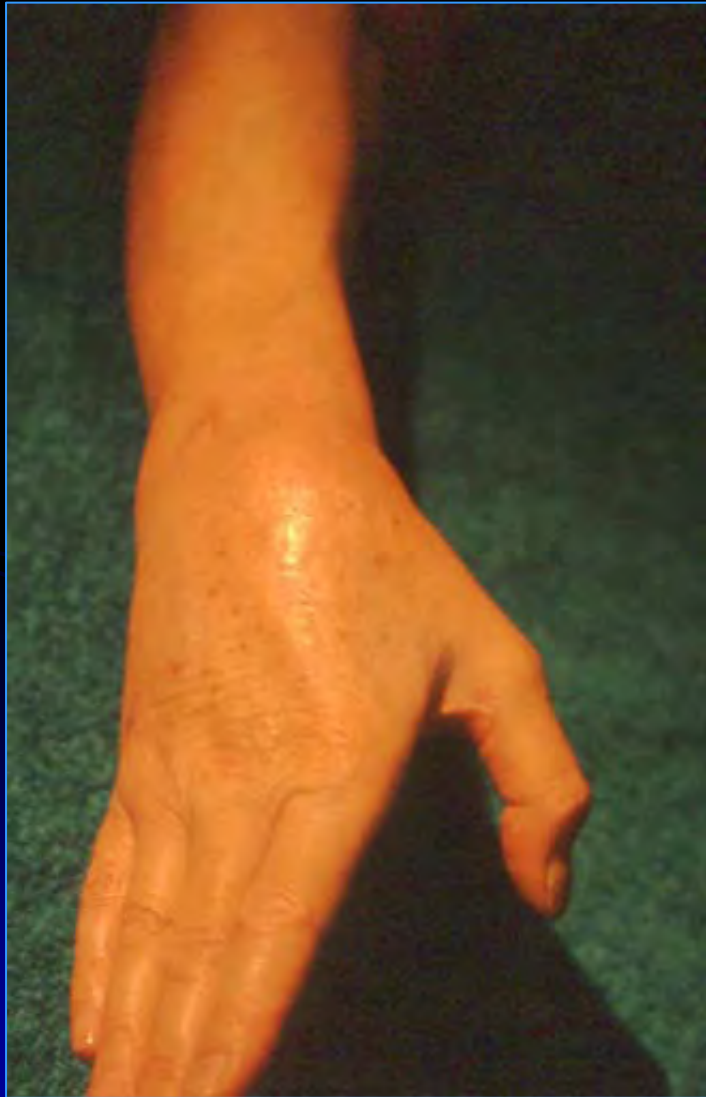




Rupture lg ext

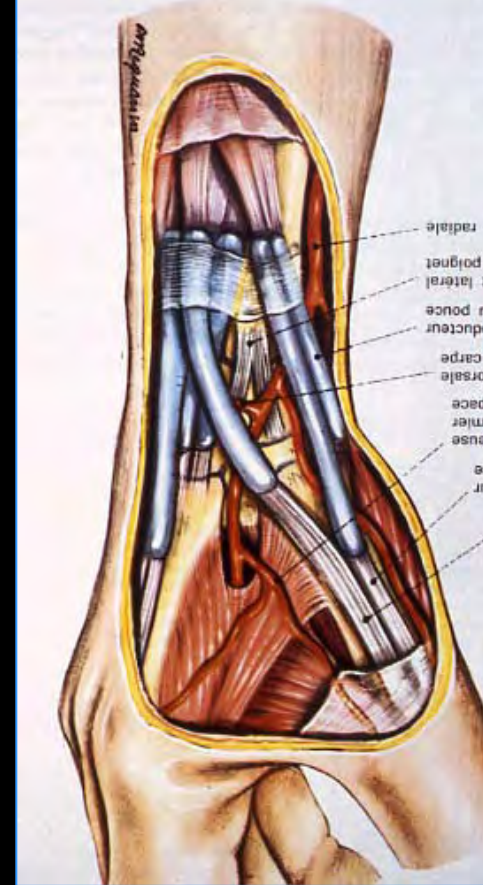
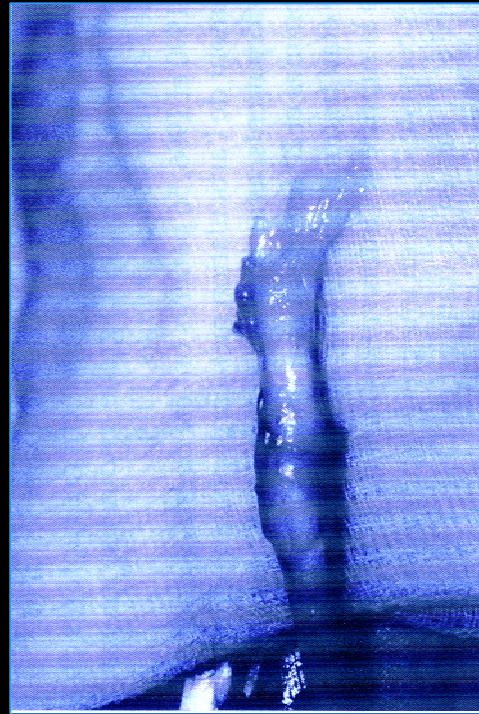
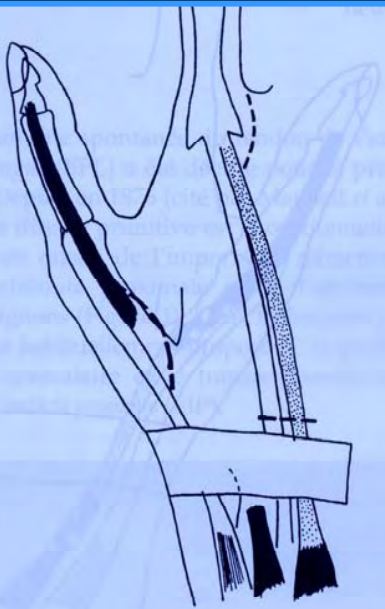



Figure 3
 Transfert de l'*extensor indicis proprius* : tracé des incisions.
Extensor indicis proprius transfer : schema of the incisions.

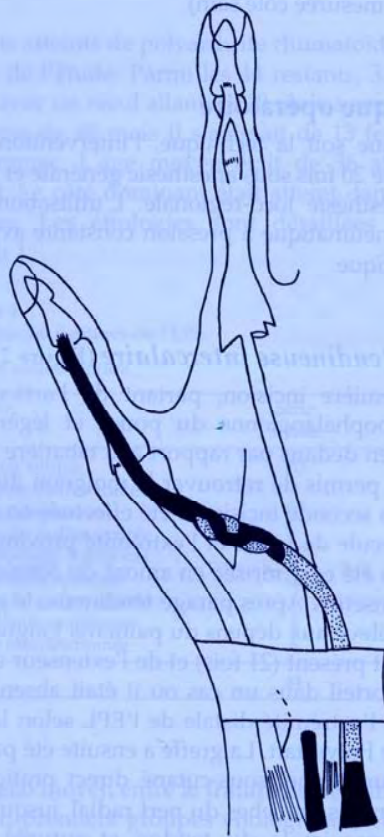
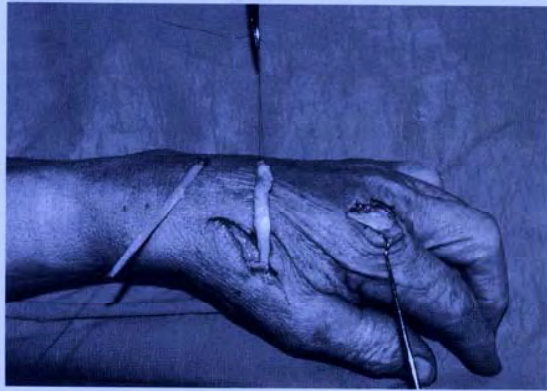
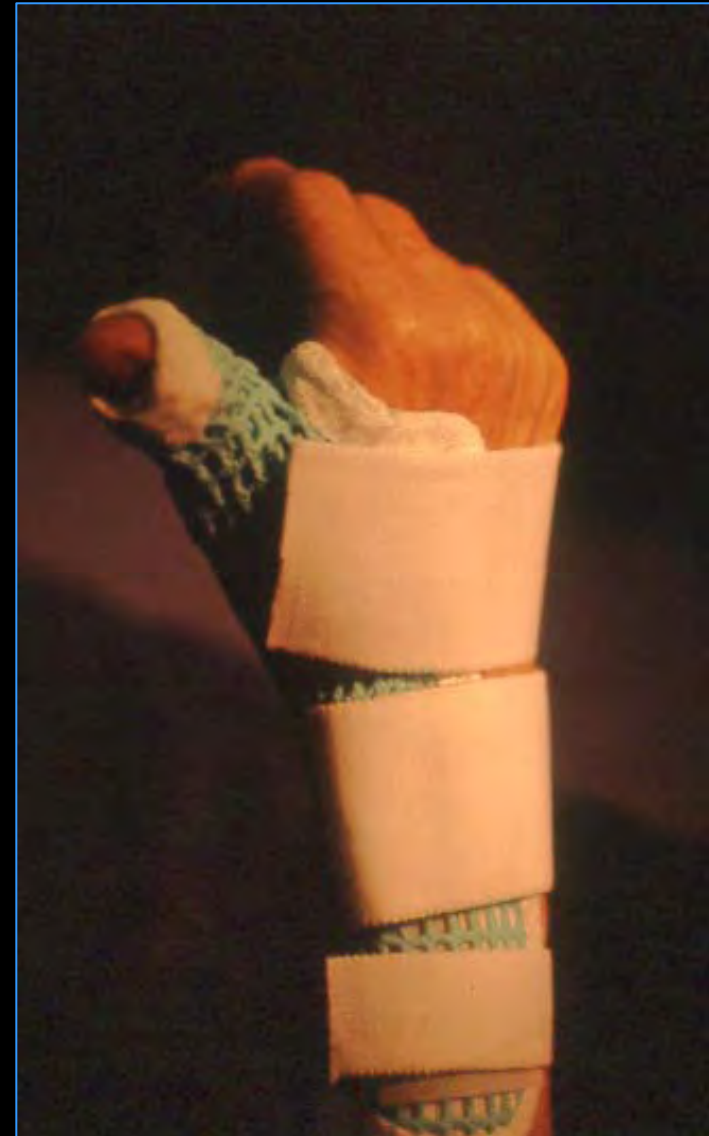
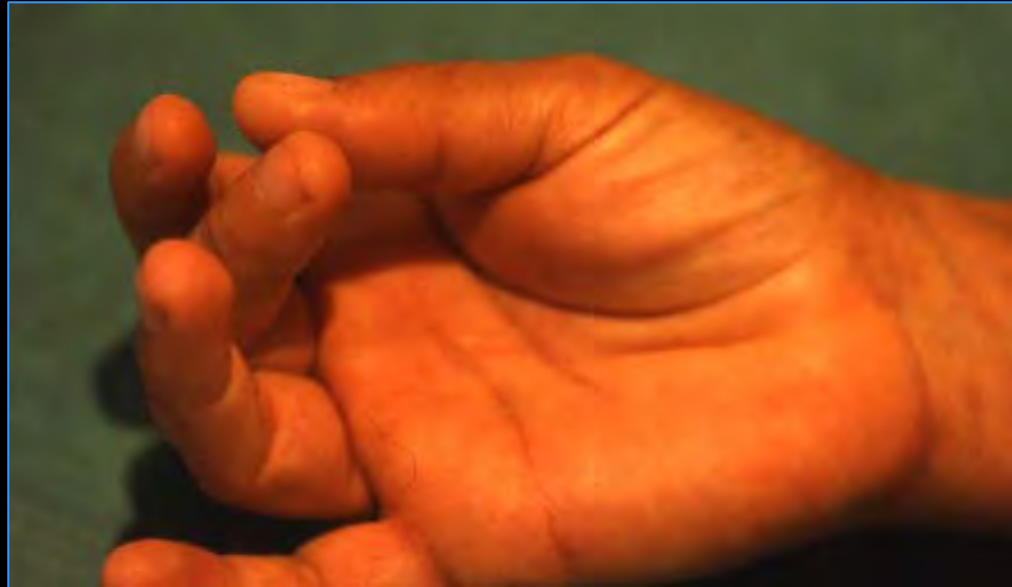
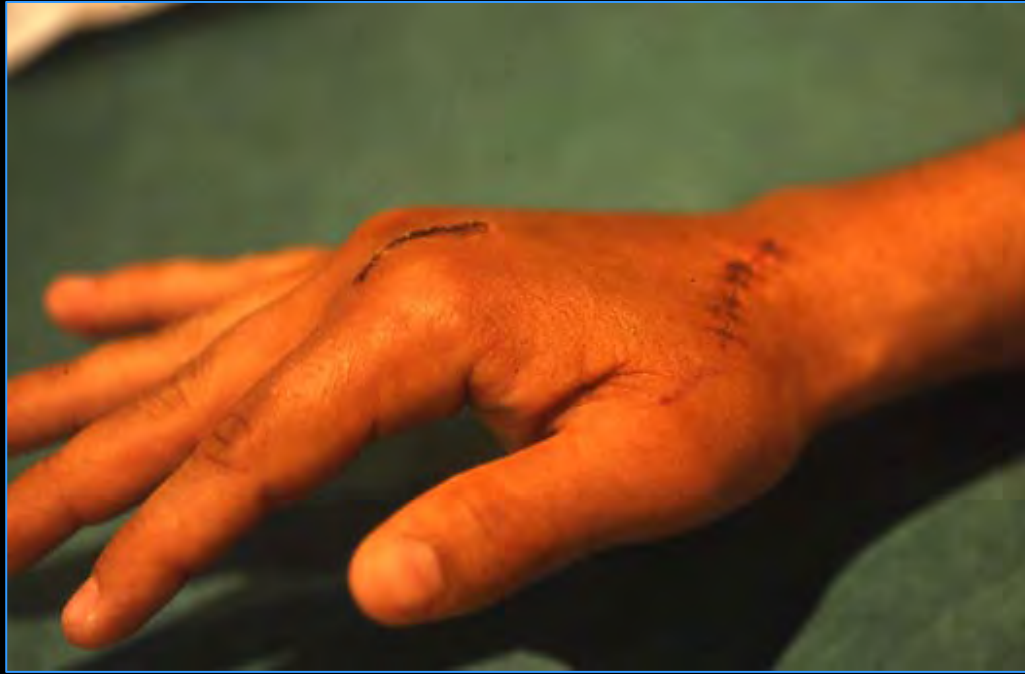
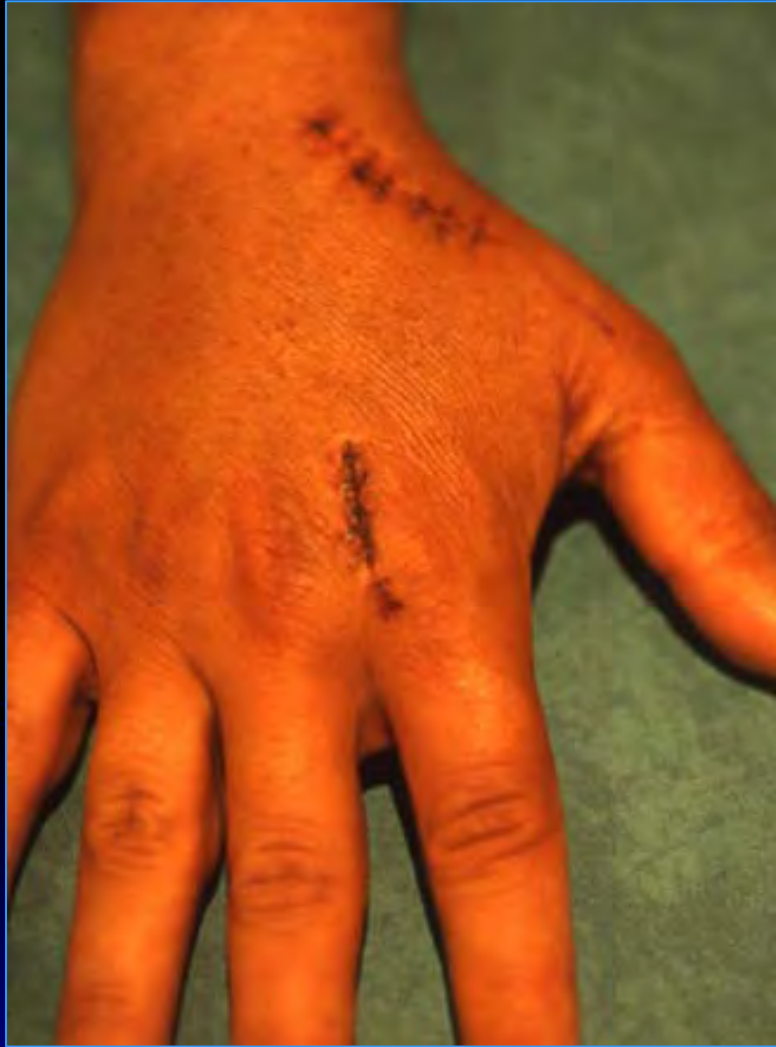Figure 5
 Transfert de l'*extensor indicis proprius* : anastomose selon la technique de Pulvertaft.
Extensor indicis proprius transfer : anastomosis according to Pulvertaft's technique.





**GLISSEMENT
PROXIMAL**



DISTAL



