

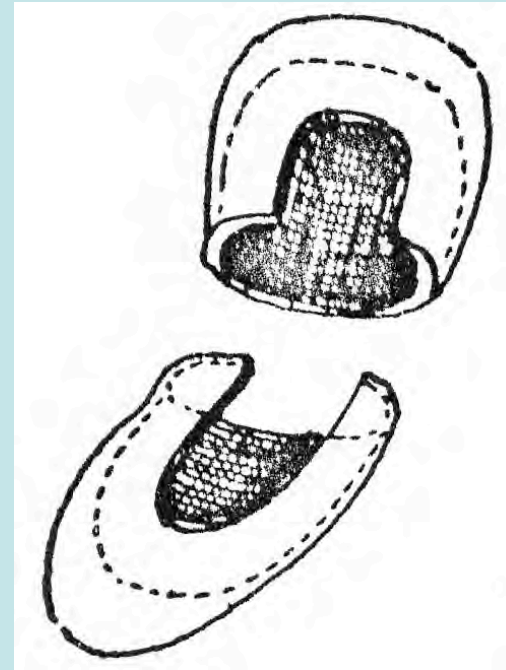
Scaphoid nonunion
Conservative surgery
(osteosynthesis- vascularized and
non-vascularized surgery)

Philippe BELLEMERE
Clinique Jeanne d'Arc
Nantes



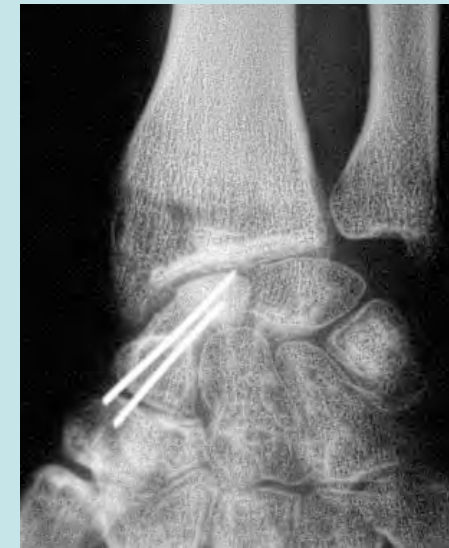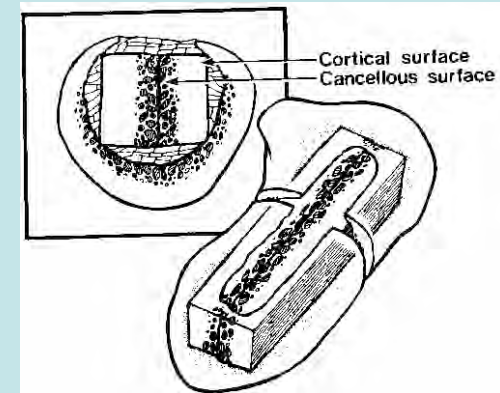
Historic

- Matti 1936
 - Excavation concept
 - Cancellous graft
- Russe 1960
 - Anterior approach
- Verdan 1968, Fisk 1970
 - Bone fixation



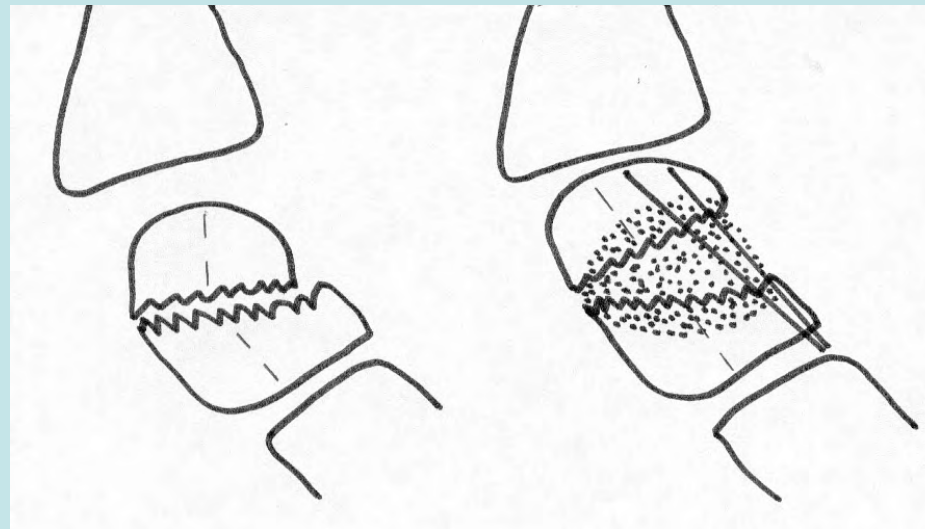
Historic

- Russe 1960
 - K-wires if instability after bone grafting
- Cooney 1980, SOFCOT 1987
 - Improves the rate of consolidation



Basic principles for treatment

- Scar tissue excision + excavation
- Correction of the scaphoid malalignment
- Bone grafting
- Bone fixation during the consolidation period with simple and accurate technique



Approach

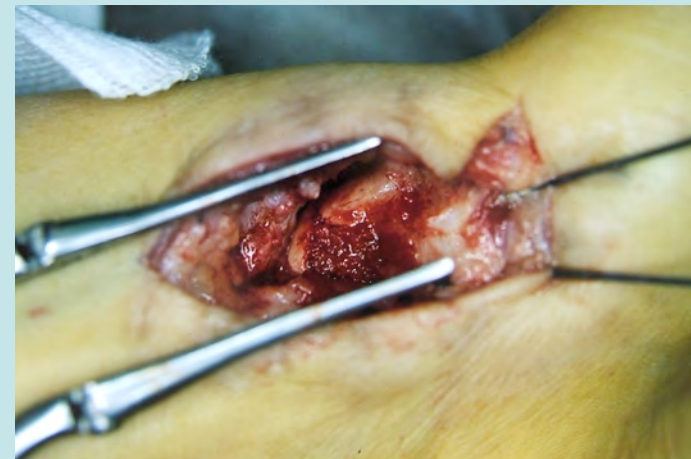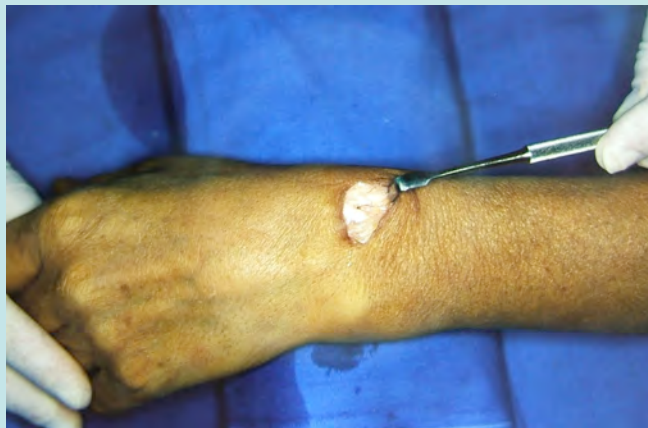Scaphoid nonunion

Proximal pole (I,II)

Waist (III, IV, V)

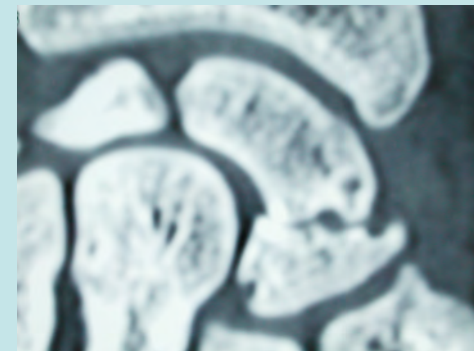
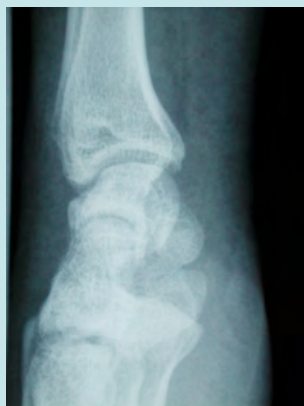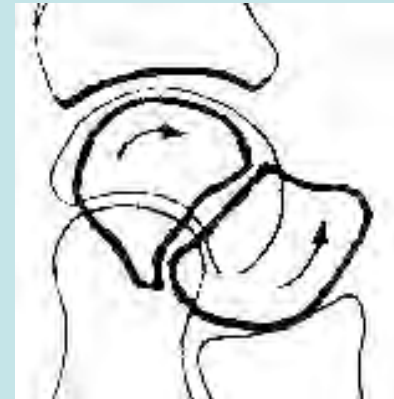Dorsal

Palmar



Correction of the malalignment

- Correction of
 - Scaphoid flexion
 - Scaphoid malrotation
 - Adaptative carpal alignment



Bone grafting

- Cortico-cancellous
 - structural component
- Cancellous
 - better osteogenic potential
- Iliac crest or radius? *Tambe J Hand Surg (Br) 2006*
 - no difference for consolidation
 - more complications with iliac crest



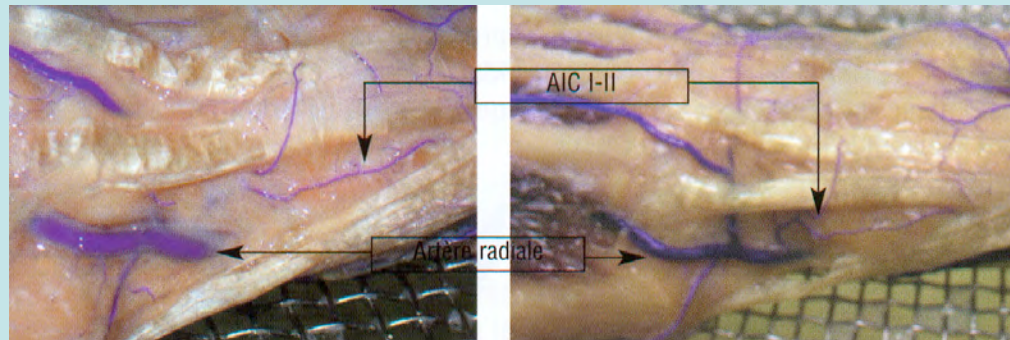
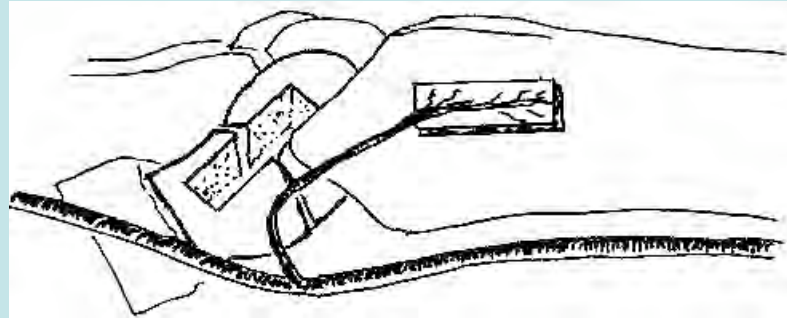
Why cancellous graft ?

	<i>Cancellous graft</i>	<i>Corticocancellous graft</i>
• Filling the defect	easy & complet	difficult & partial
• Bone quantity	++++	++
• Primary stability	++ (packed)	++
• osteogenic power	YES	LESS
• osteoclastic resorption	NO	YES

Vascularized bone graft

Greater mechanical properties

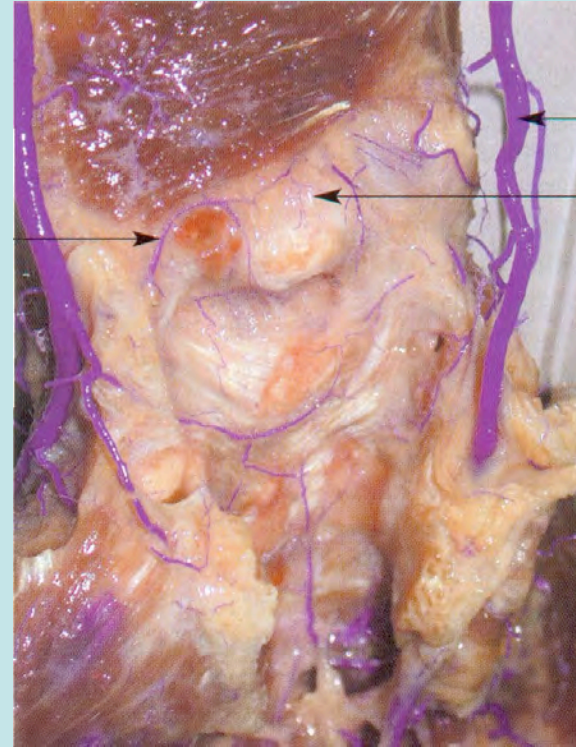
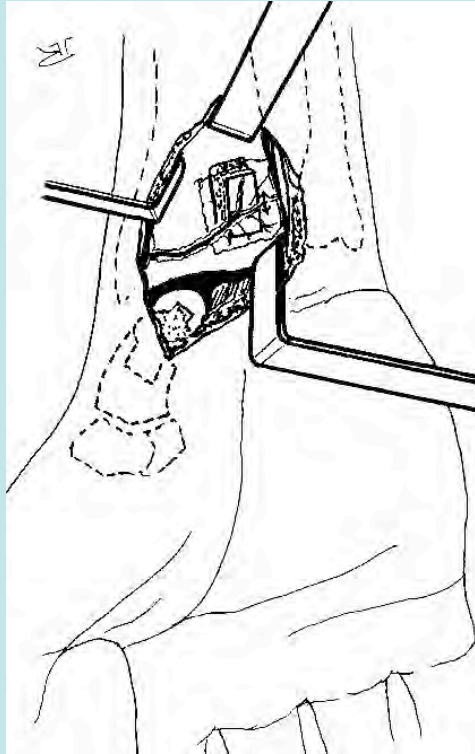
Quicker consolidation



Radial styloid (Zaidemberg 1991)

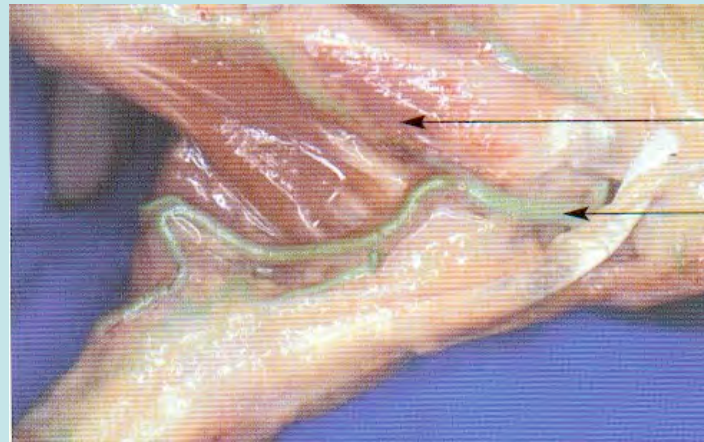

Partial styloidectomy often needed

Vascularized graft



Anterior radius (Kulmann 1987, Mathoulin)

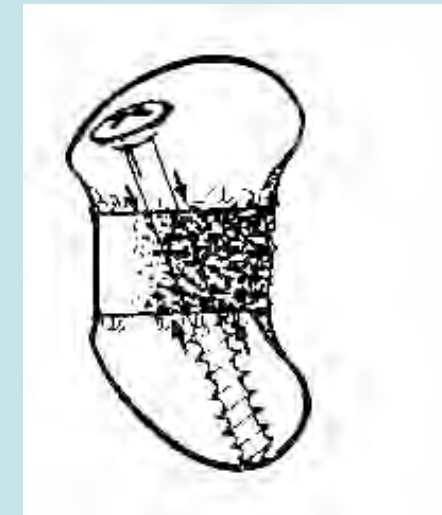
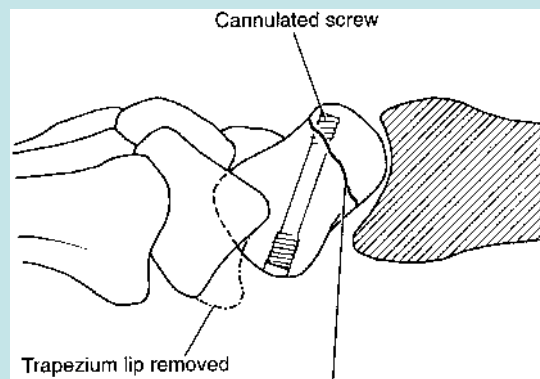
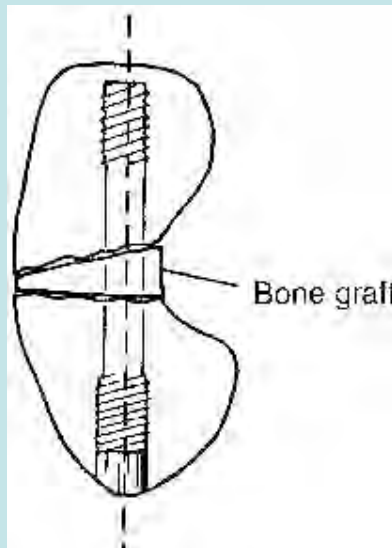
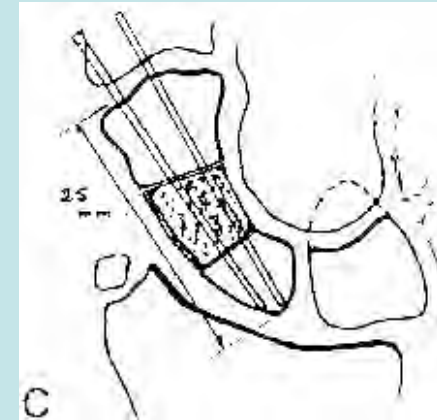
Vascularized bone graft



2nd metacarpal (Brunelli 1992)

Fixation

- Wires
- Screw AO and like
- Herbert screw (1984) and like
 - Need of compression ?

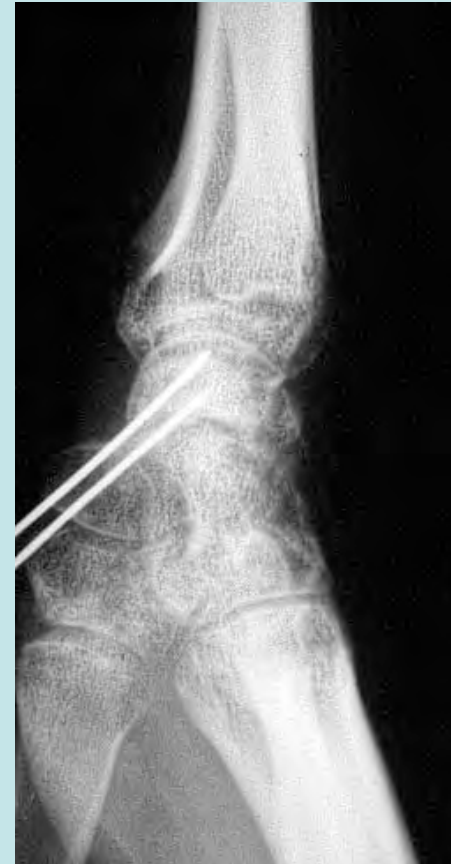

Keep the place for the bone rather for the screw. Please !

Why Kirschner-wires ?

- Compression is not necessary
- Easy procedure
- Wide range of positioning
- Minimal bulkiness
- Minimal damage to ST joint
- Anterior positioning = strut
- Removal is easy
- Low cost

Drawback = removal



Scaphoid non union without arthritis

Proximal pole (I,II)

Waist (III, IV, V)

Dorsal

Palmar

AV

Non AV

AV or failure

Non AV

I

II

Cancel.graft
+ 2 screws

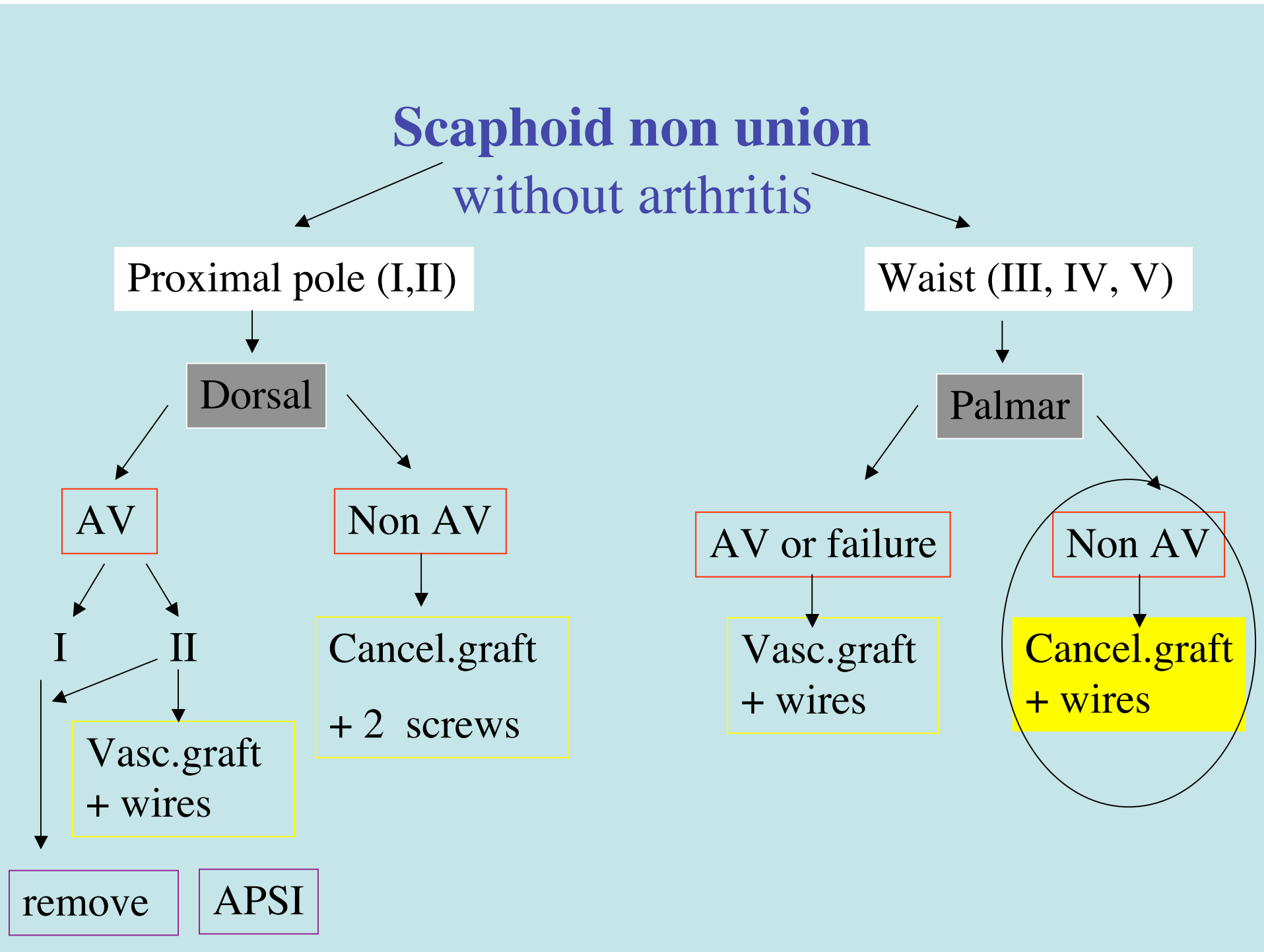
Vasc.graft
+ wires

Cancel.graft
+ wires

Vasc.graft
+ wires

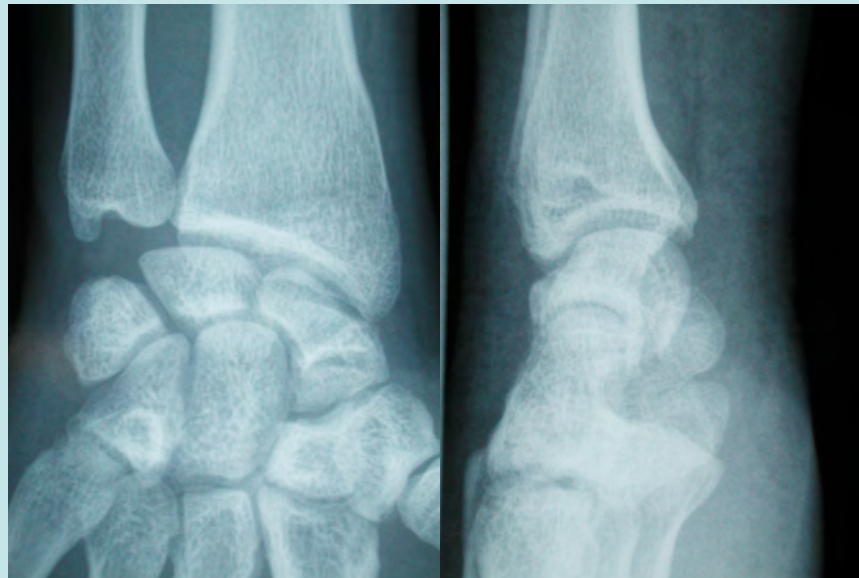
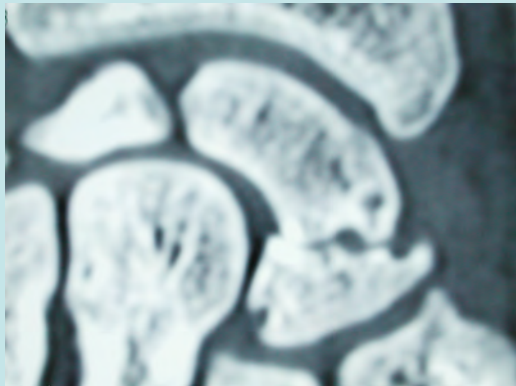
remove

APSI

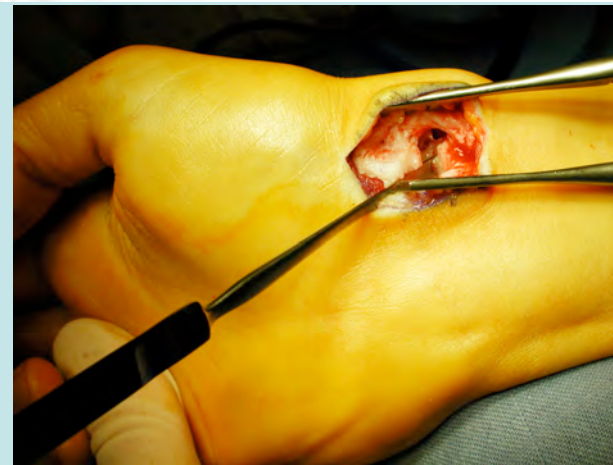
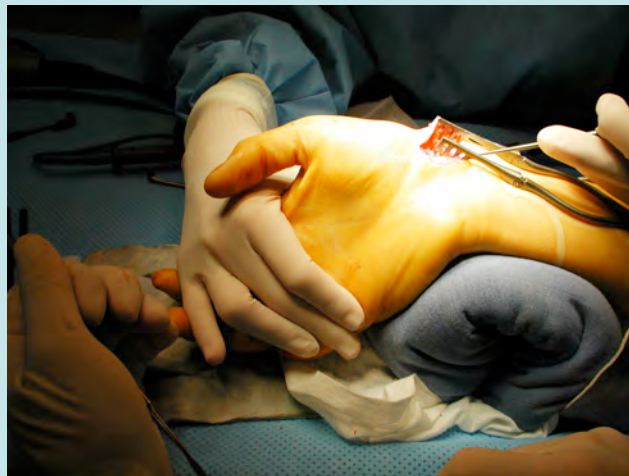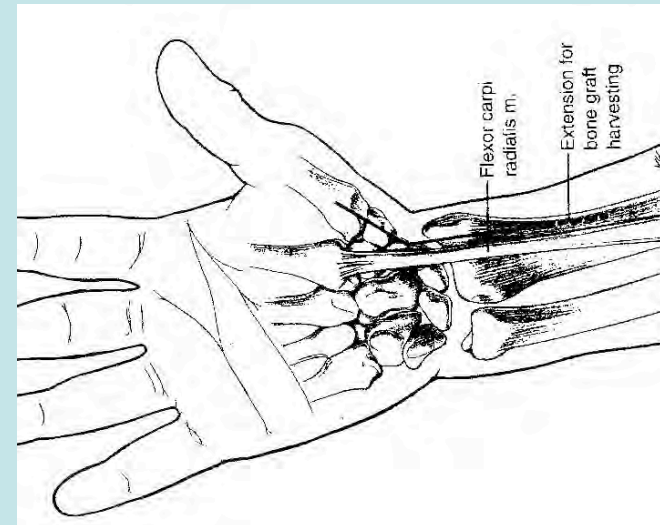

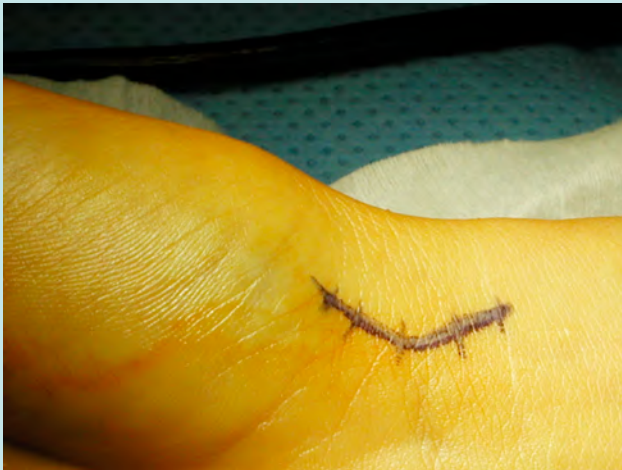
Surgical technique

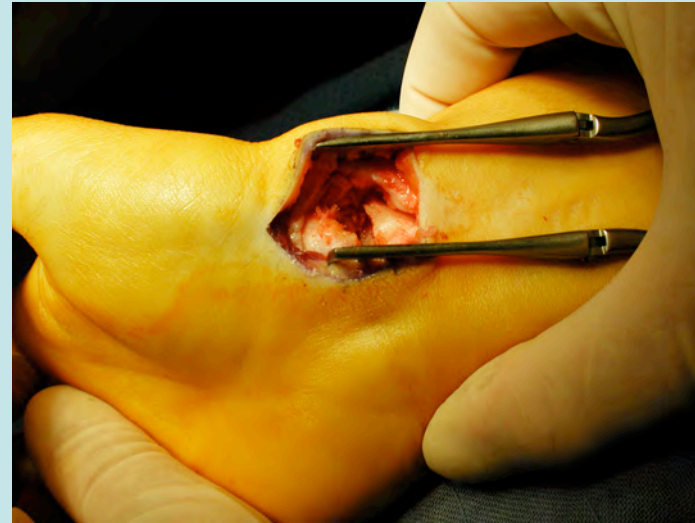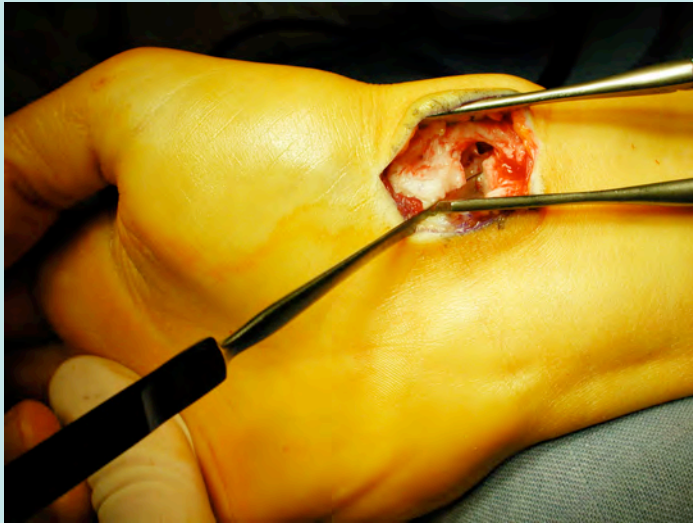
male, 22,
traffic injury 1 year ago
hockey player
dominant side



Anterior approach and exposition



Excavation and graft



Cancellous graft from iliac crest

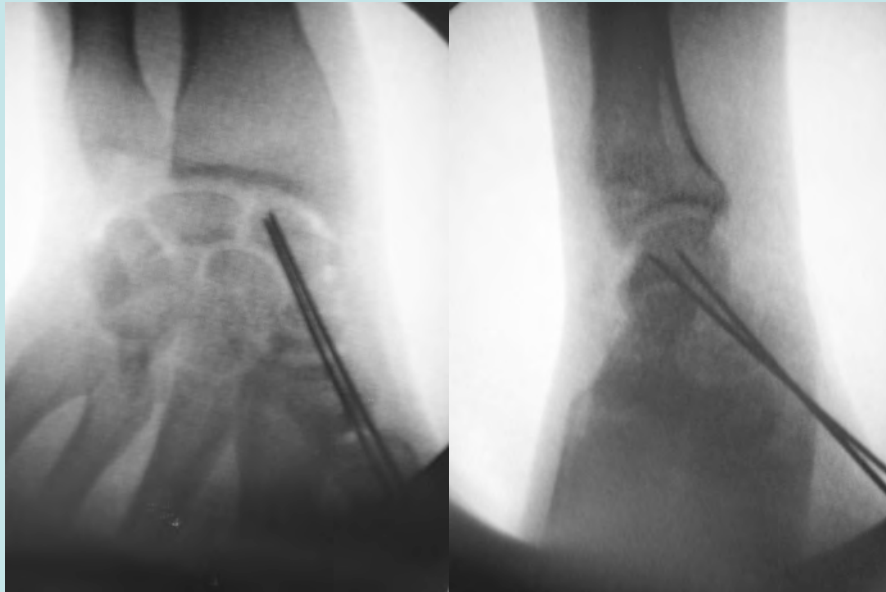
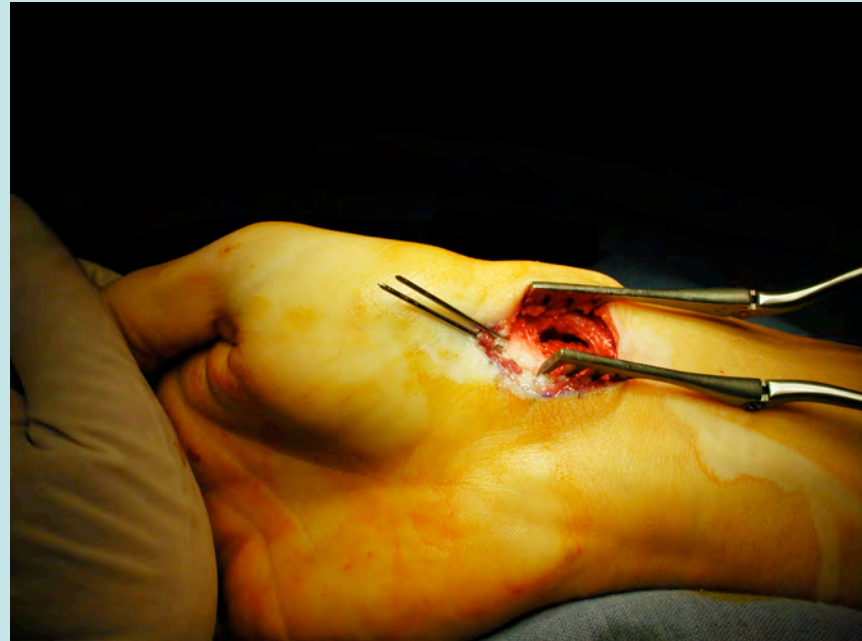Packed graft

Manual axial compression

Fluoroscopic checking

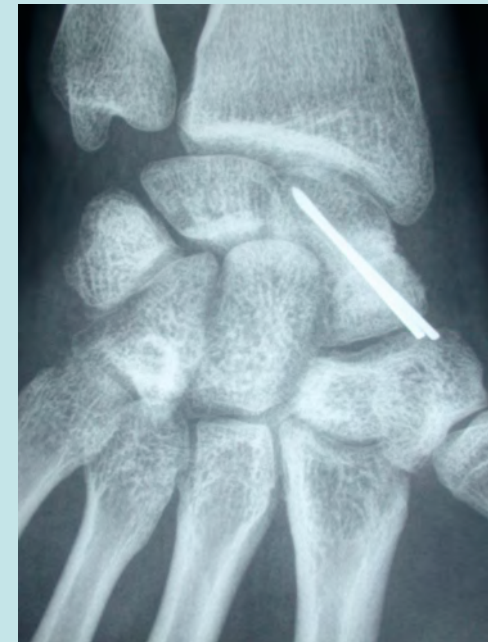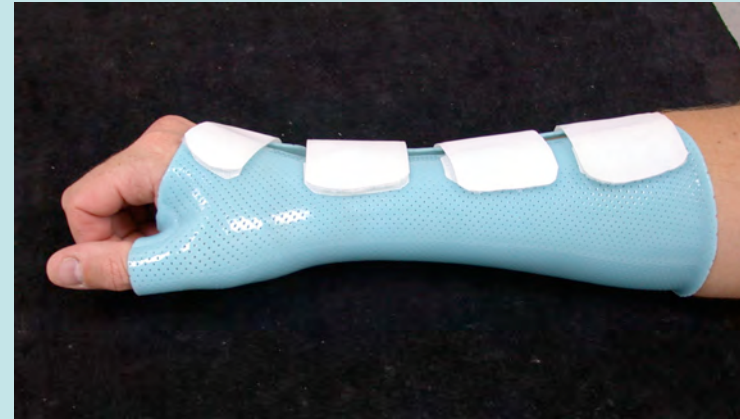Fixation

- 2 K-wires 10/100
- From ST joint
- Anterior stut

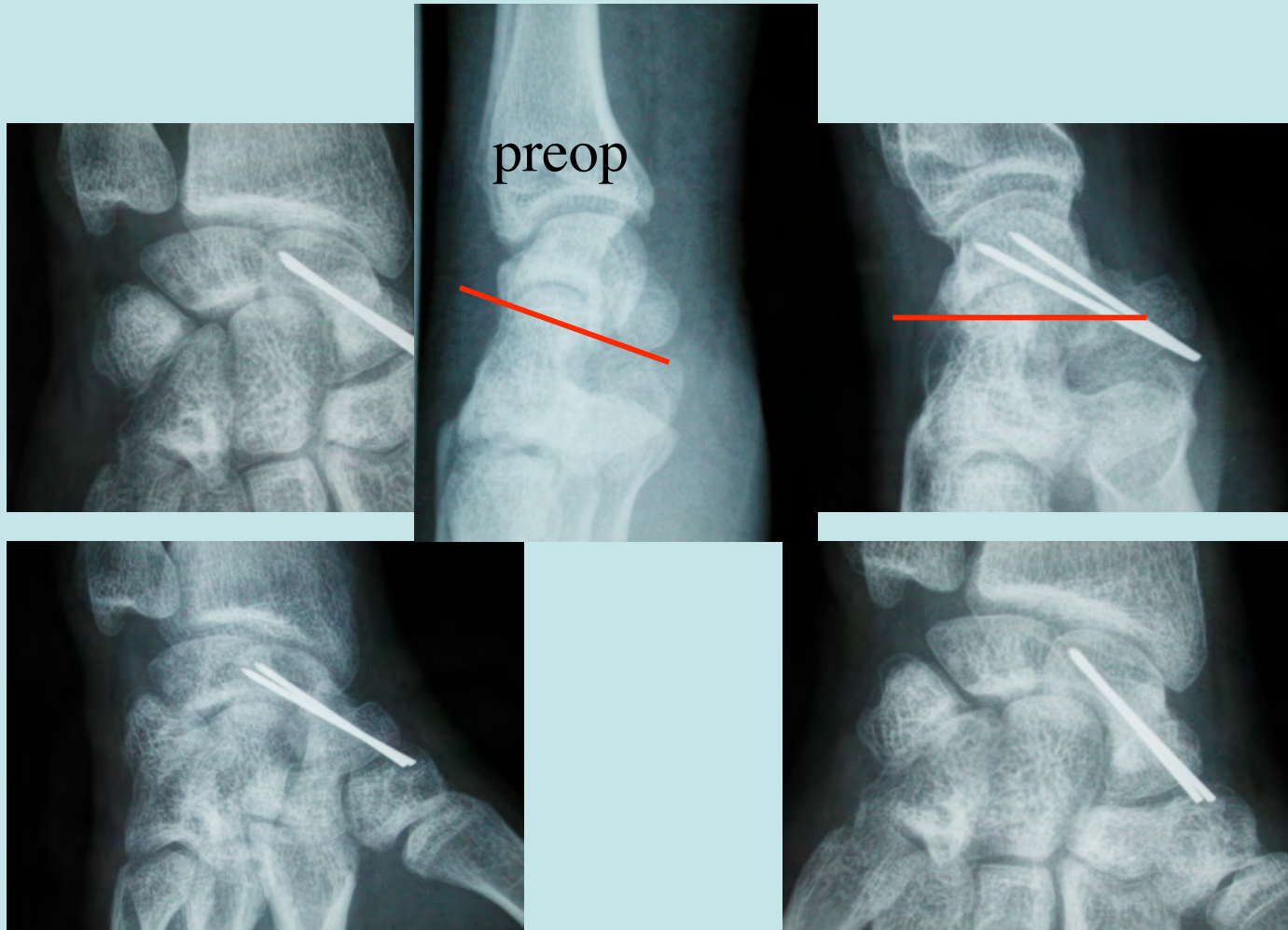

Postoperative care

- Anterior splint 12 weeks
 - Continuously 8 weeks
- X ray control
 - at 6 weeks and 12 weeks
- K-wires removal from 12 weeks

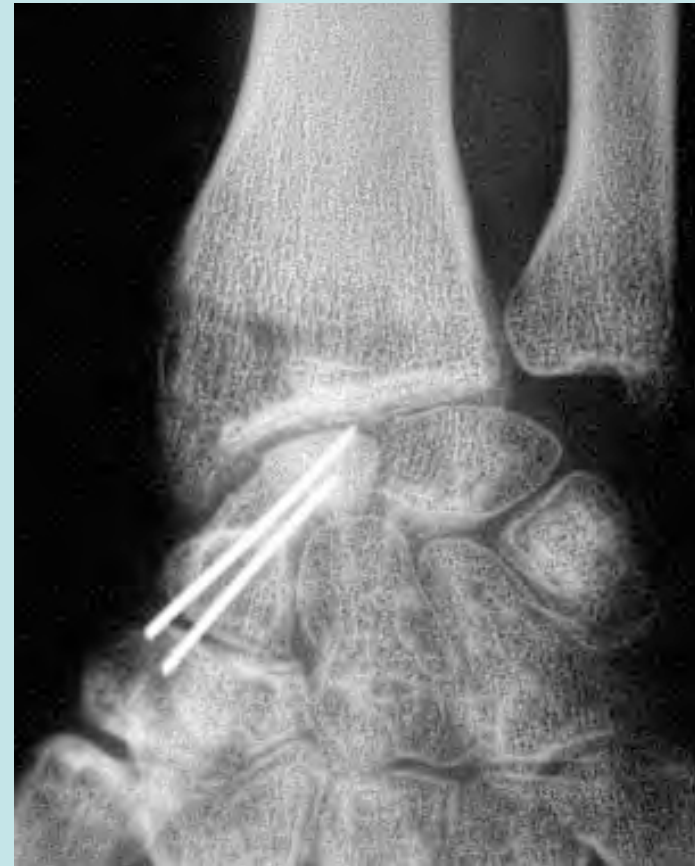

At 12 weeks



Surgical options

- Partial styloidectomy
 - Old nonunion without cartilage damage
- Cancellous graft from radius
 - Nonunion without large bone defect



Scaphoid non union without arthritis

Proximal pole (I,II)

Waist (III, IV, V)

Dorsal

Palmar

AV

Non AV

AV or failure

Non AV

I

II

Cancel.graft
+ 2 screws

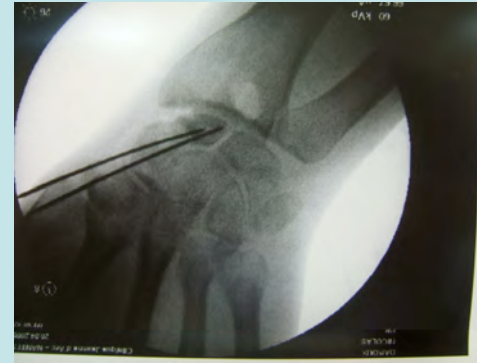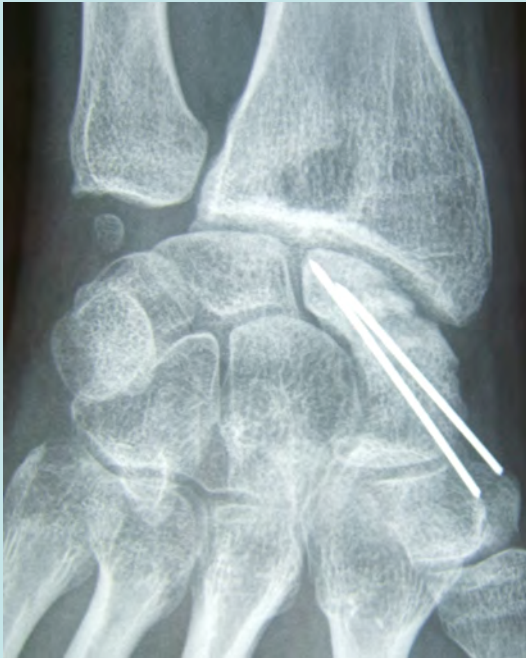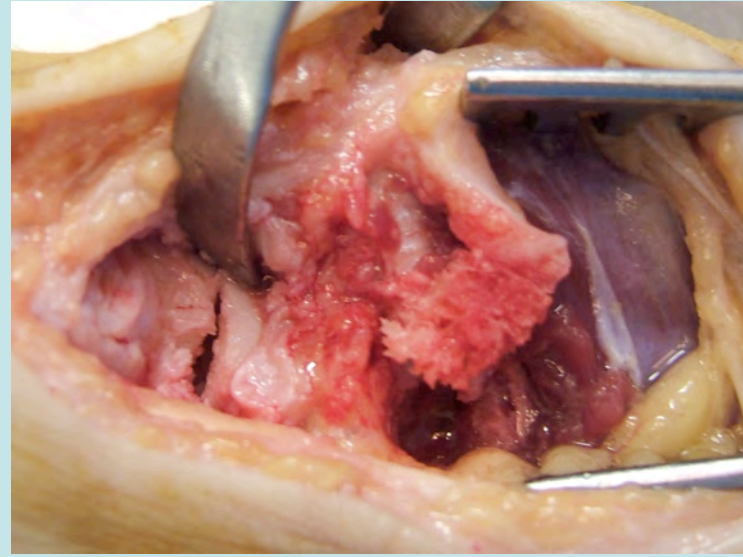
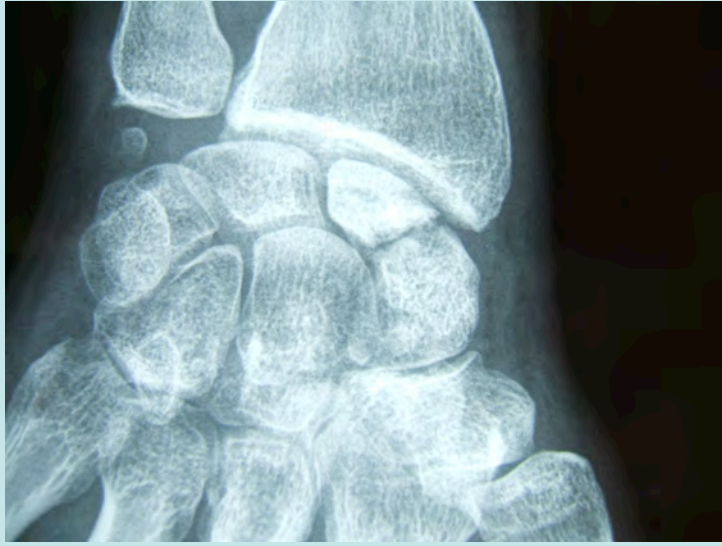Vasc.graft
+ wires

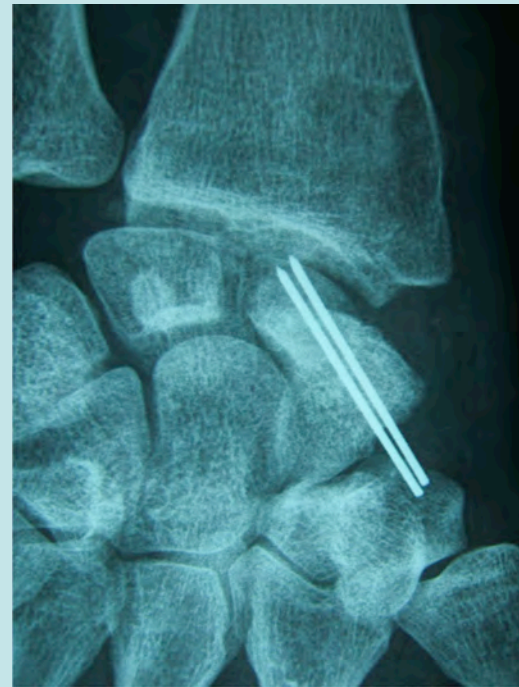
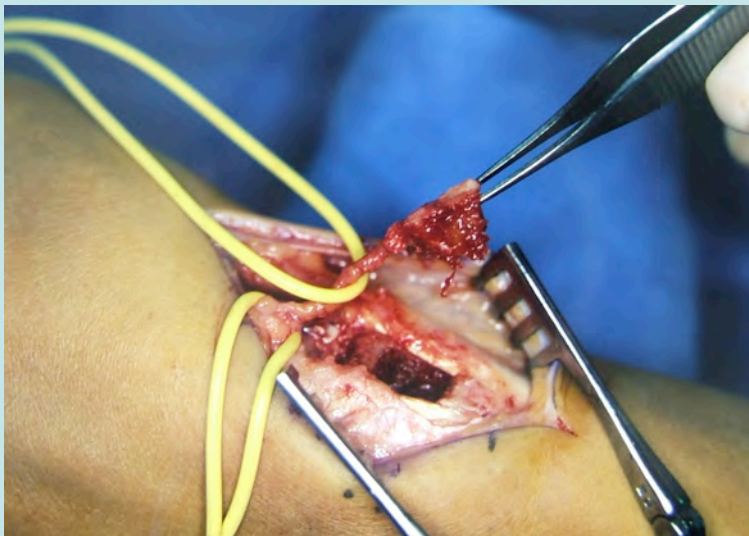
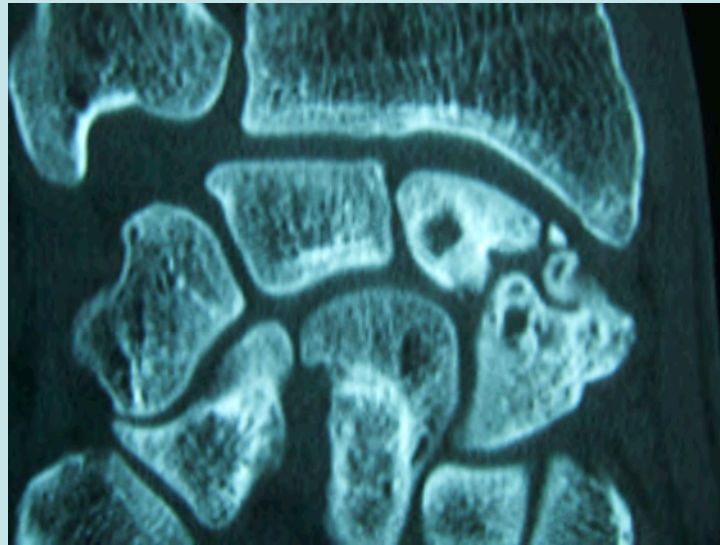
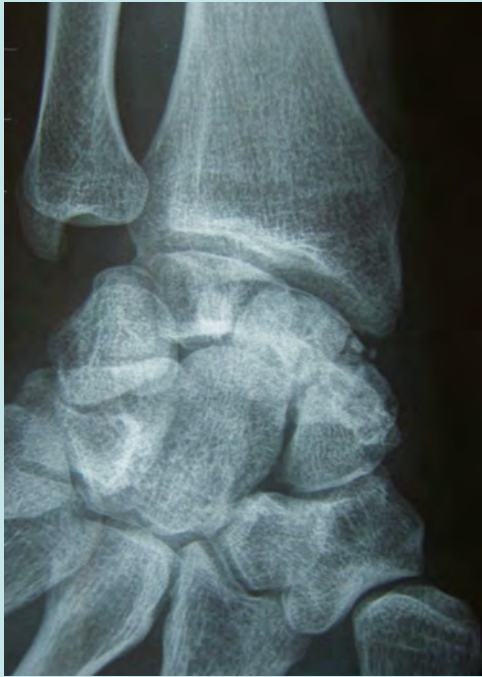Cancel.graft
+ wires

Vasc.graft
+ wires

remove

APSI





Scaphoid non union without arthritis

Proximal pole (I, II)

Waist (III, IV, V)

Dorsal

Palmar

AV

Non AV

AV or failure

Non AV

I

II

Cancel.graft
+ 2 screws

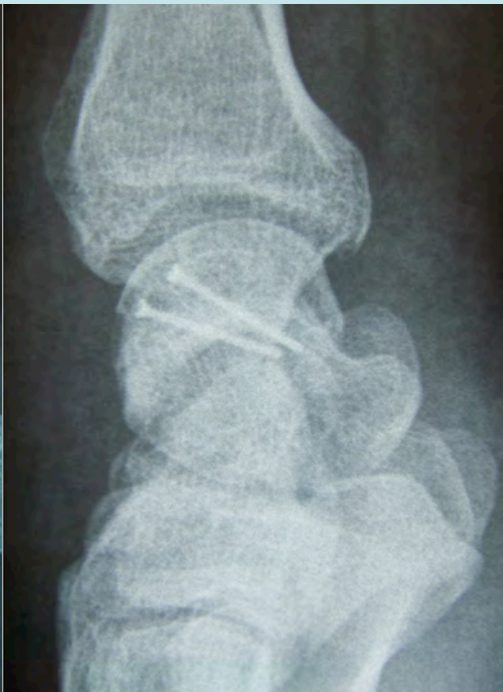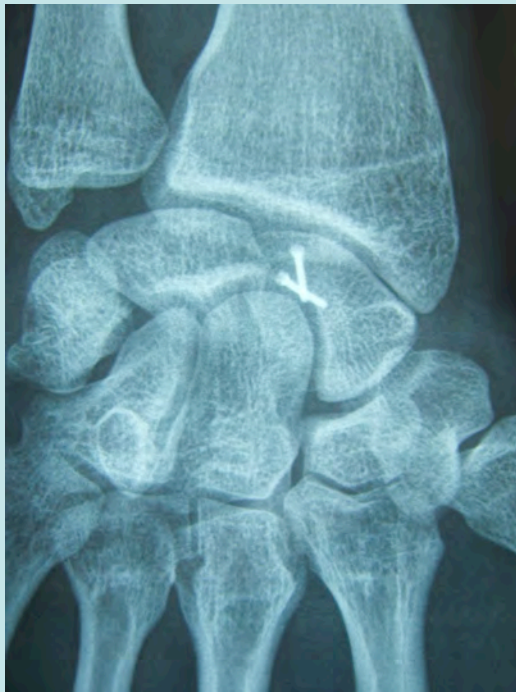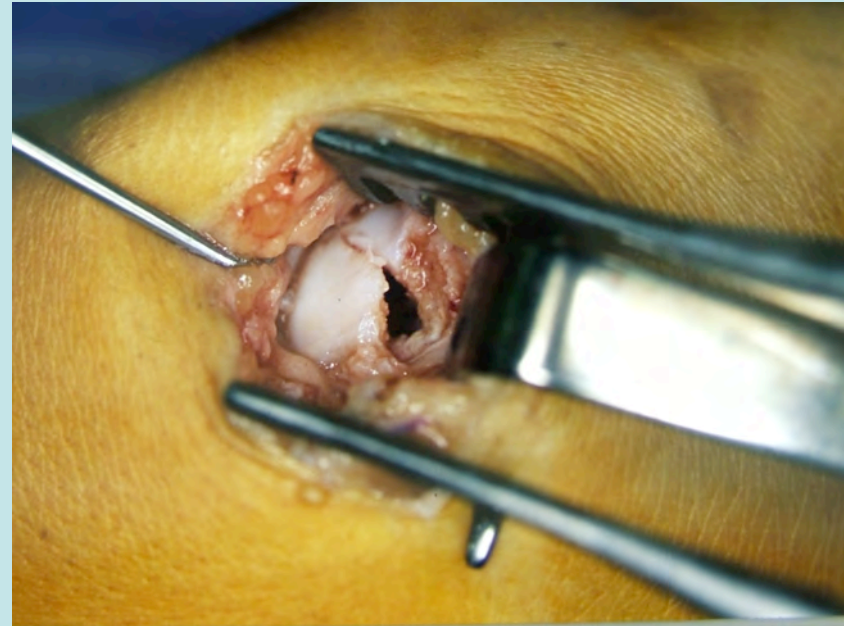
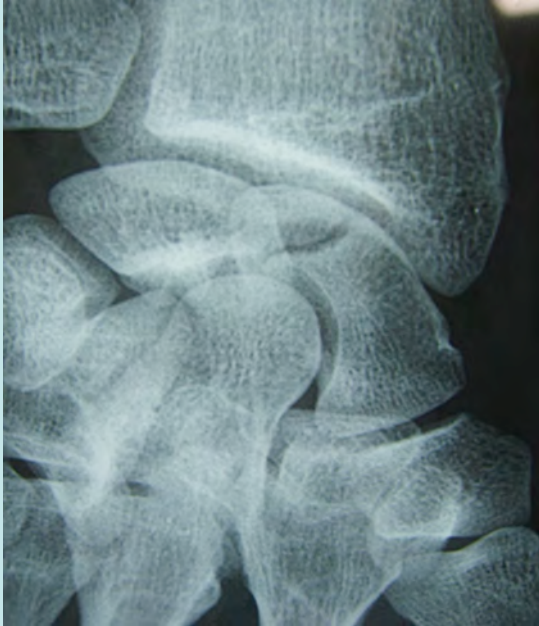
Vasc.graft
+ wires

Cancel.graft
+ wires

Vasc.graft
+ wires

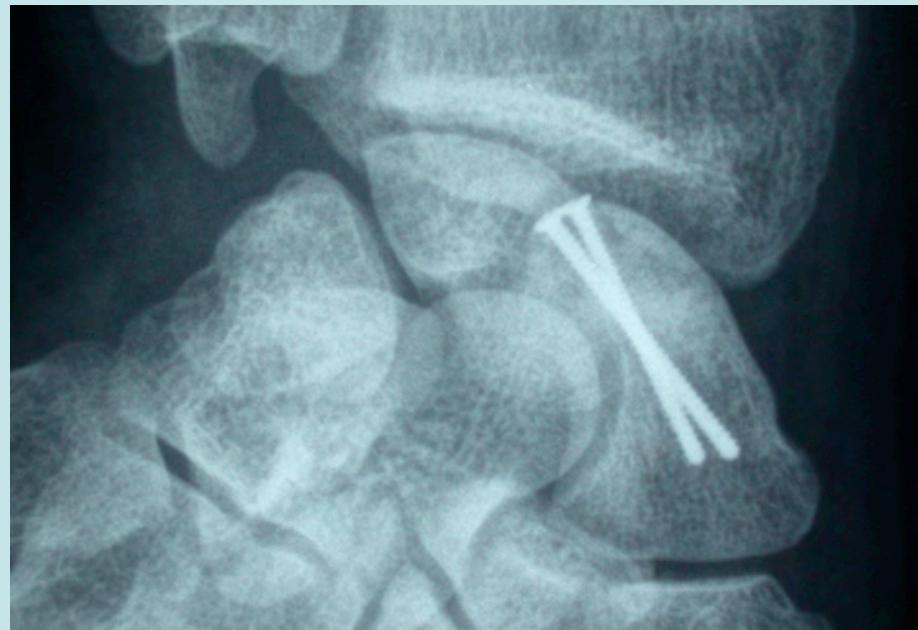
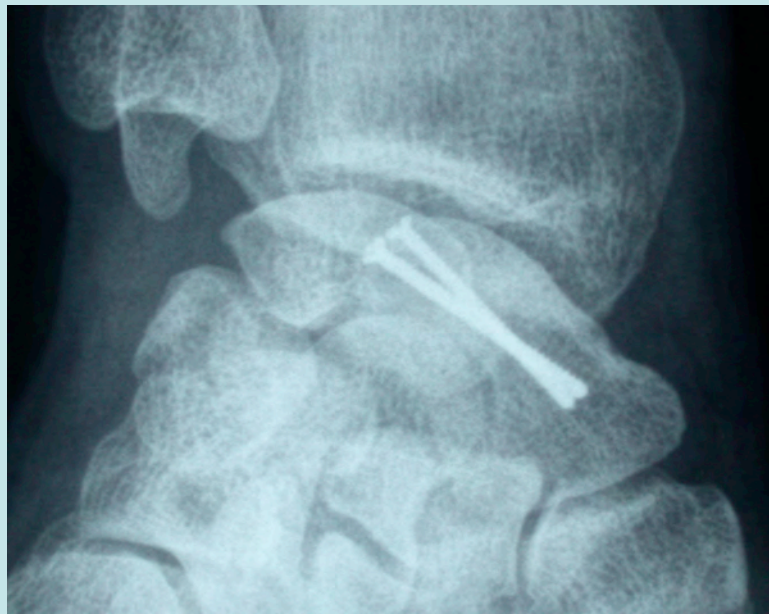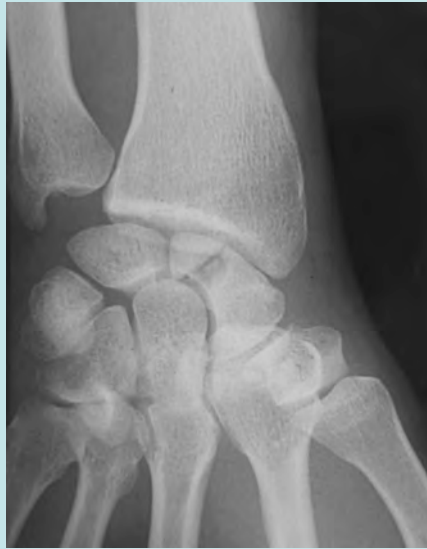remove

APSI



Zone 1

2 wires dia 1.2



Zone II 2 wires dia. 1,7

Scaphoid non union without arthritis

Proximal pole (I, II)

Waist (III, IV, V)

Dorsal

Palmar

AV

Non AV

AV or failure

Non AV

I

II

Cancel.graft
+ 2 screws

Vasc.graft
+ wires

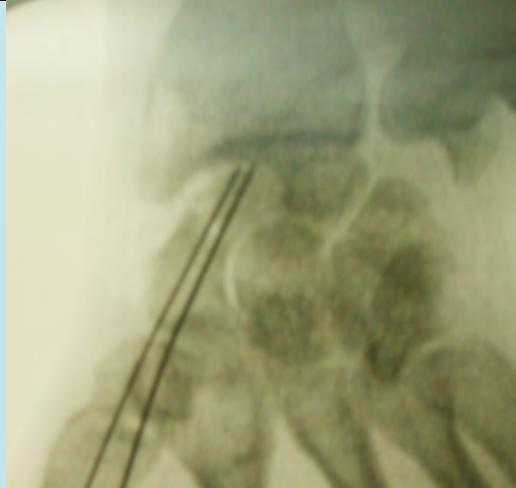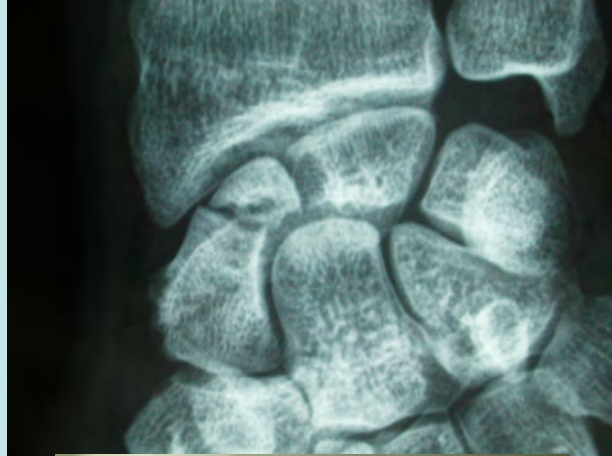
Cancel.graft
+ wires

Vasc.graft
+ wires

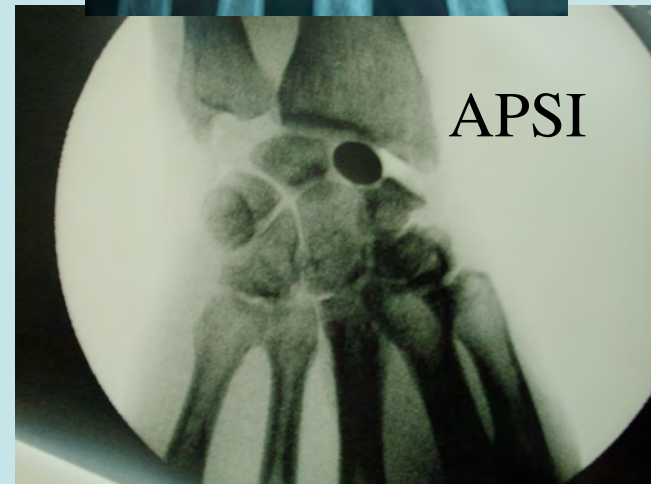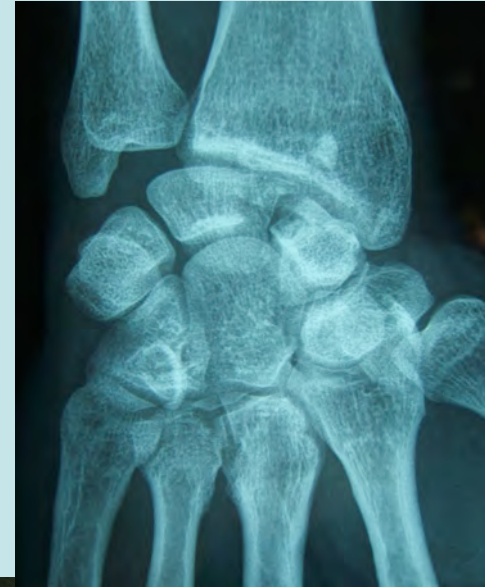remove

APSI

AV zone II



AV zone I
Necrosis zone II



Simple removal possible in zone I

Scaphoid non union without arthritis

Proximal pole (I, II)

Waist (III, IV, V)

Dorsal

Palmar

AV

Non AV

AV or failure

Non AV

I

II

Cancel.graft
+ 2 screws

Vasc.graft
+ wires

Cancel.graft
+ wires

Vasc.graft
+ wires

remove

APSI