Lésions sterno-claviculaires

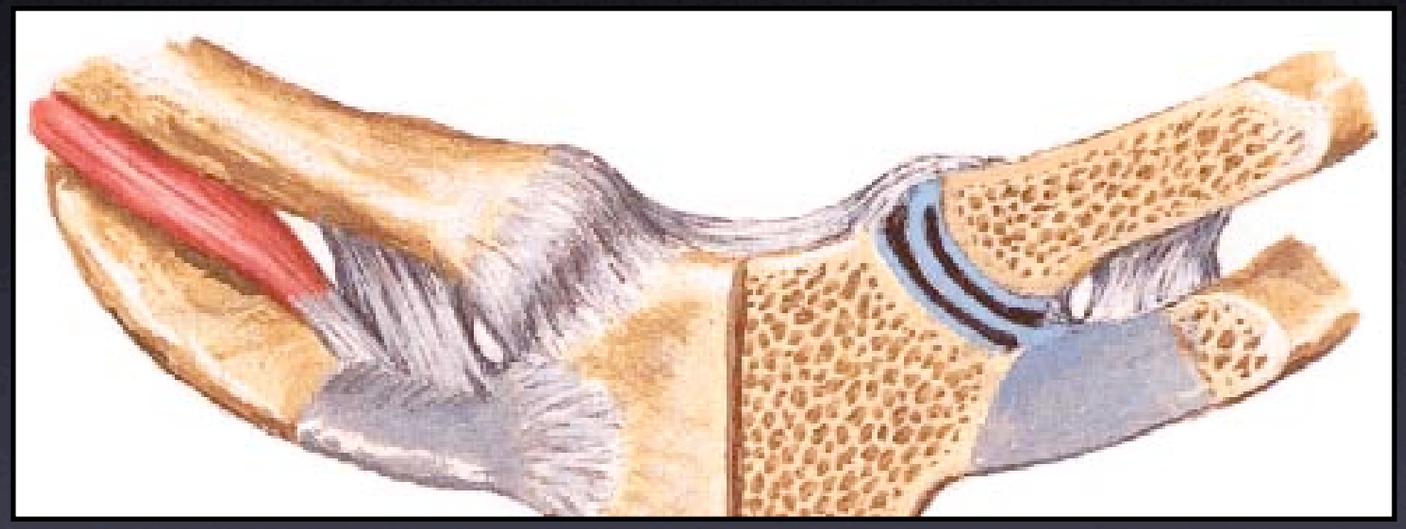

Christian Dumontier
hôpital Saint Antoine & Institut de la Main,
Paris

Luxations sterno-claviculaires

- Rares (1/4 des luxations acromio-claviculaires, 3% des traumatismes de l'épaule)
- Luxations antérieures > postérieures (ratio de 1/4 à 1/20)

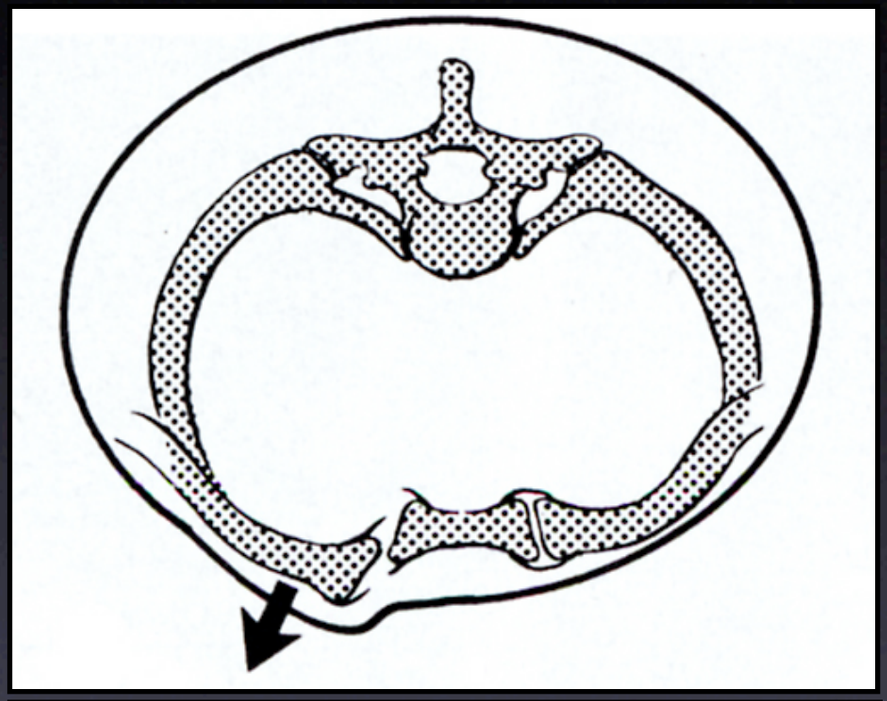

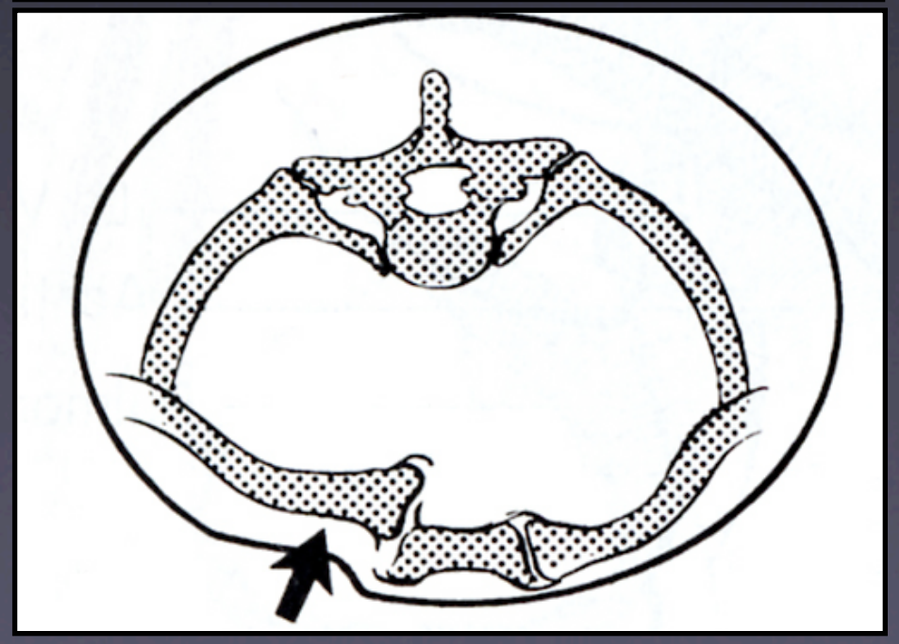

Luxations sterno-claviculaires

- Traumatisme indirect sur le moignon de l'épaule

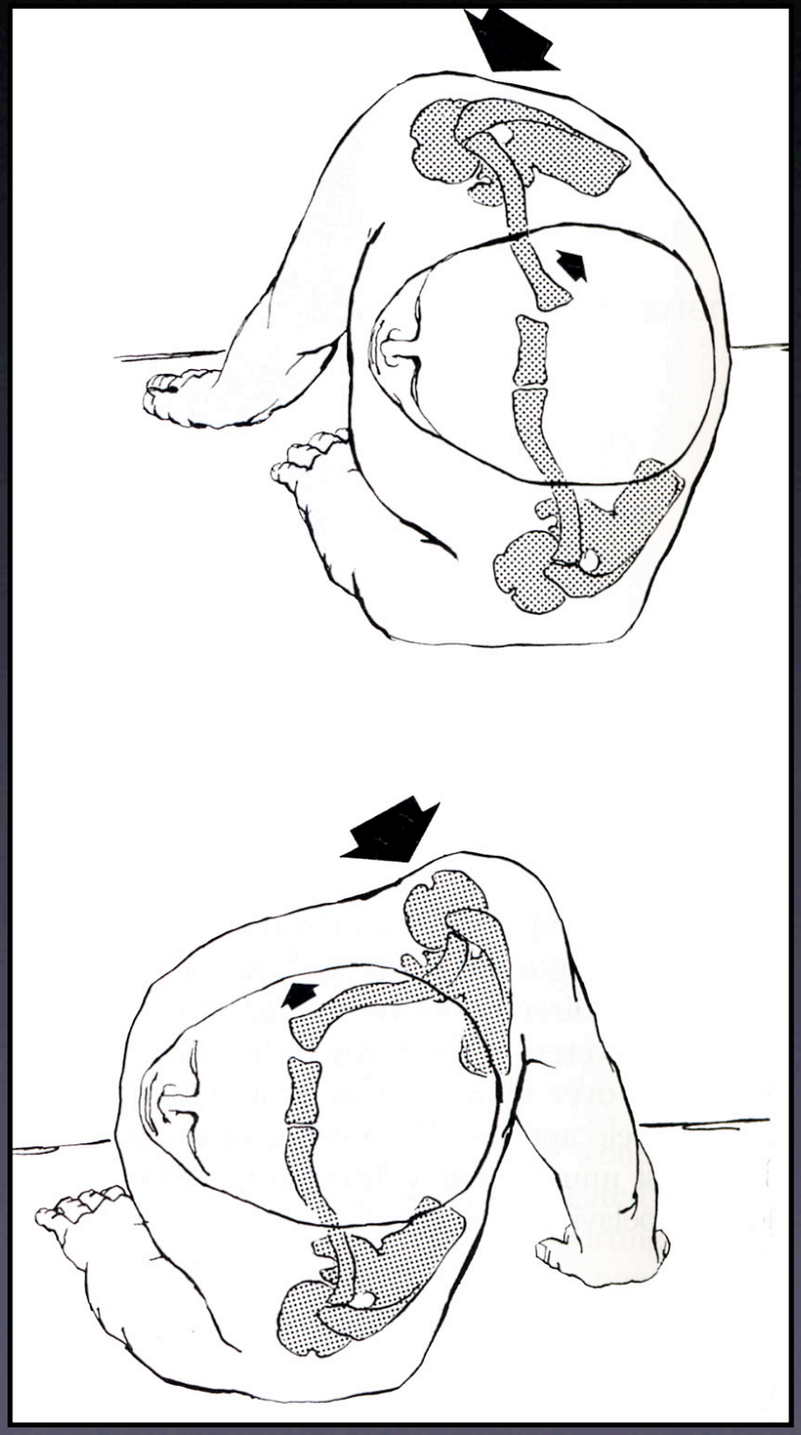

Rappel anatomique

- Di-arthrodie
- Seule articulation entre le tronc et le membre supérieur !
- Articulation non congruente
  - Clavicule est plus grosse que le sternum
  - Concave d’avant en arrière
  - Convexe de haut en bas

AURORA
SAULT
L<->R : 115.8
A<->P : 9.8
S<->I : 0.7
Zoom : 3.87

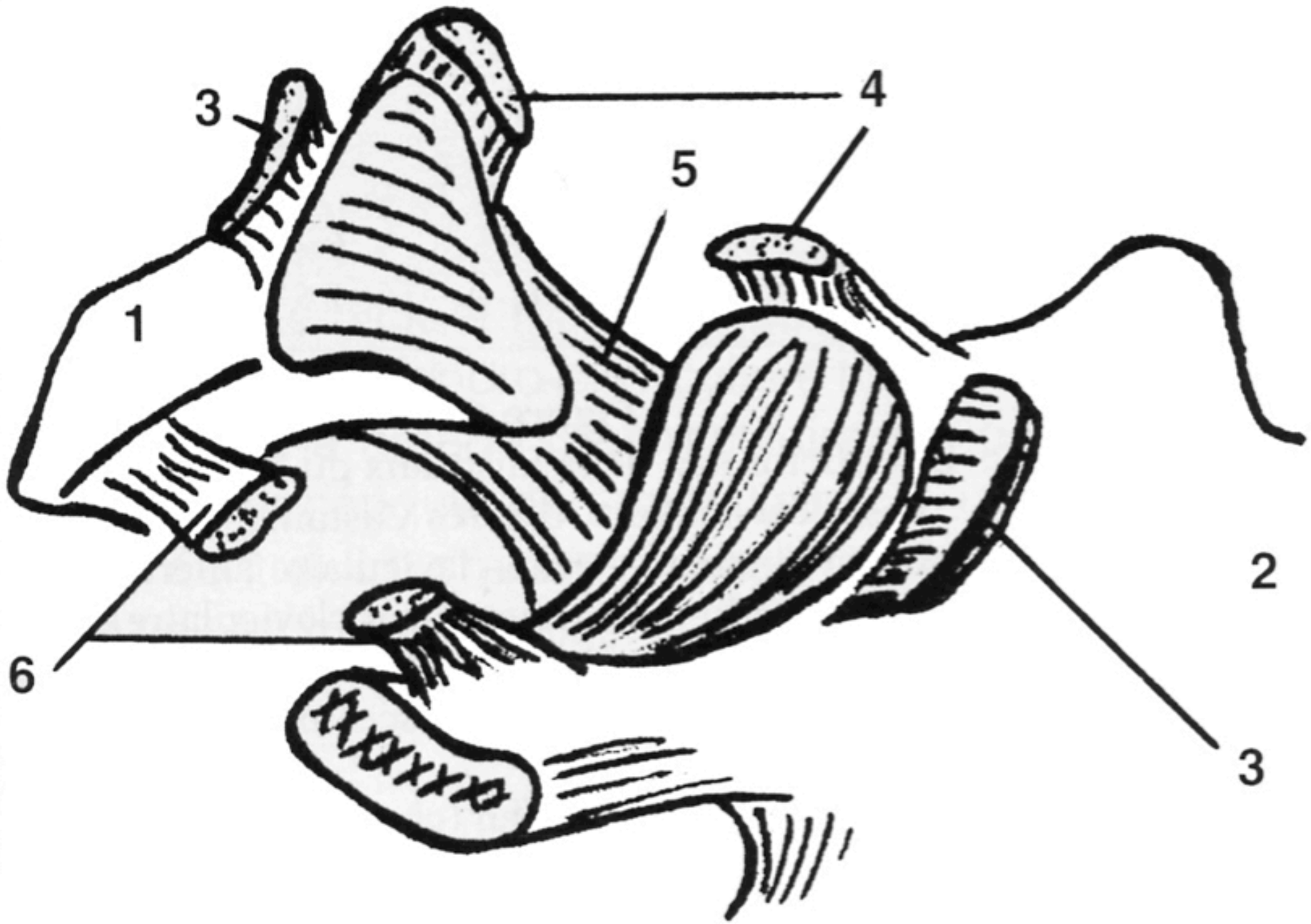

Figure 4 :
Vue antérieure de l'articulation sterno-chondro-claviculaire ouverte :

1 - clavicule,
2 - sternum,
3 - ligament sterno-claviculaire antérieur,
4 - ligament sterno-claviculaire supérieur,
5 - ligament sterno-claviculaire postérieur,
6 - ligament costo-claviculaire.

Rappel anatomique

- <u>Stabilité ligamentaire</u>
  - Ménisque intra-articulaire
  - Ligament costo-claviculaire
  - Ligament inter-claviculaire
  - Capsule

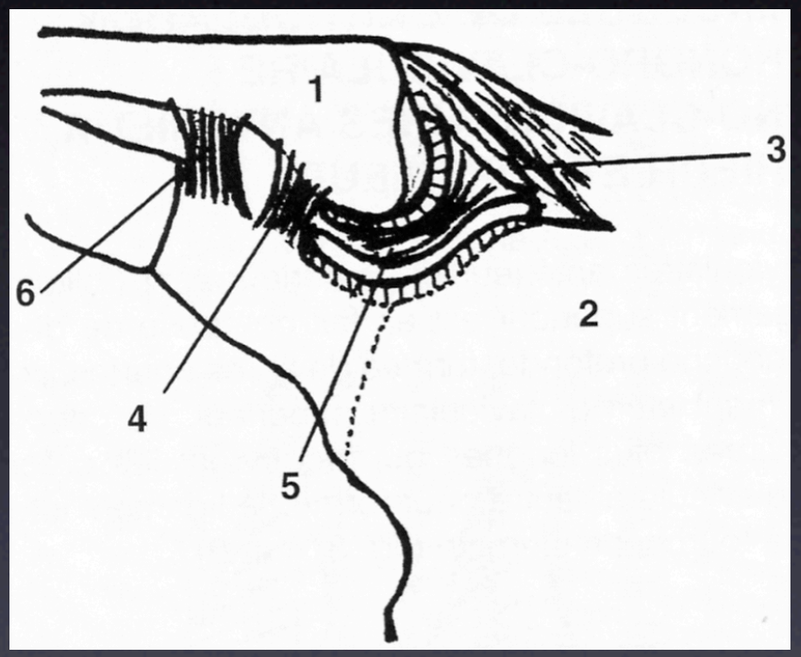

Figure 3 :
L'appareillage ligamentaire intrinsèque et extrinsèque de l'articulation sterno-chondro-claviculaire (vue antérieure) :

1 - clavicule,
2 - sternum,
3 - ligament inter-claviculaire,
4 - ligament sterno-claviculaire antérieur,
5 - ligament costo-claviculaire,
6 - premier cartilage costal.

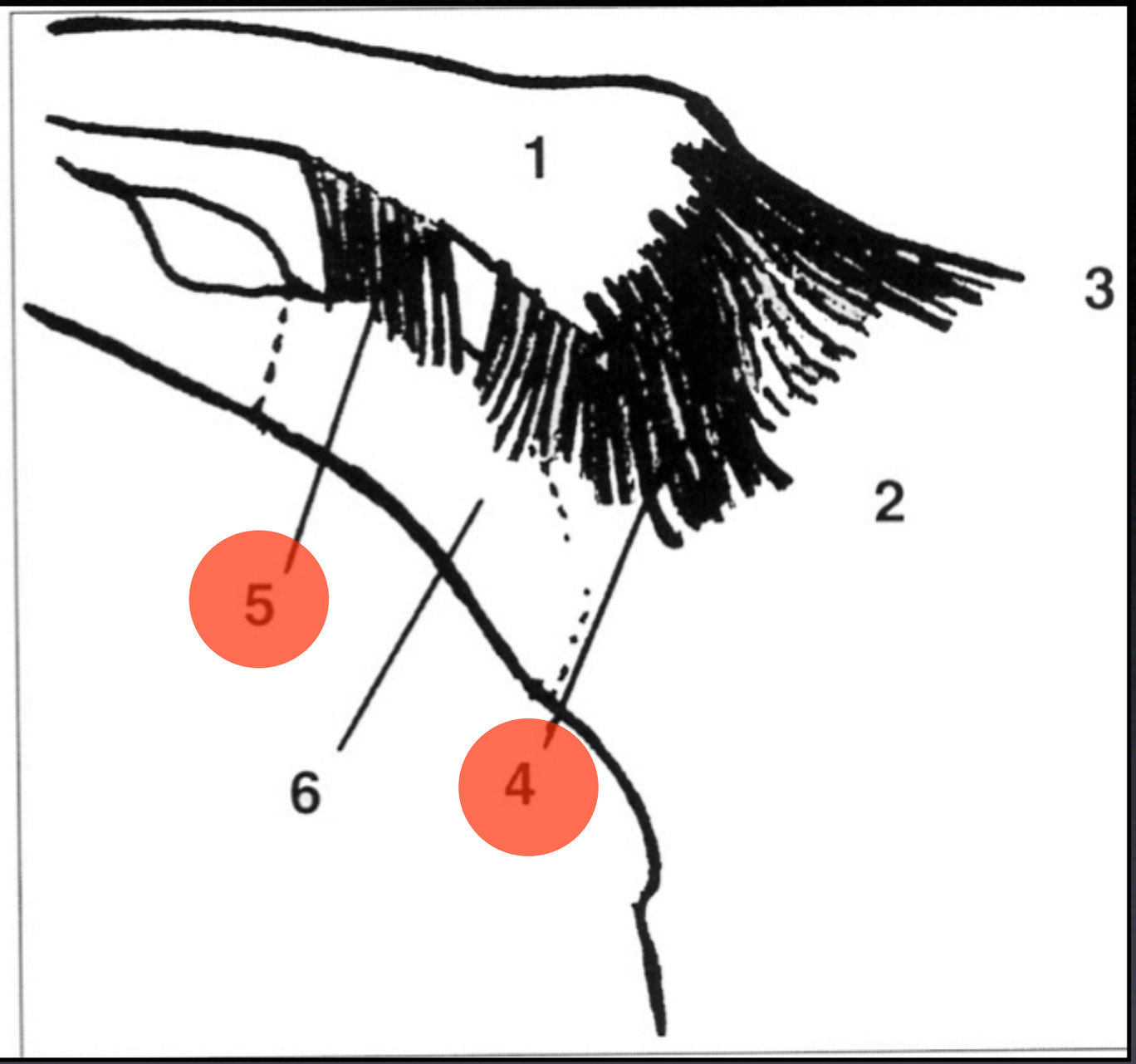

Le ligament costo-claviculaire a 1,3 cm d'épaisseur et de largeur, 1,9 cm de hauteur

Biomécanique de la sternoclaviculaire

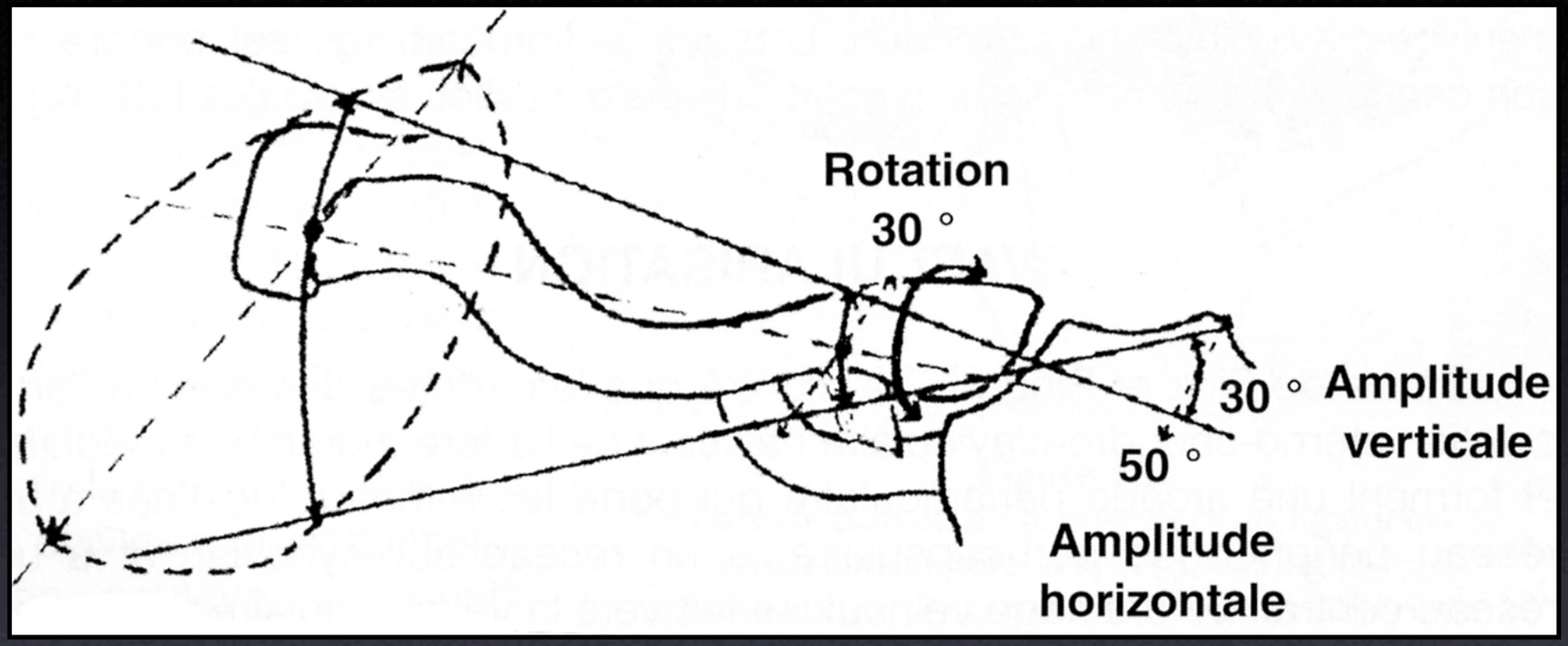

- 35° d'élévation (environ 1/6 de la mobilité de l'épaule en élévation)
- 35° de mobilité antéro-postérieure
- 45° de rotation axiale

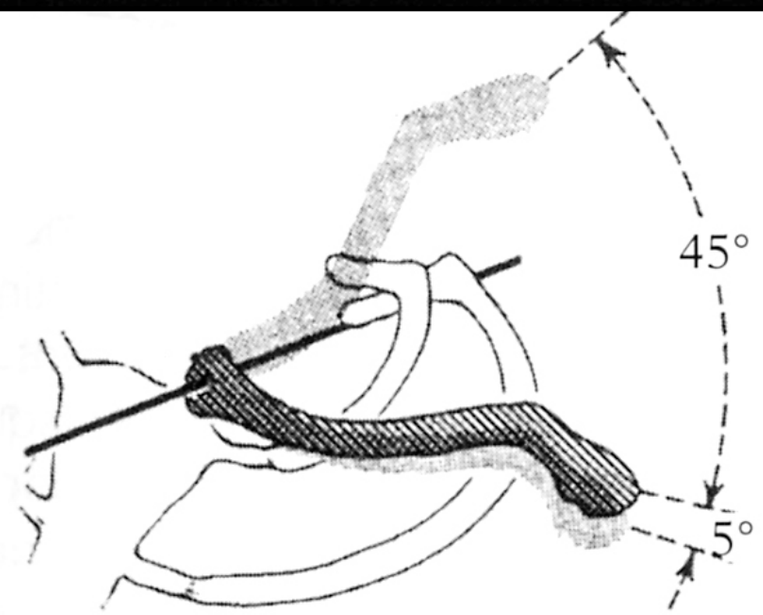

ELEVATION-ABAISSEMENT

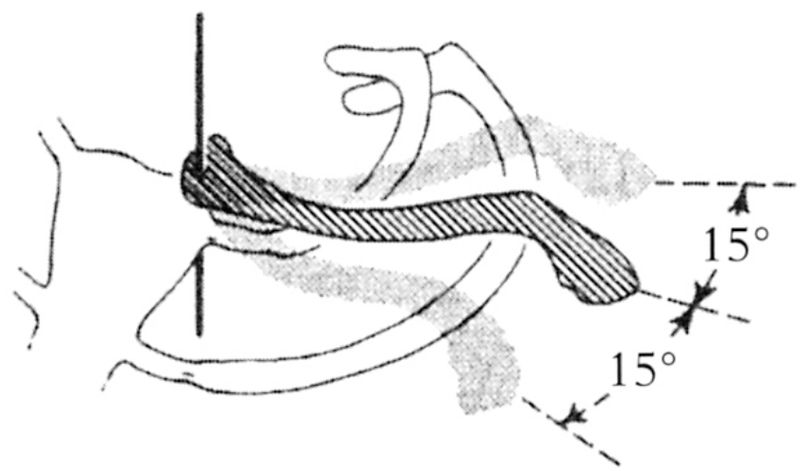

ANTEPULSION-RETROPULSION

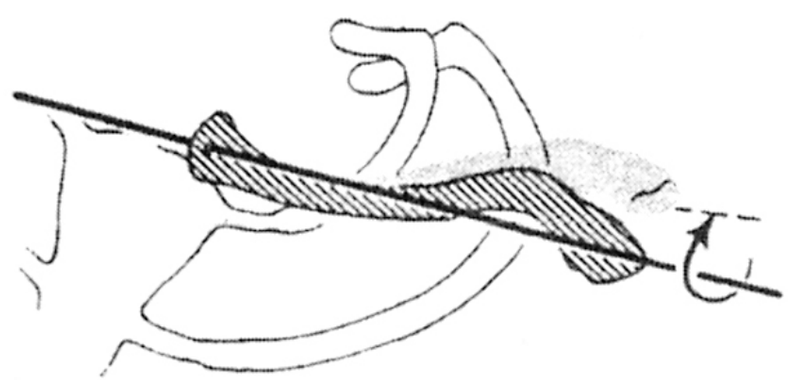

ROTATION AXIALE

Rapports anatomiques compliqués

Rapports anatomiques compliqués

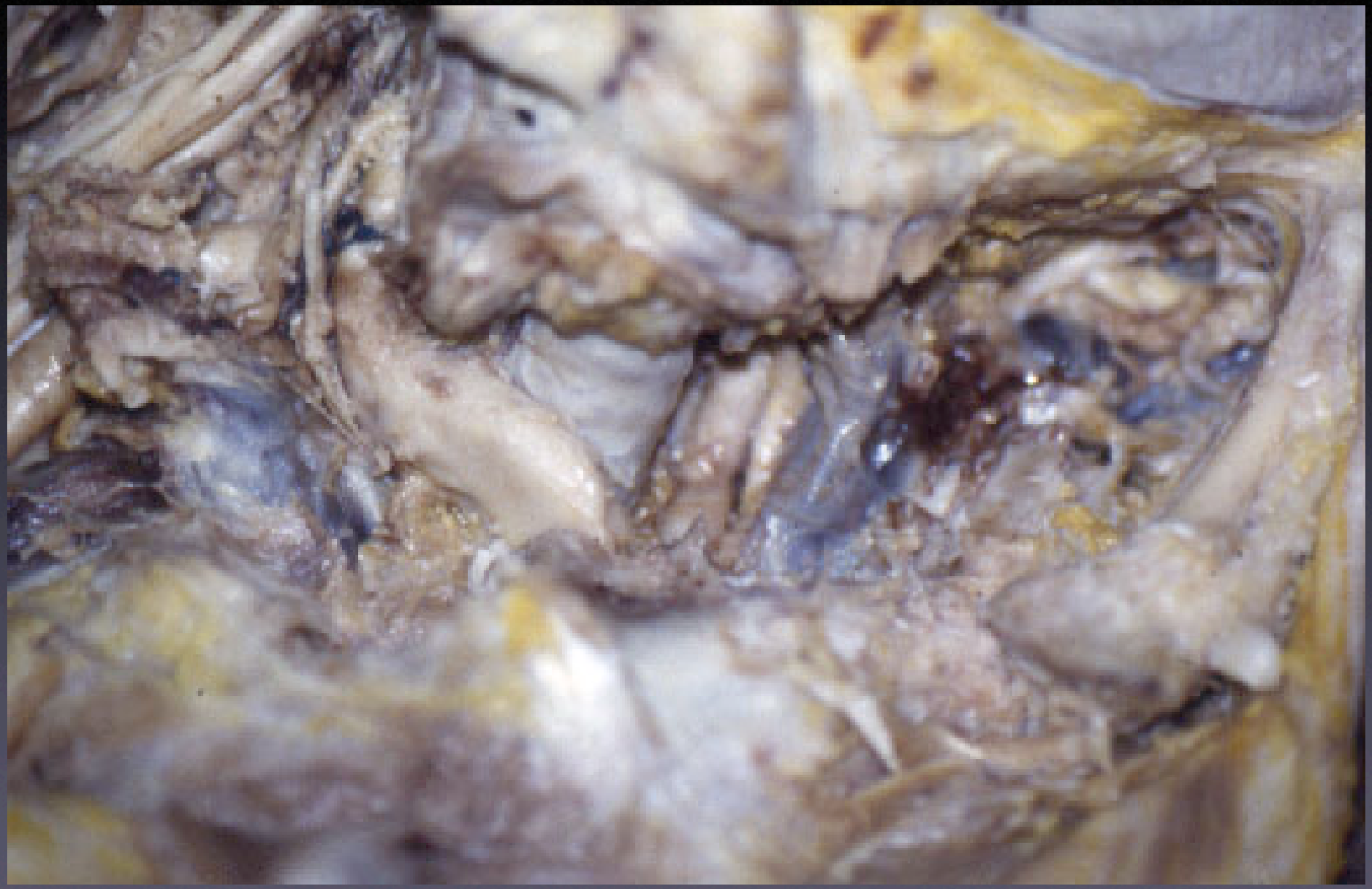

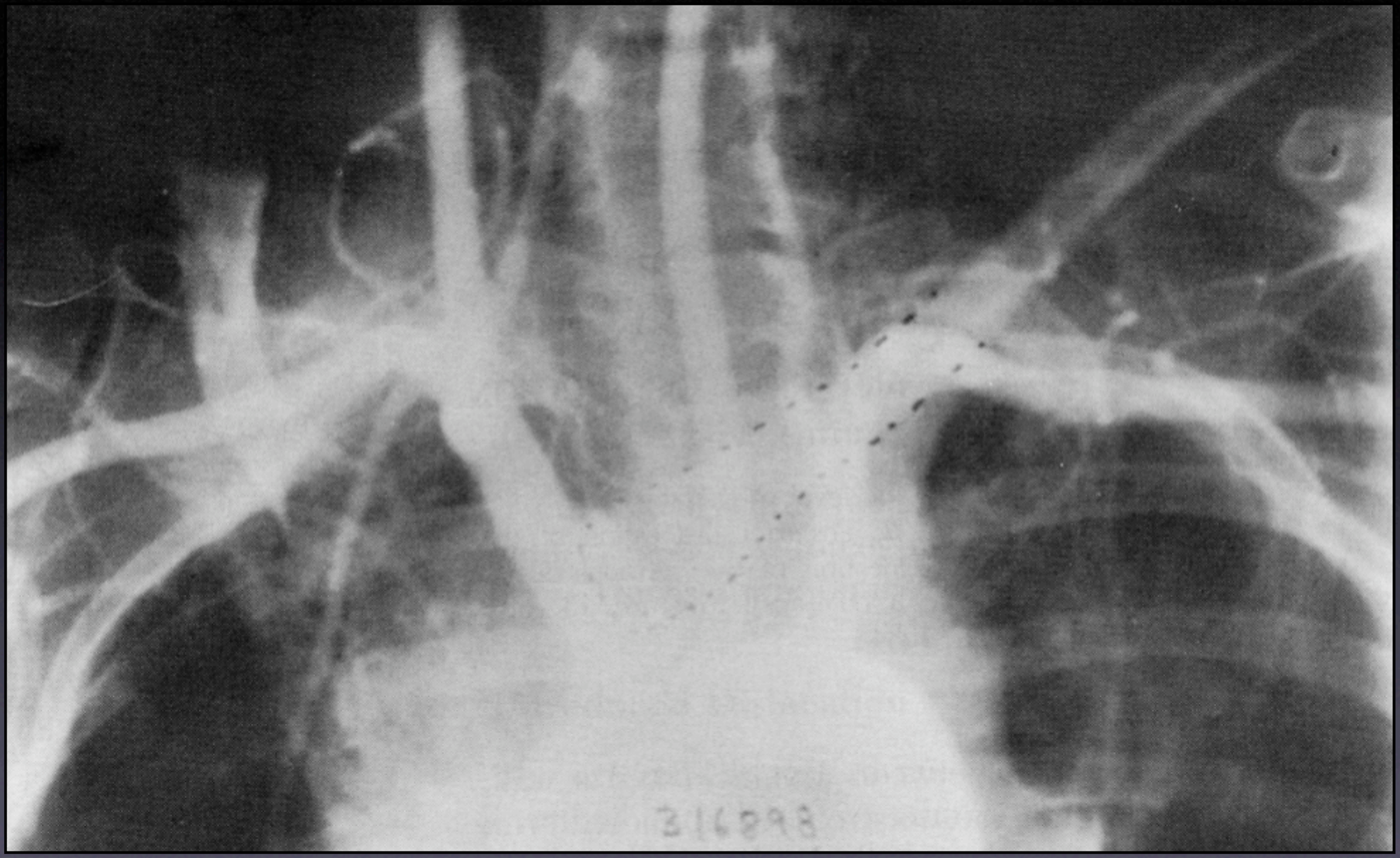
316898

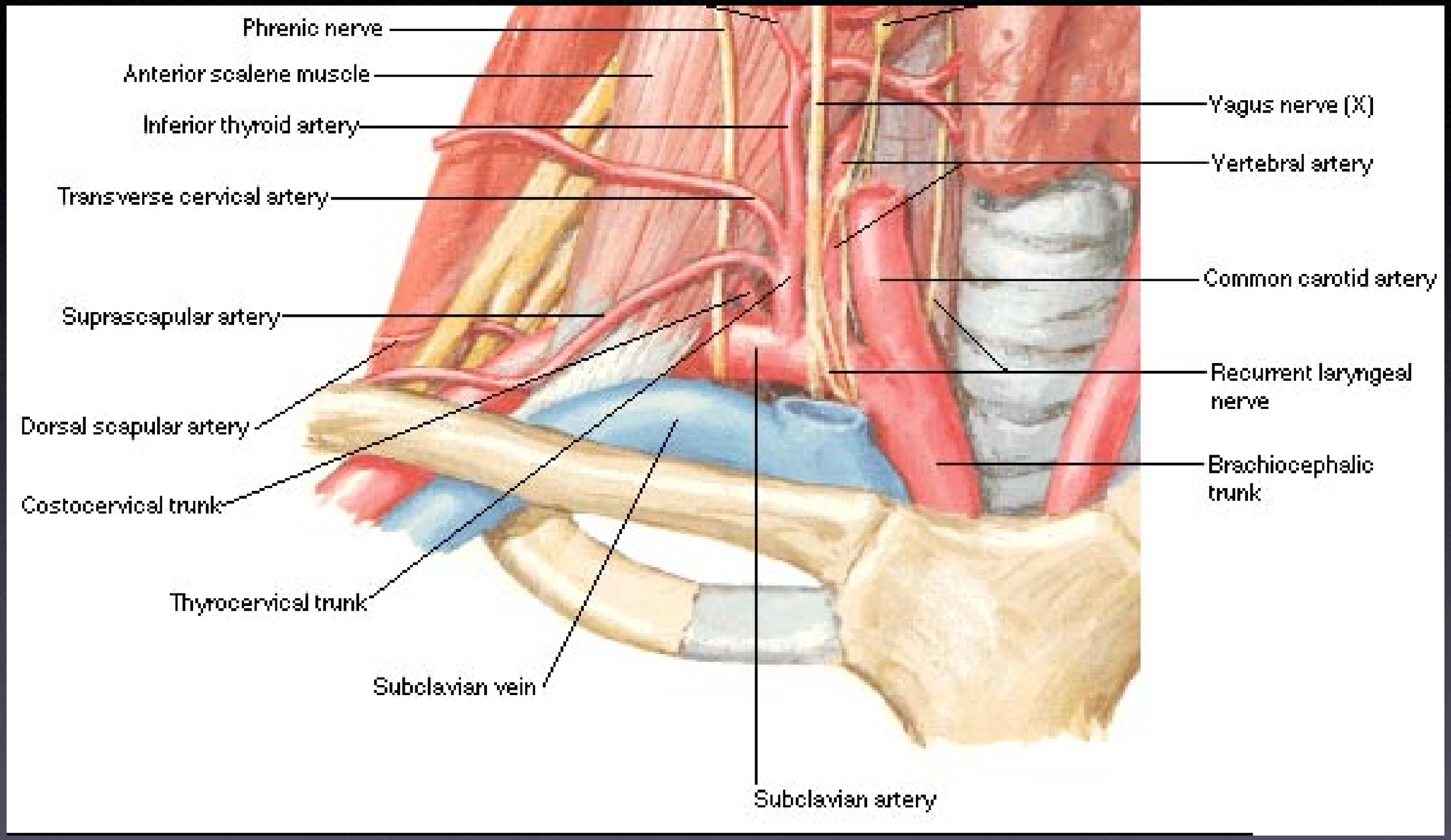
Phrenic nerve
Anterior scalene muscle
Inferior thyroid artery
Transverse cervical artery
Suprascapular artery
Dorsal scapular artery
Costocervical trunk
Thyrocervical trunk
Subclavian vein
Subclavian artery
Vagus nerve (X)
Vertebral artery
Common carotid artery
Recurrent laryngeal nerve
Brachiocephalic trunk

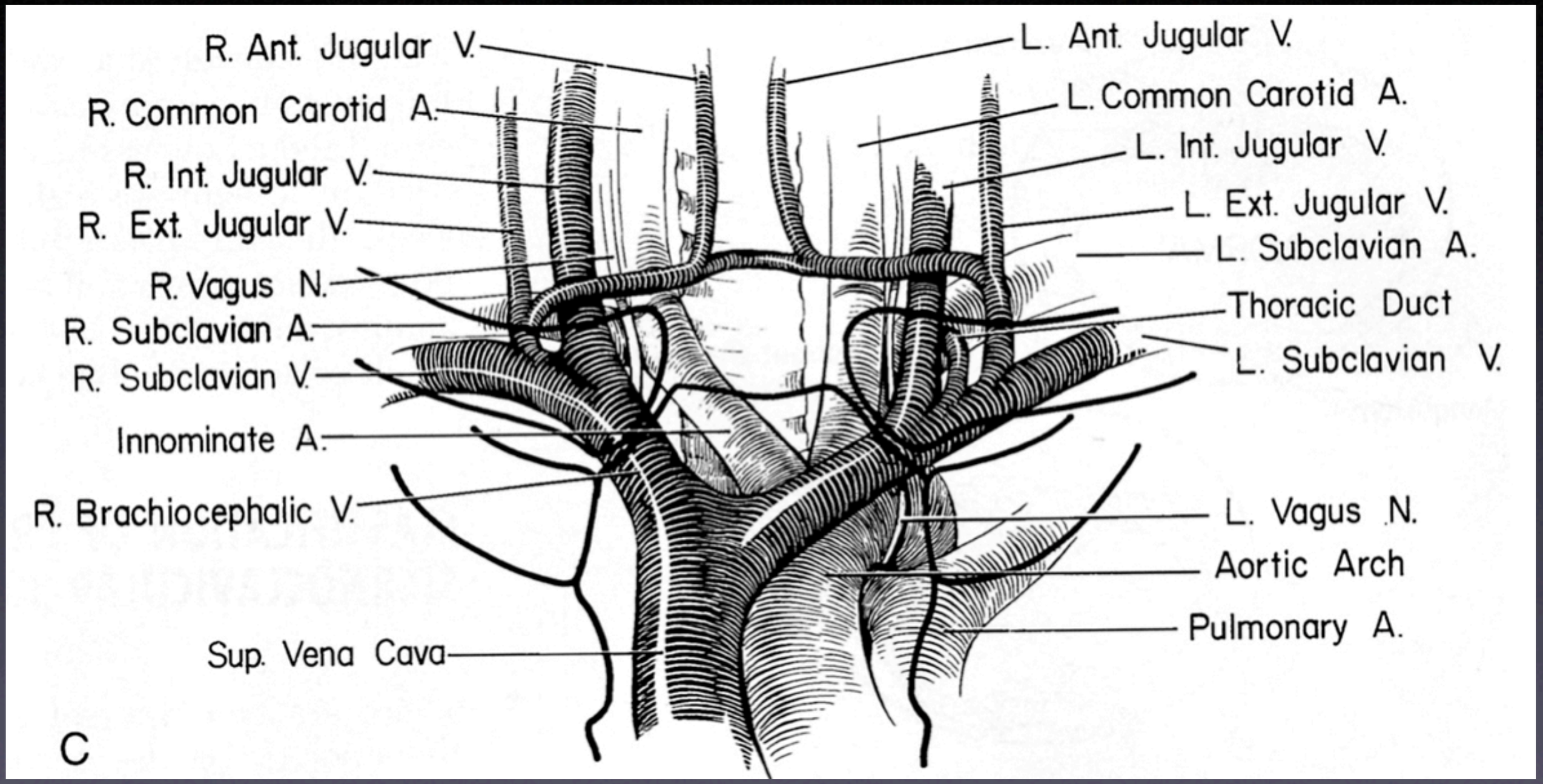
R. Ant. Jugular V.
R. Common Carotid A.
R. Int. Jugular V.
R. Ext. Jugular V.
R. Vagus N.
R. Subclavian A.
R. Subclavian V.
Innominate A.
R. Brachiocephalic V.
Sup. Vena Cava
L. Ant. Jugular V.
L. Common Carotid A.
L. Int. Jugular V.
L. Ext. Jugular V.
L. Subclavian A.
Thoracic Duct
L. Subclavian V.
L. Vagus N.
Aortic Arch
Pulmonary A.
C

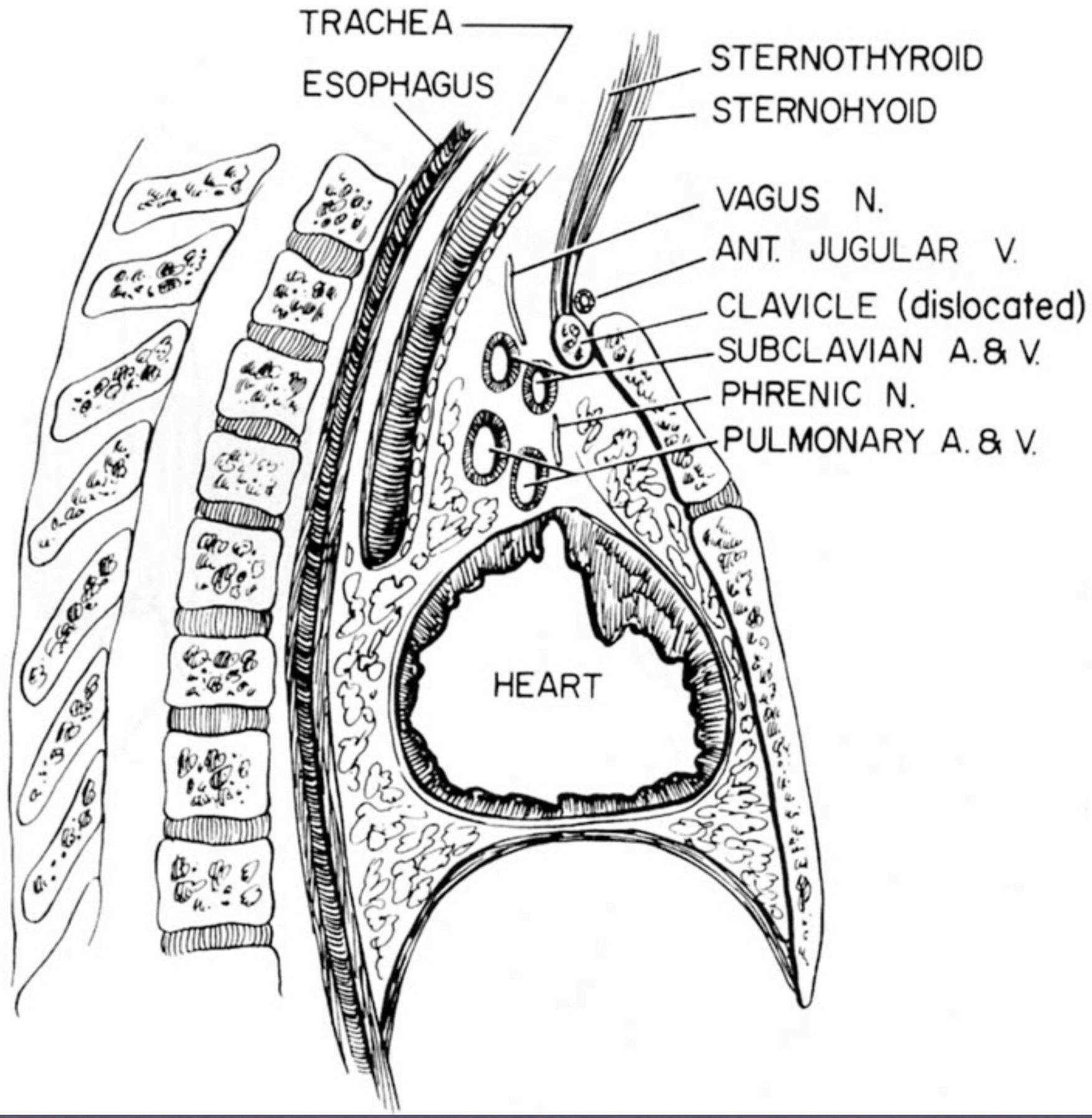
TRACHEA
ESOPHAGUS
STERNOTHYROID
STERNOHYOID
VAGUS N.
ANT. JUGULAR V.
CLAVICLE (dislocated)
SUBCLAVIAN A. & V.
PHRENIC N.
PULMONARY A. & V.
HEART

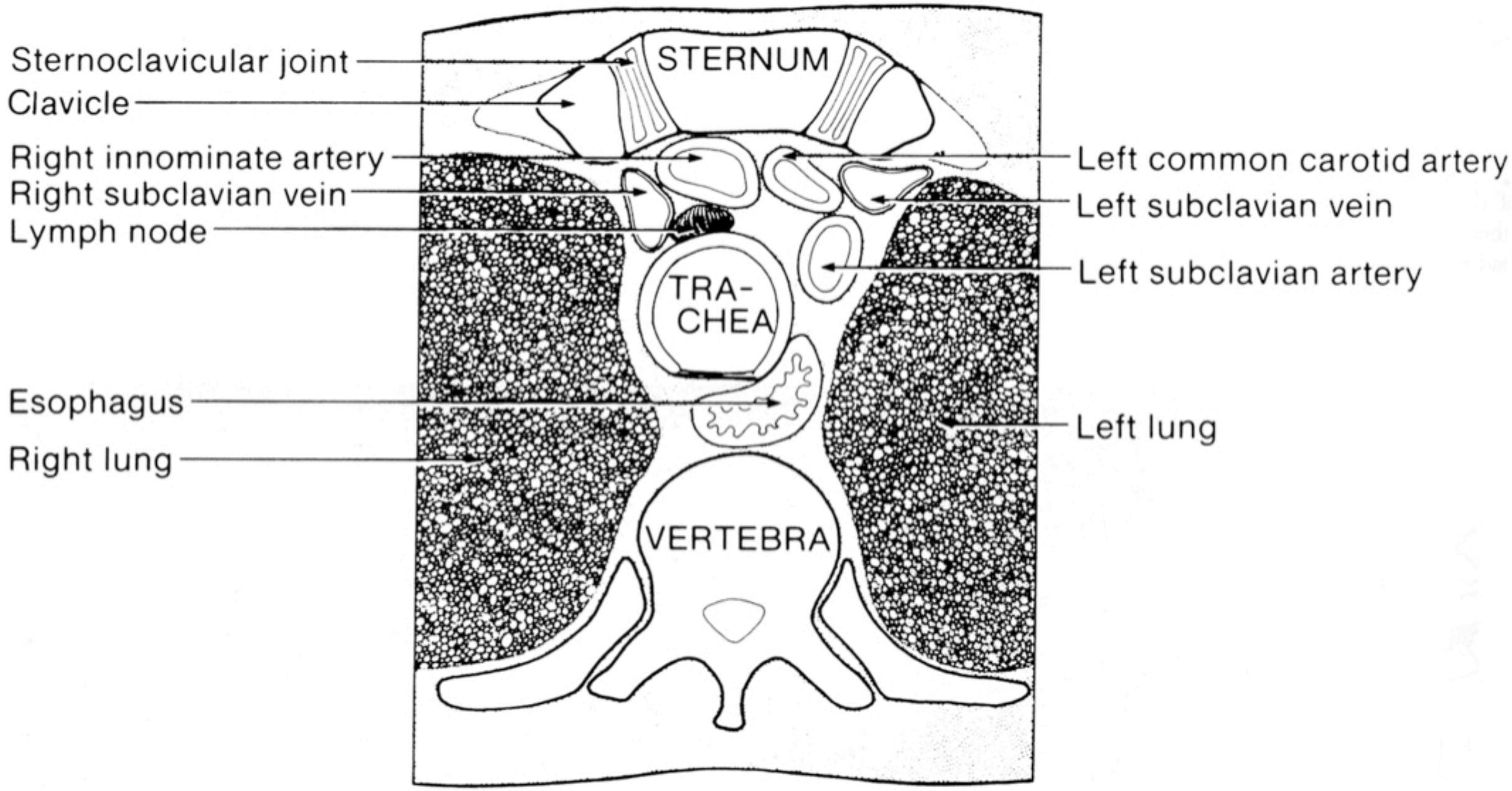
Sternoclavicular joint
Clavicle
Right innominate artery
Right subclavian vein
Lymph node
Esophagus
Right lung
STERNUM
TRA-
CHEA
VERTEBRA
Left common carotid artery
Left subclavian vein
Left subclavian artery
Left lung

Luxations postérieures

- Très rares
- Potentiellement très graves (compression ou lésion de la trachée, des gros vaisseaux,...)
- Stables après réduction (si le patient survit)

Exemple luxation chronique

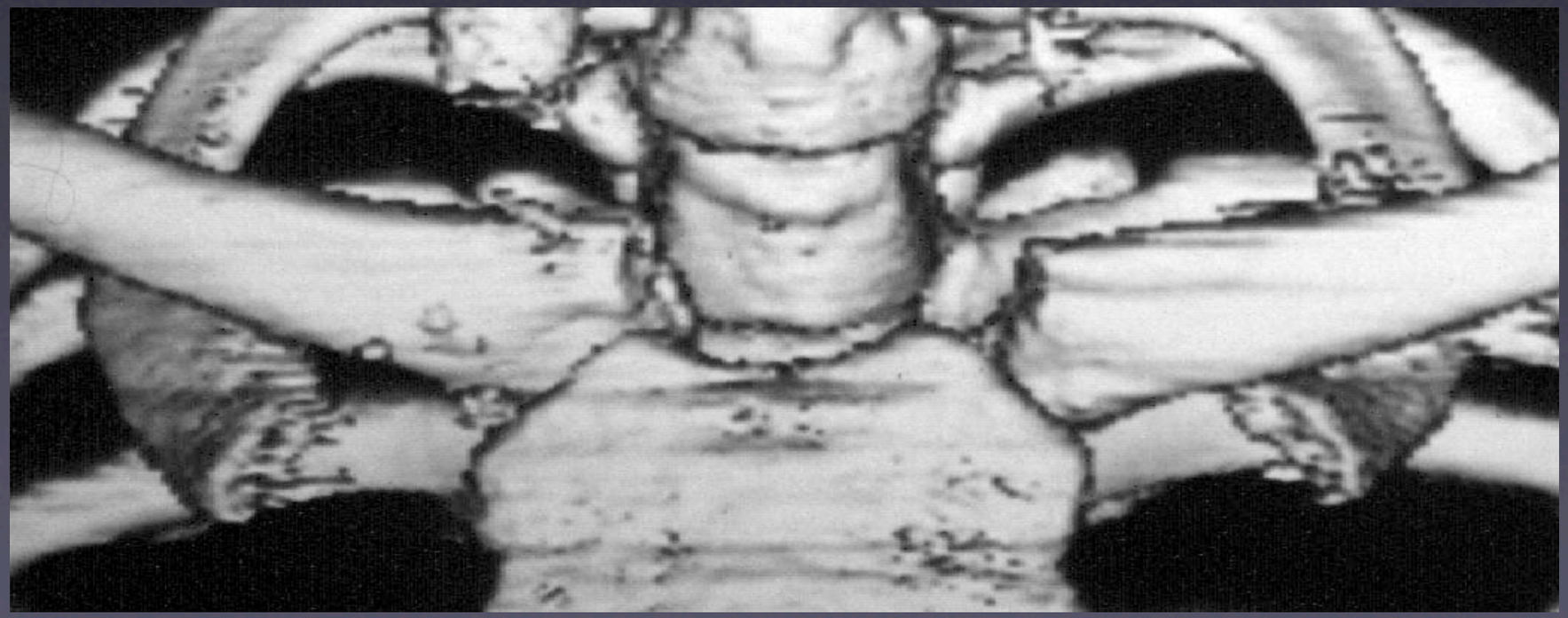

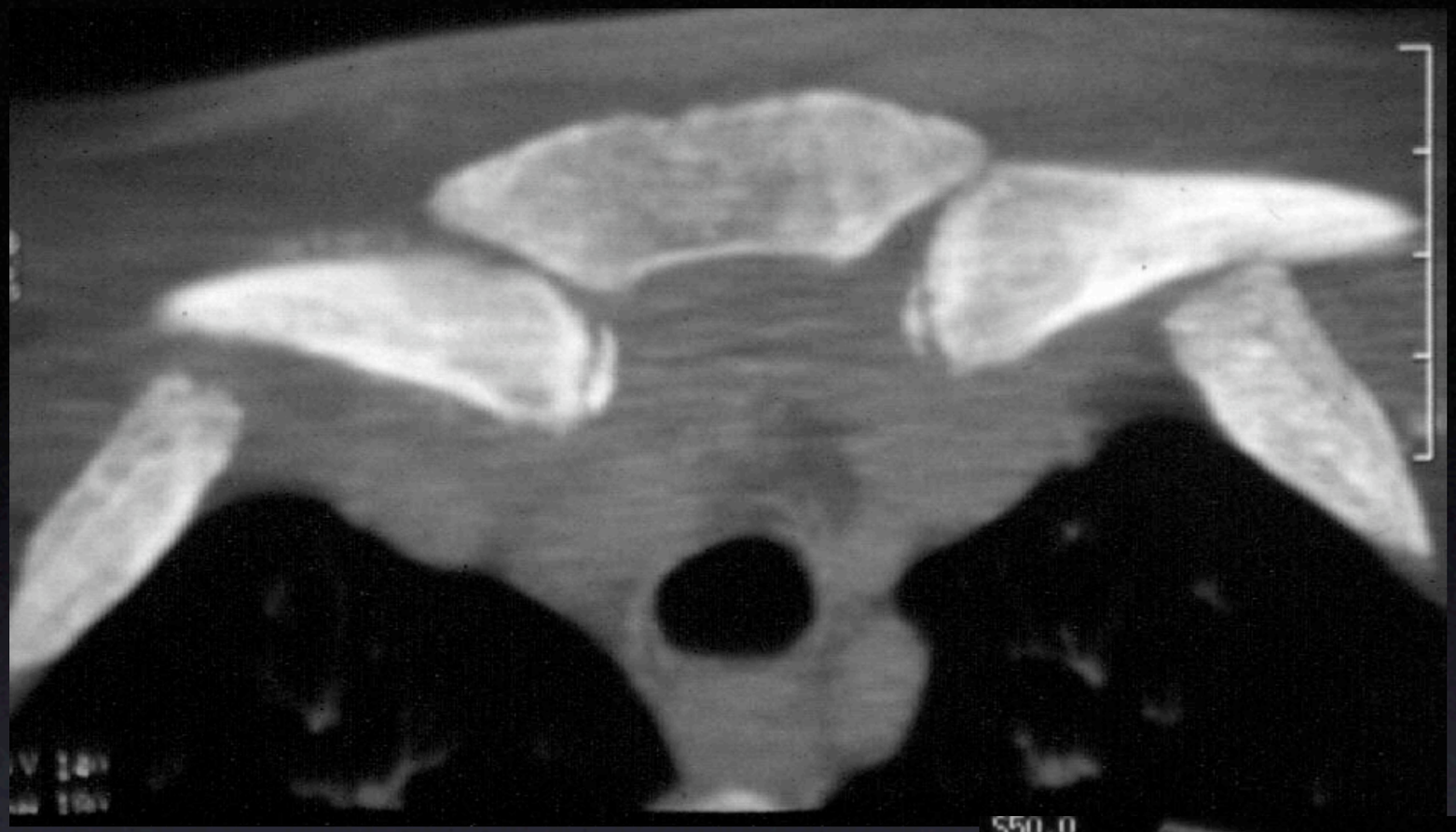

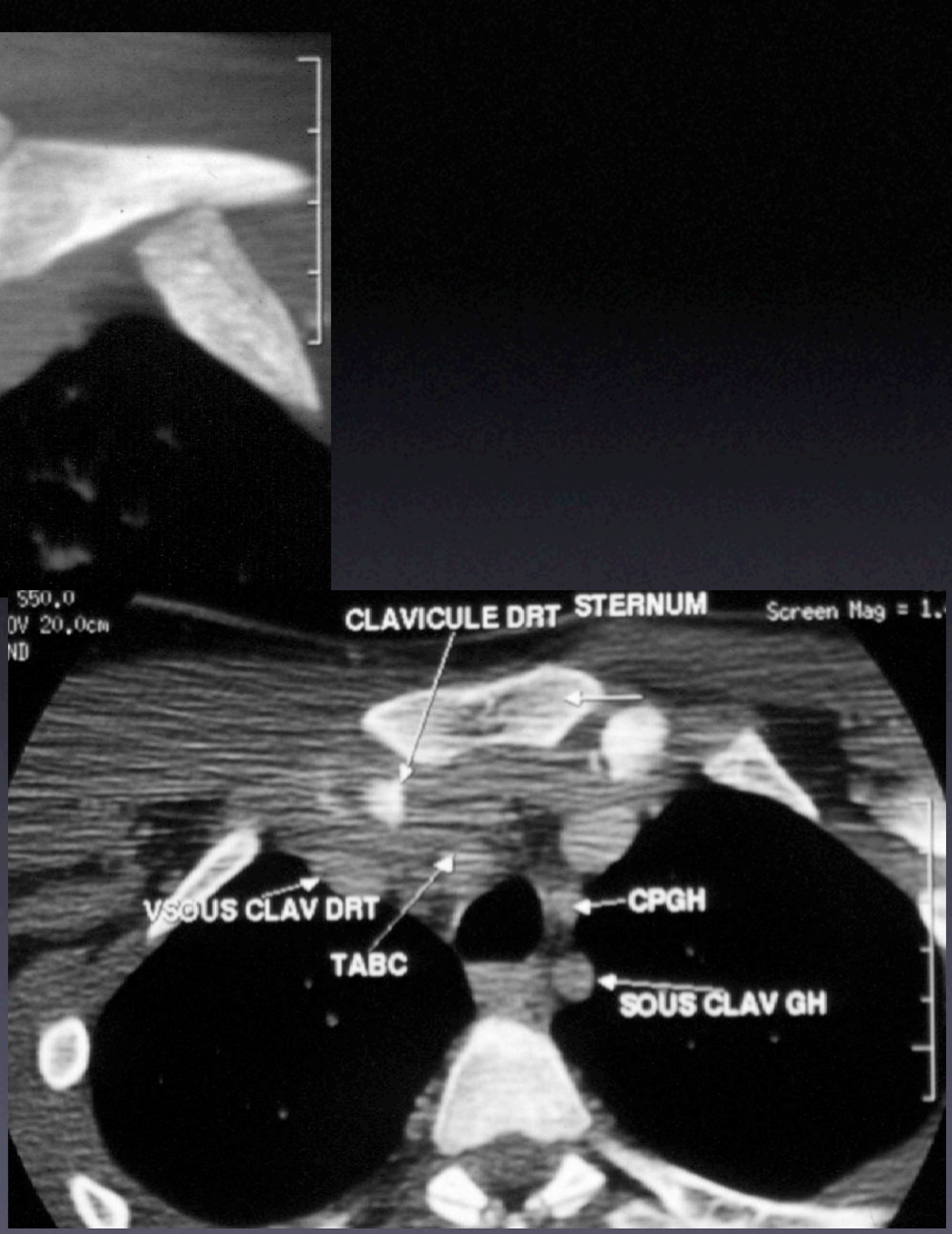
550.0
0V 20.0cm
ND
CLAVICULE DRT
STERNUM
Screen Mag = 1.
VSOUS CLAV DRT
TABC
CPGH
SOUS CLAV GH

Conduite à tenir

- Au bloc opératoire
- Avec un chirurgien vasculaire
- Réduction orthopédique possible dans les 48 premières heures
- Immobilisation 4-6 semaines dans des anneaux

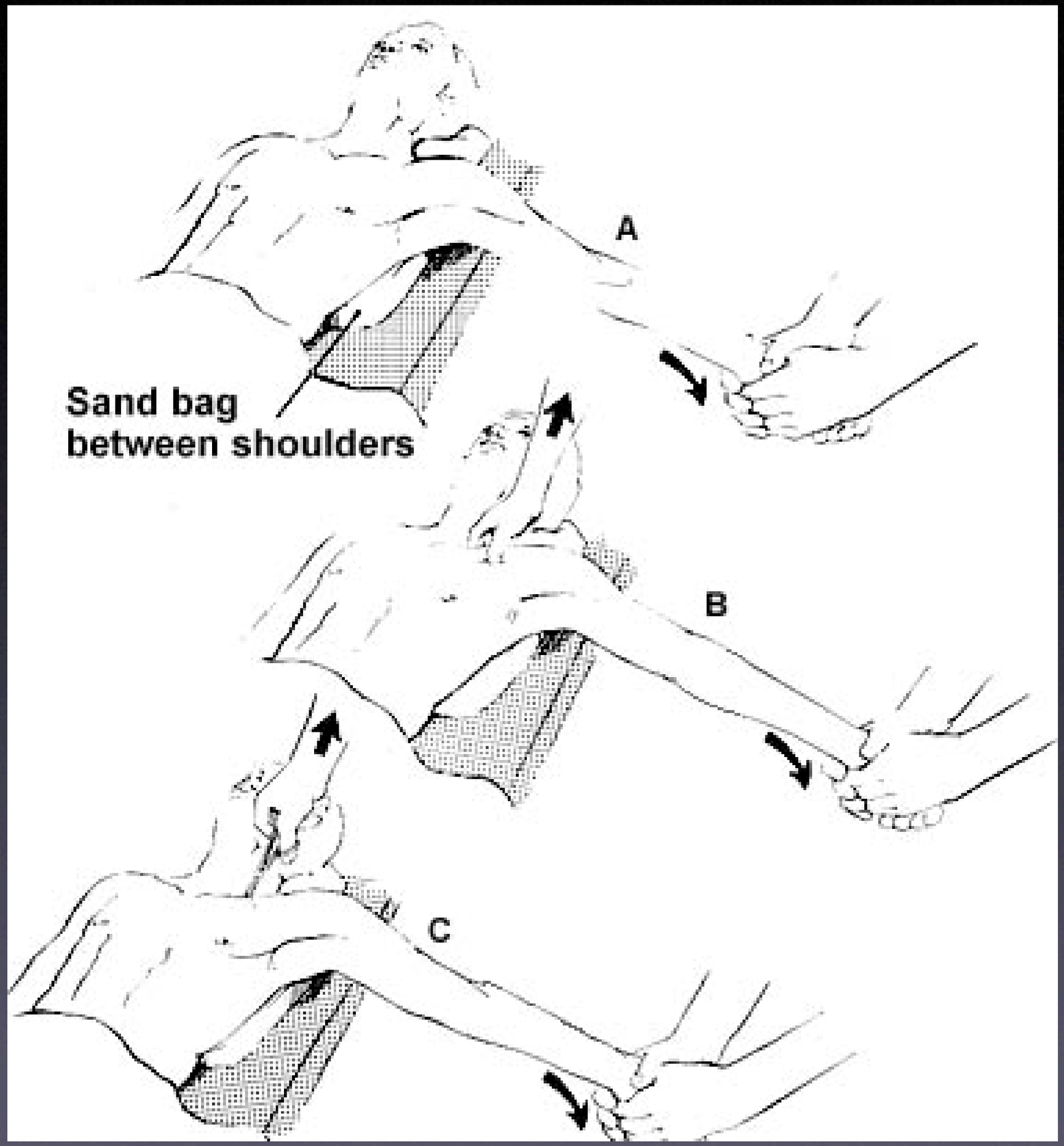
A
Sand bag
between shoulders
B
C

Luxations antérieures

- Plus fréquentes
- Pas de risque vital
- Réduction facile mais instable après réduction
  - Chirurgie secondaire si gène

Exemples de luxations antérieures vues secondairement

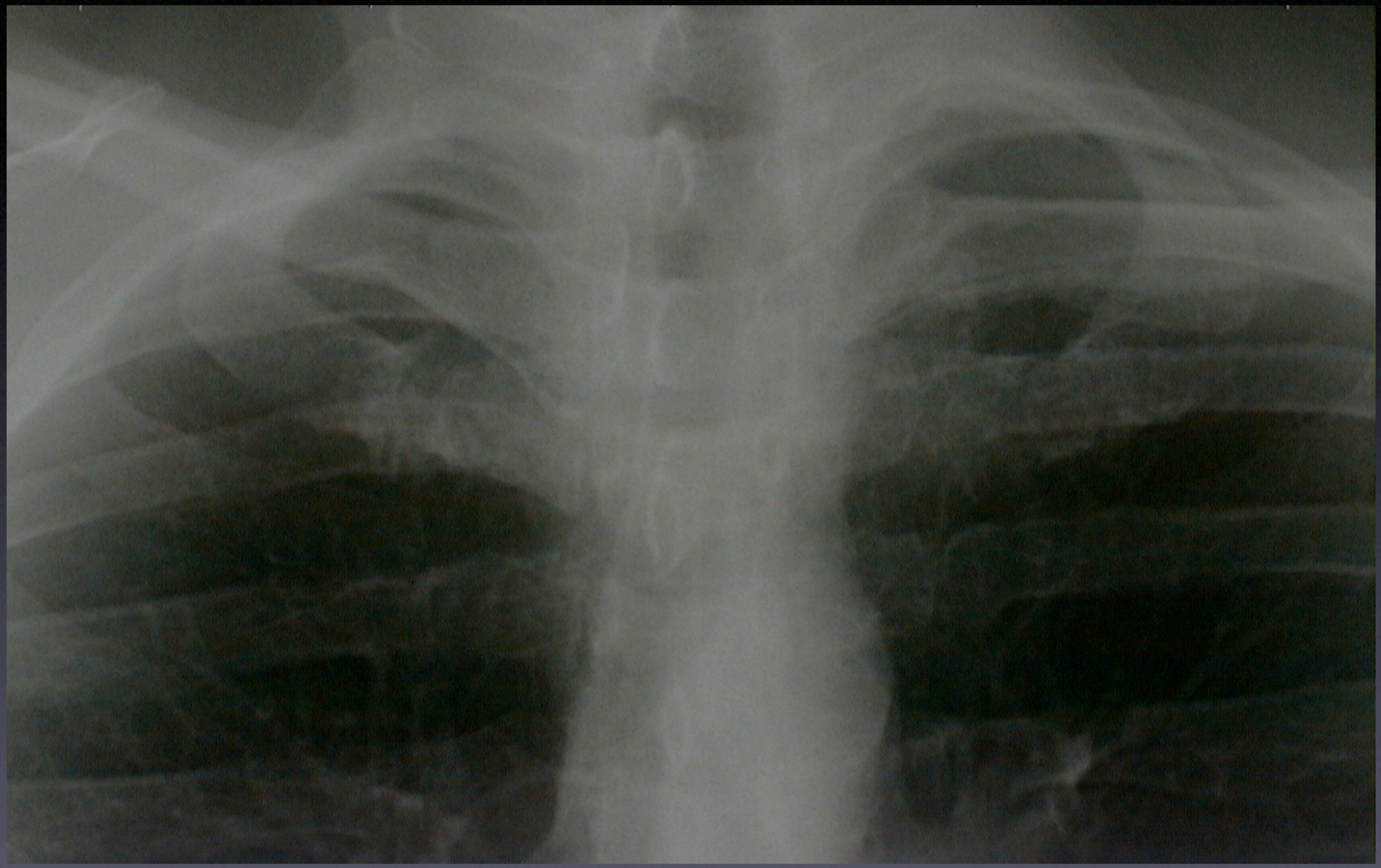

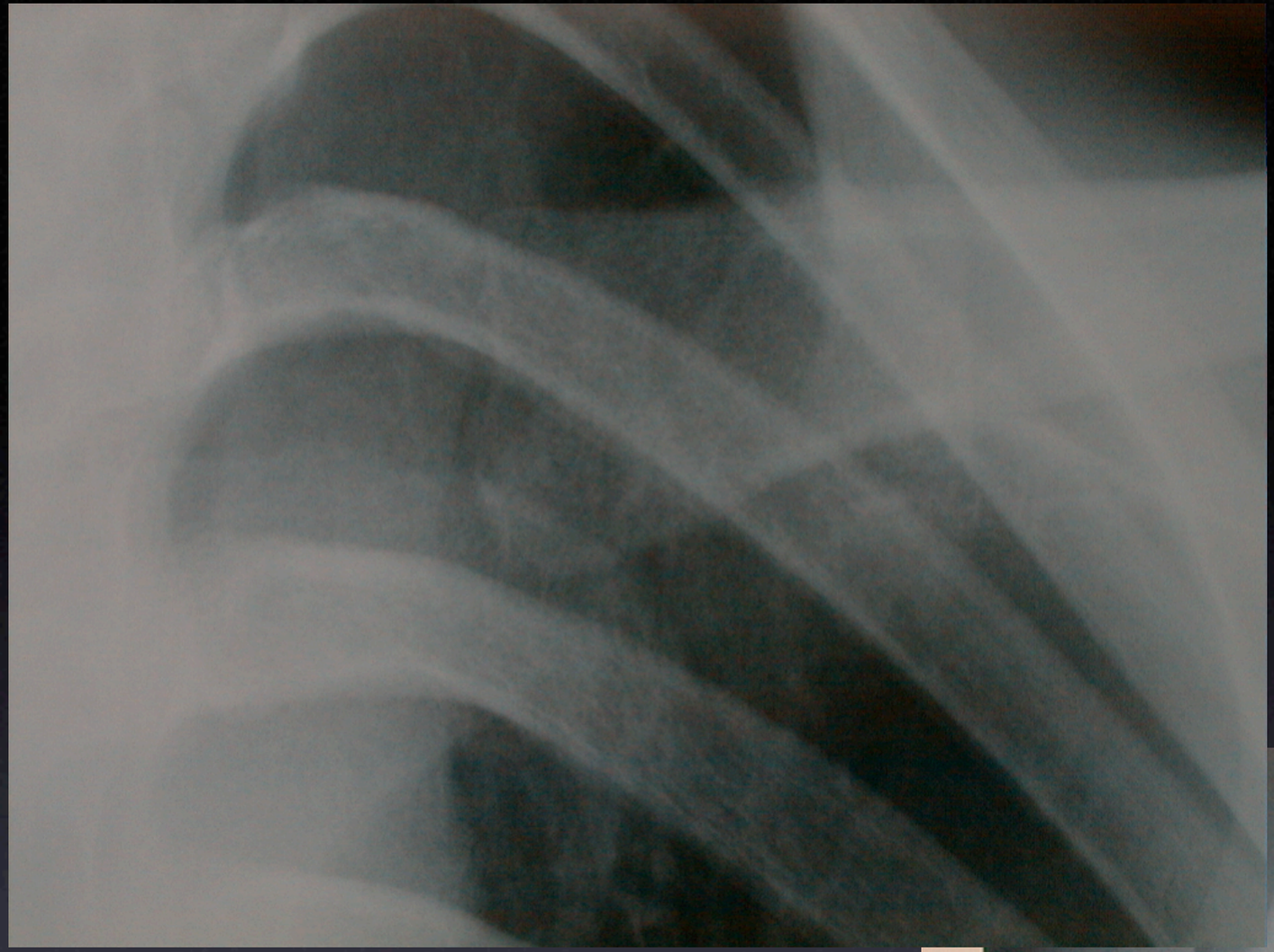

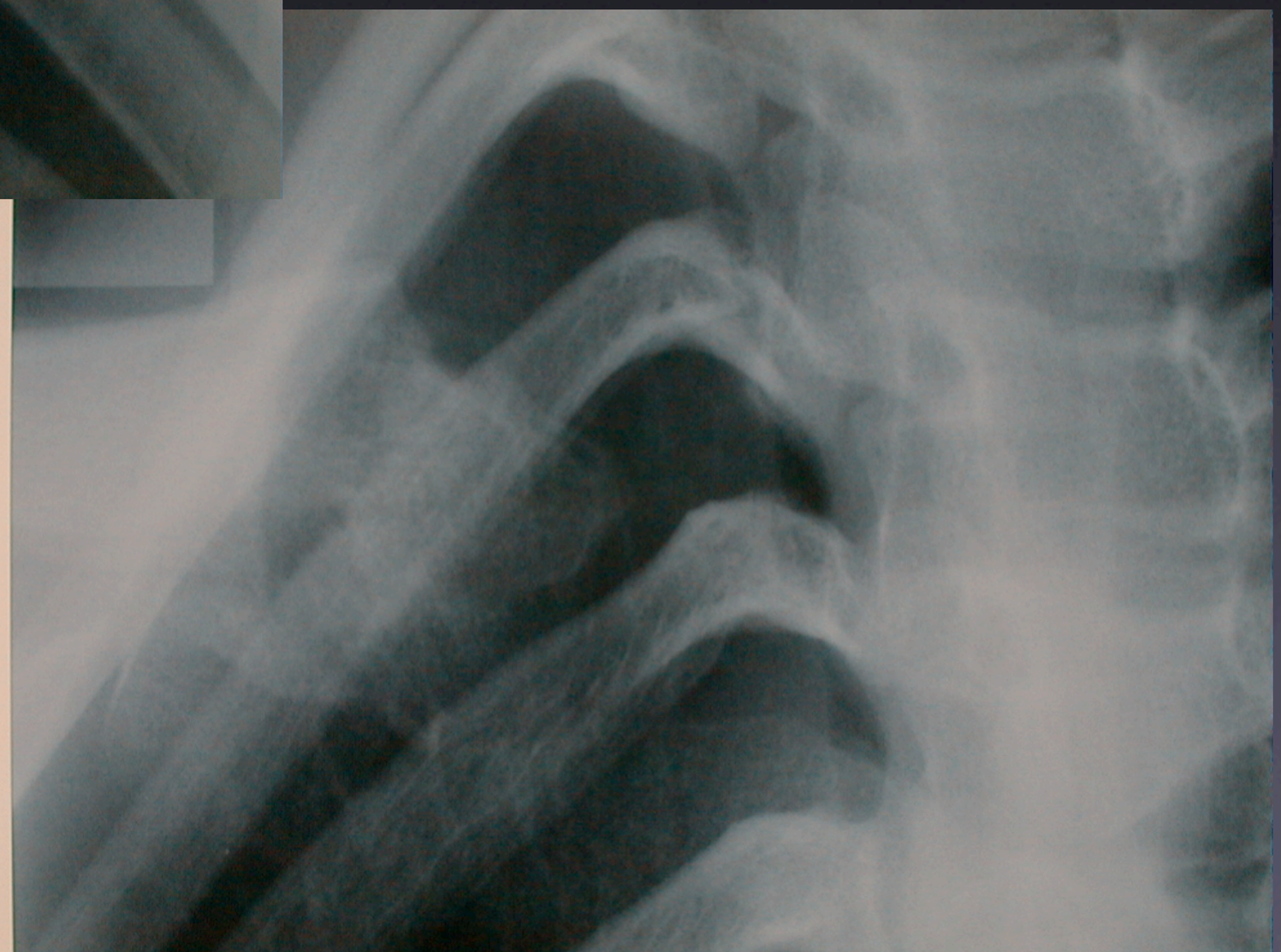

Chirurgie de la sterno-claviculaire

- Incision antérieure
- Repérage premier de l'interligne
- Repérage et excision du ménisque
- Respect du muscle subclavius

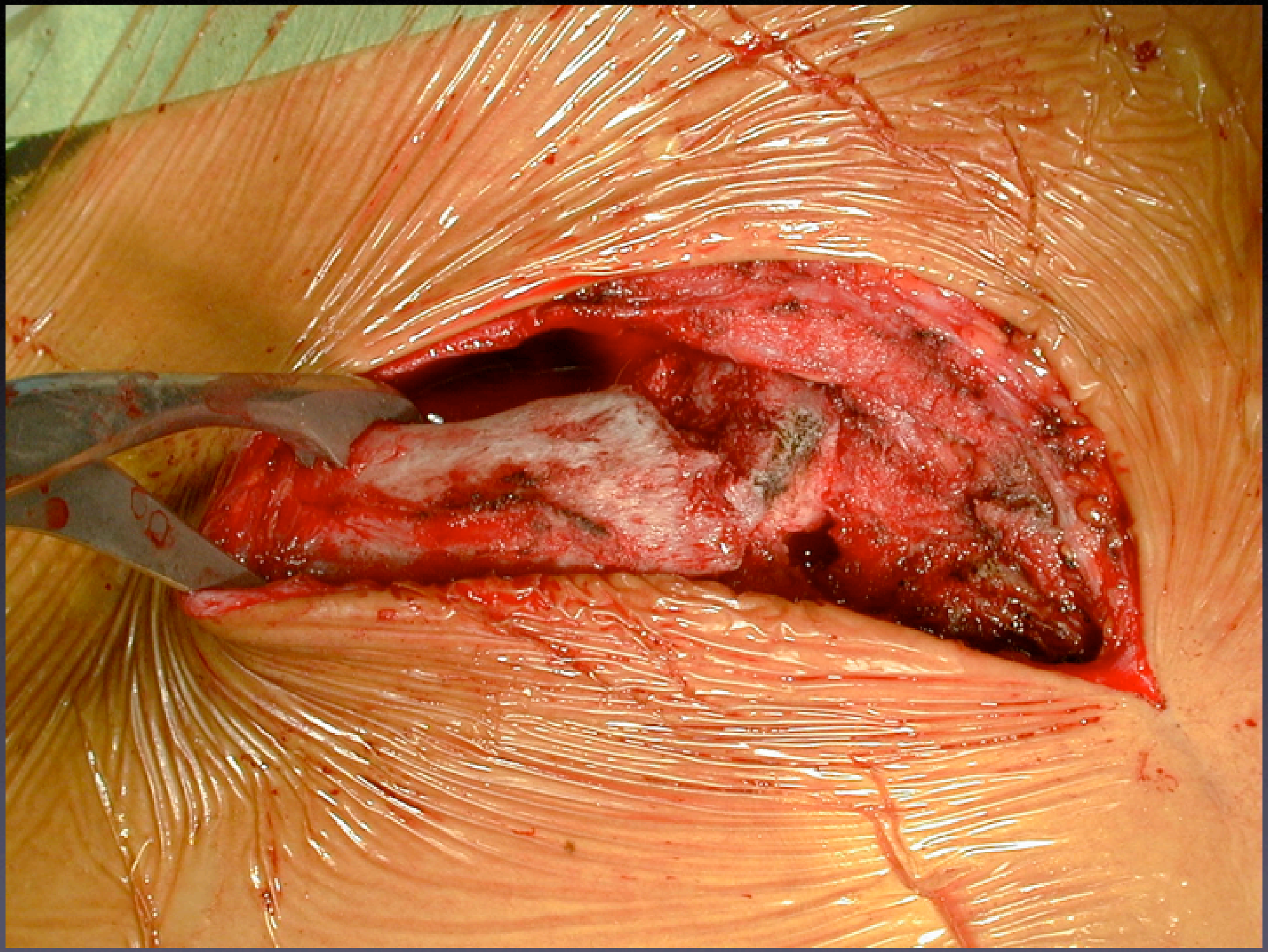

Stabilisation

- Avec ou sans résection du 1/4 interne
- Avec le tendon du subclavius (Jackson-Burrows)
- Avec une greffe tendineuse (Fascia lata, palmaris longus) ou artificielle

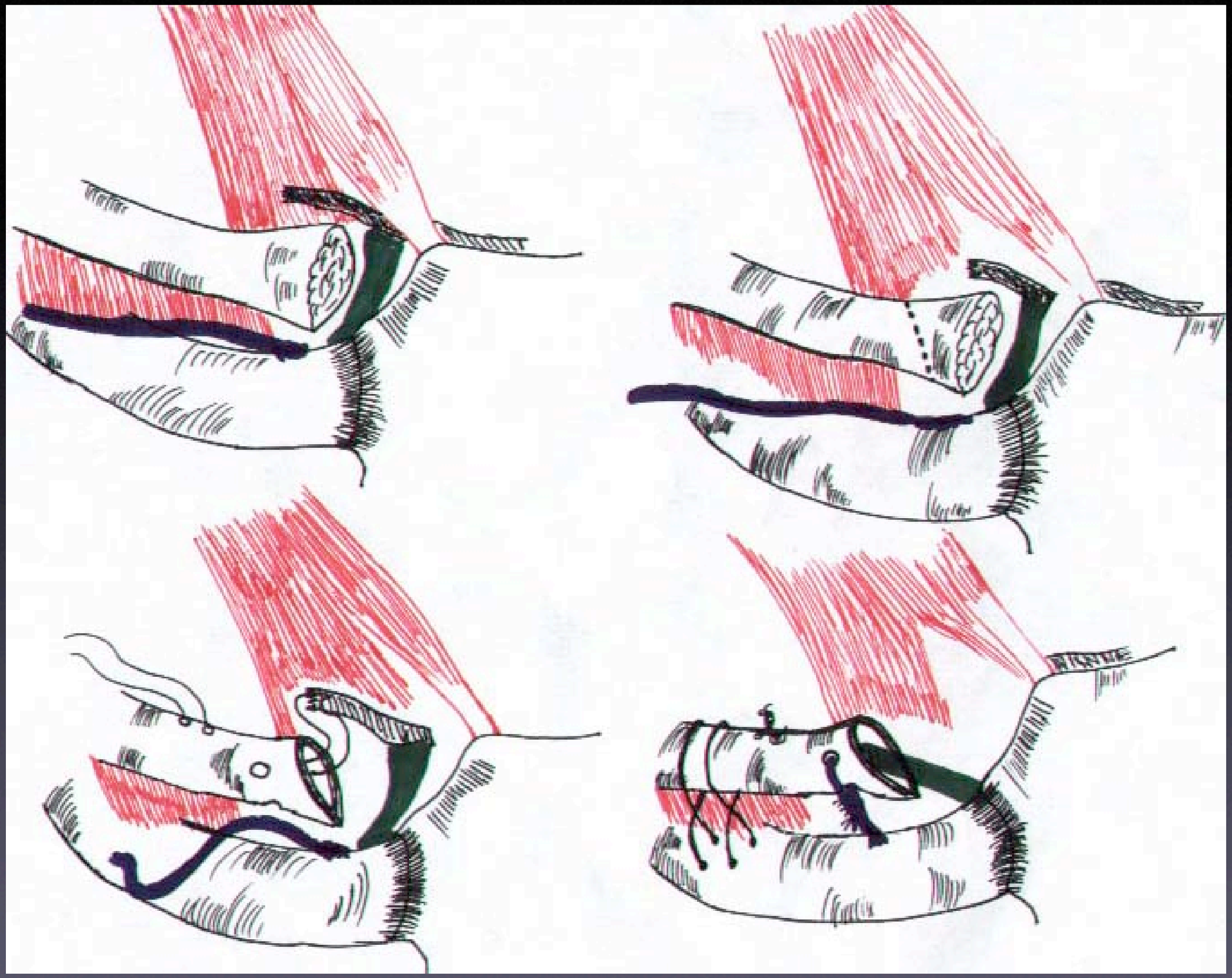

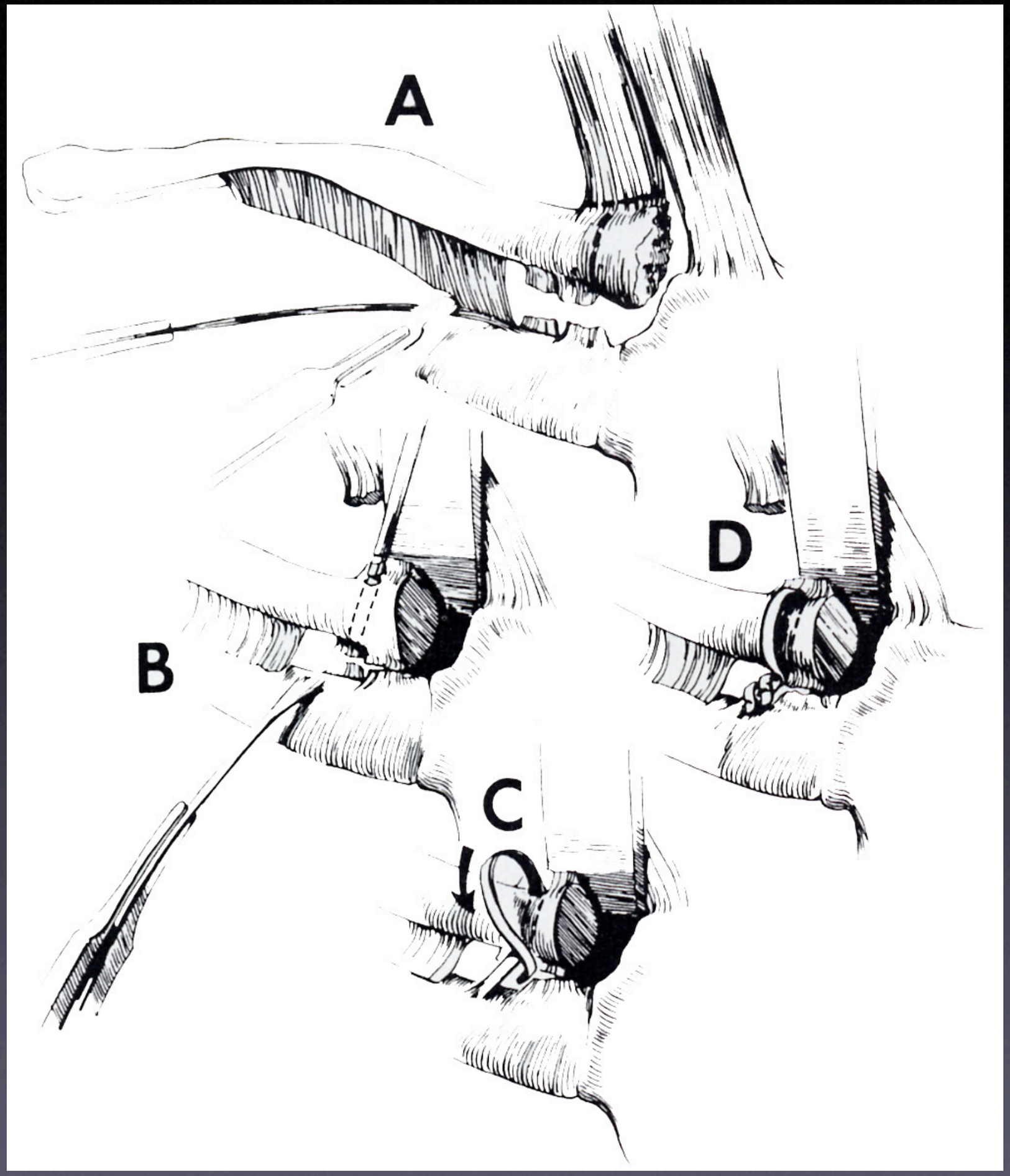
A
B
C
D

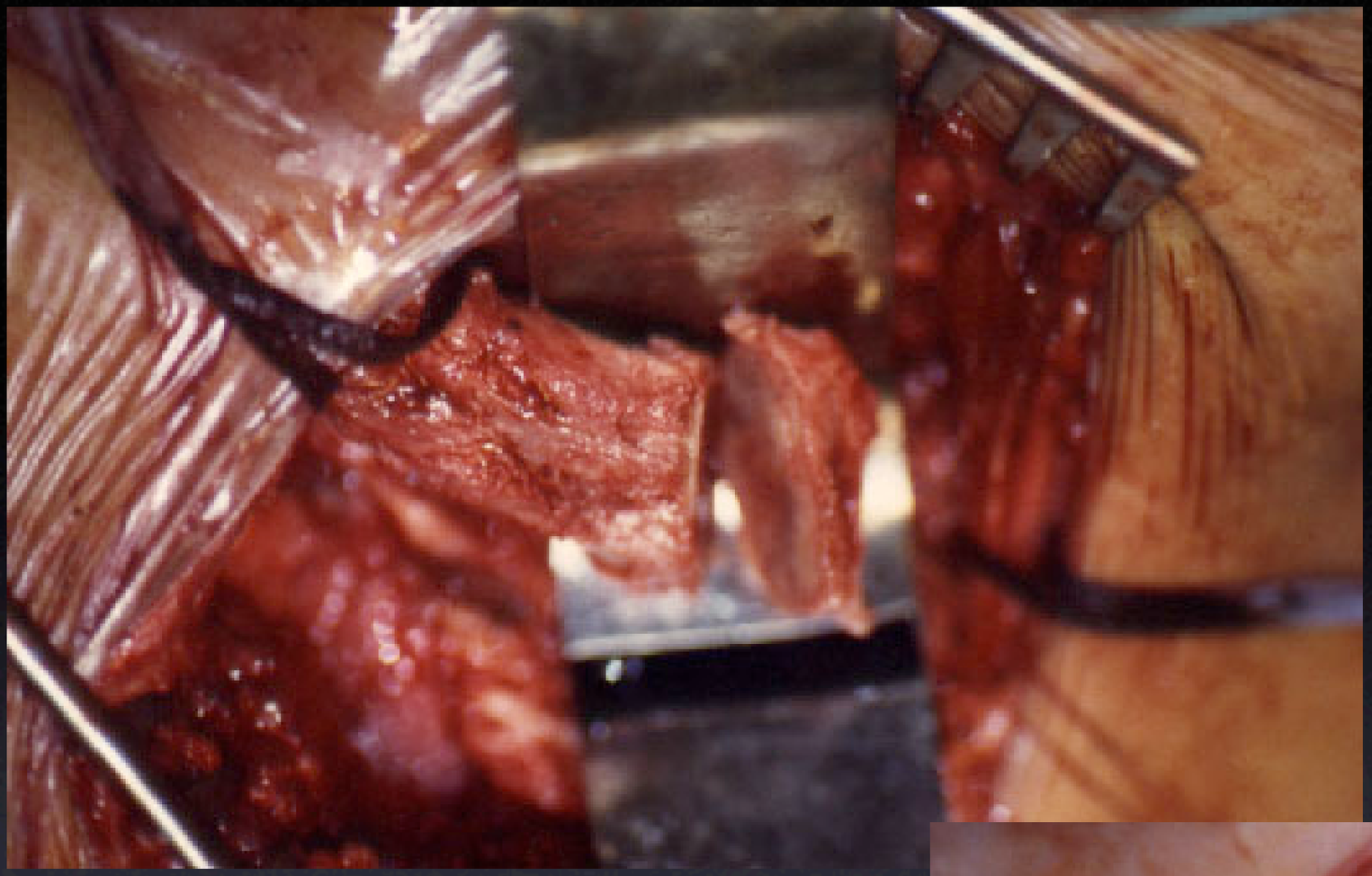

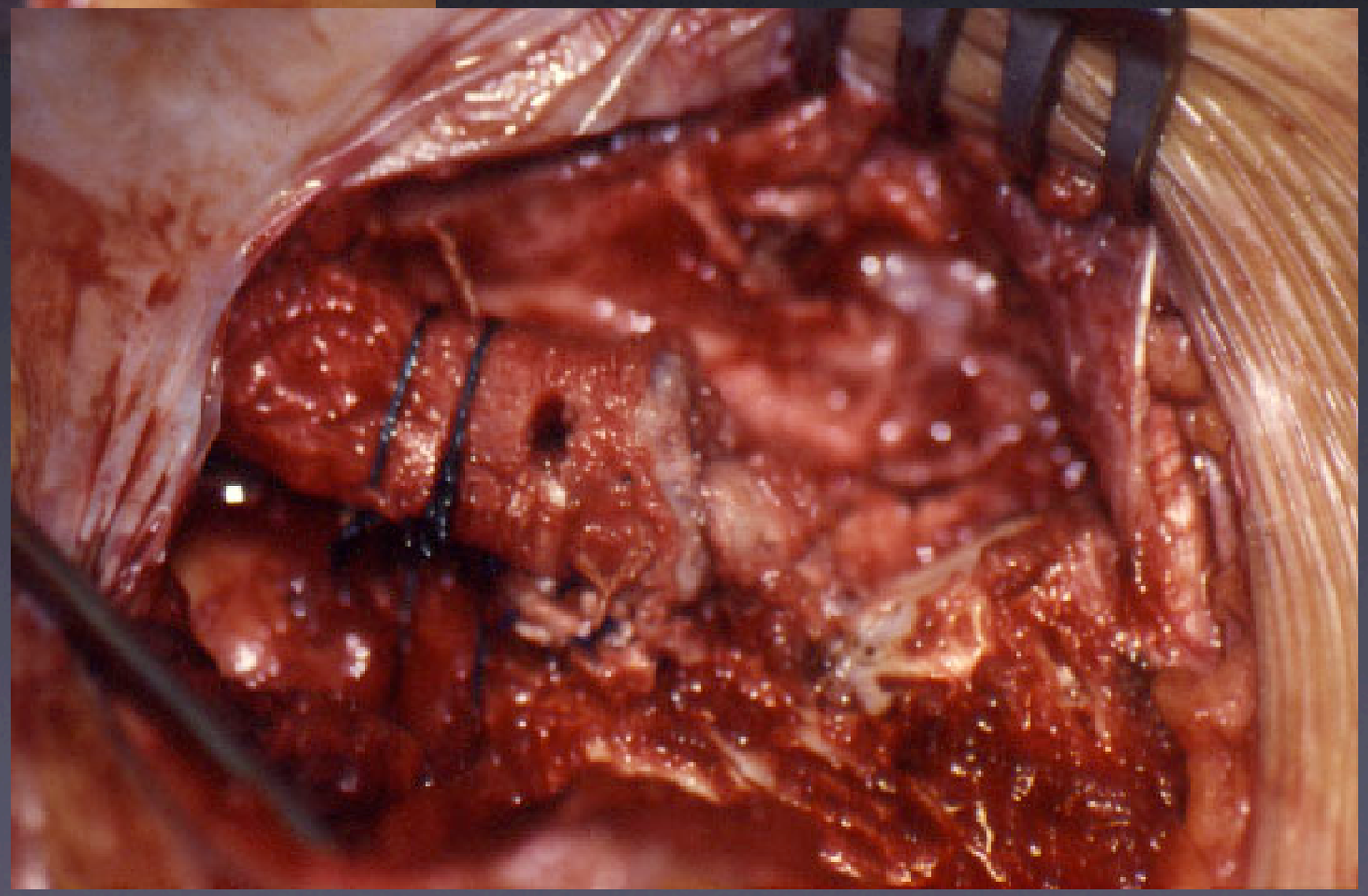

Im: 8
SN O A62.2 (coi)
DFOV 15.5cm
BONE
M41Y/May 12 1963
4054
May 14 2004
02:02:14 PM
512 X 512
Mag = 2.31
FL:
ROT:
R
L
kV 140
mA 300
SFOV 50.0cm
0.30mm 13.75mm/rot 1.375:1 /1i

50.0cm
13.75mm/rot 1.375:1 /1i

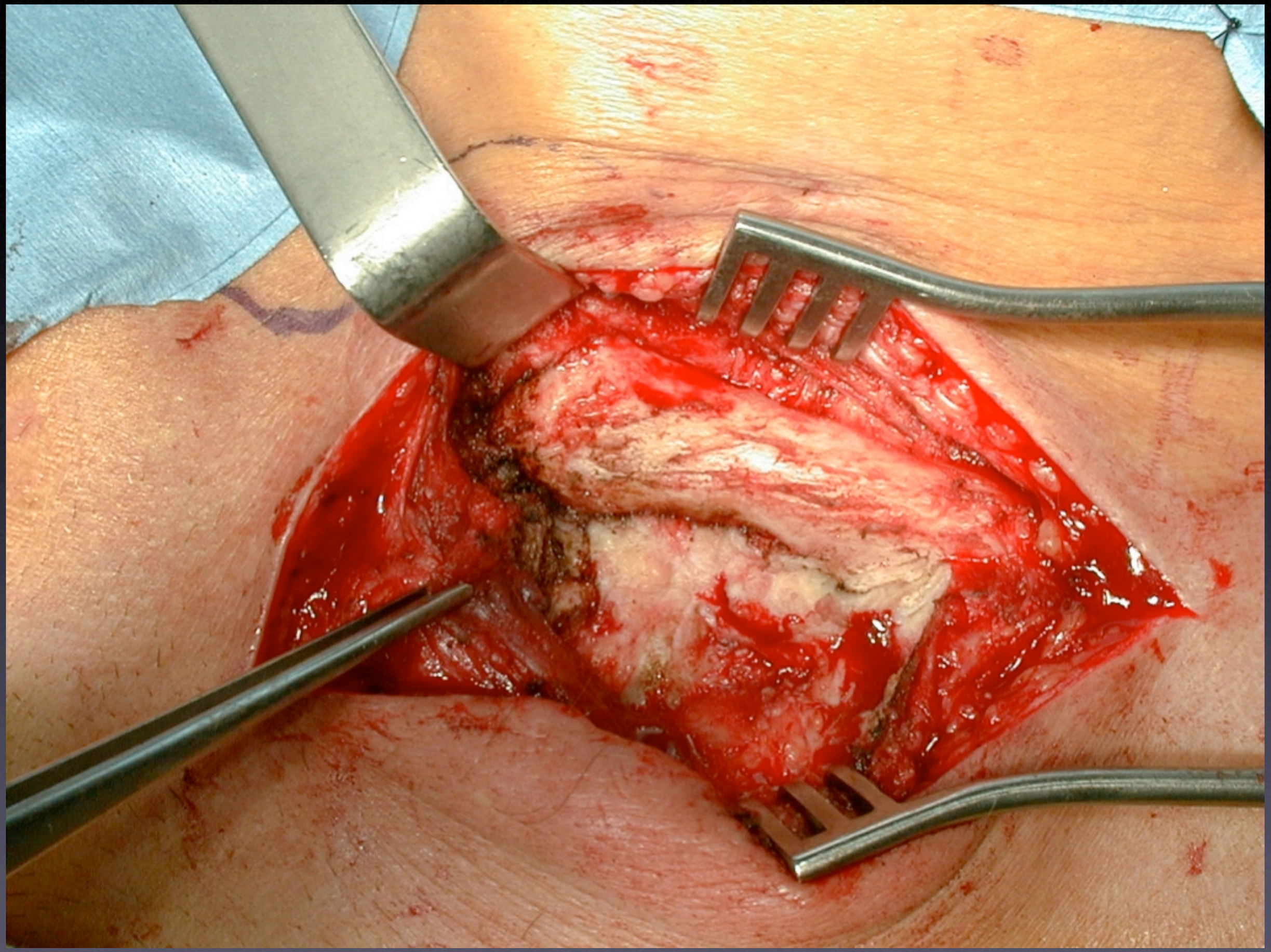

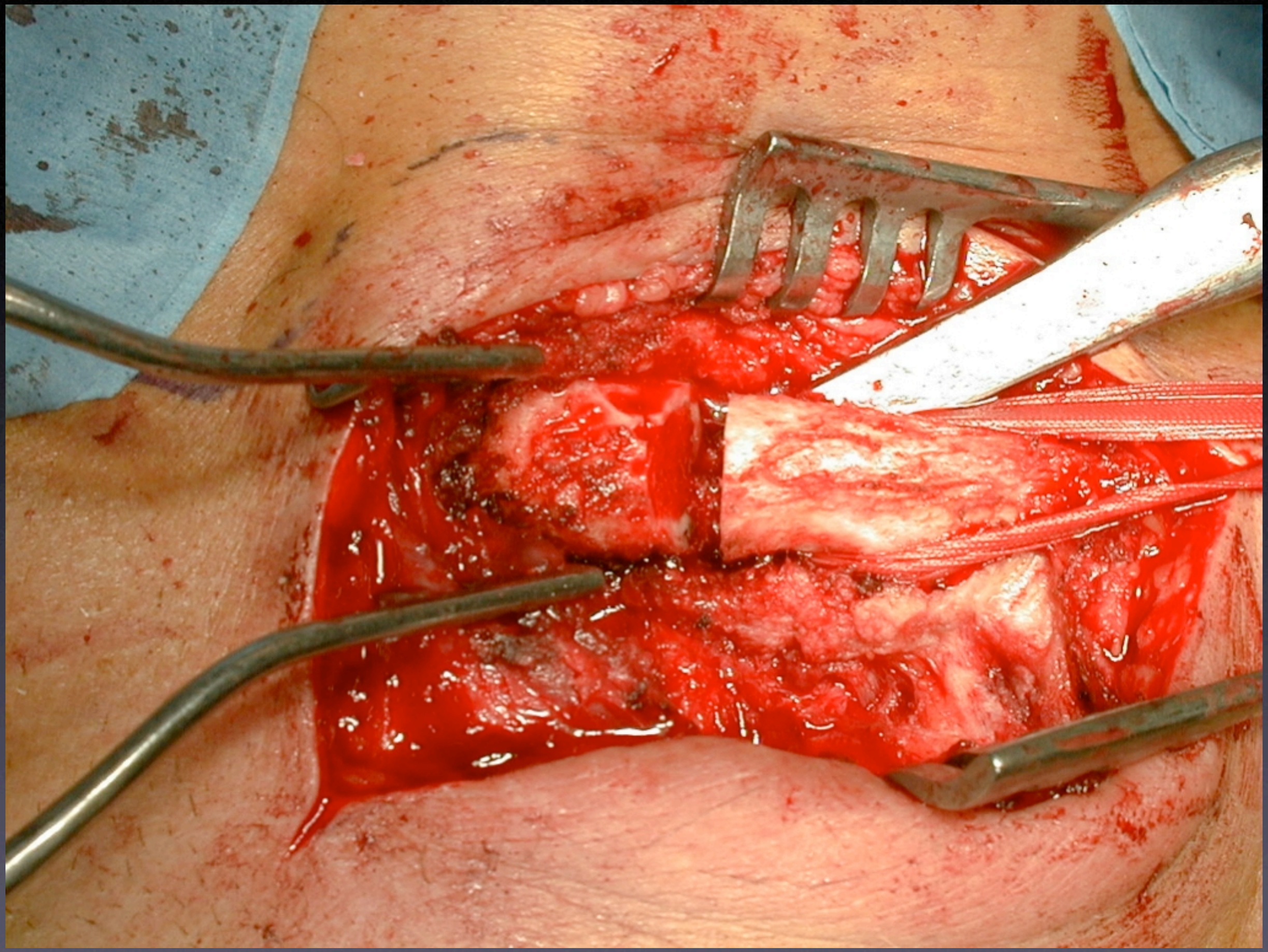

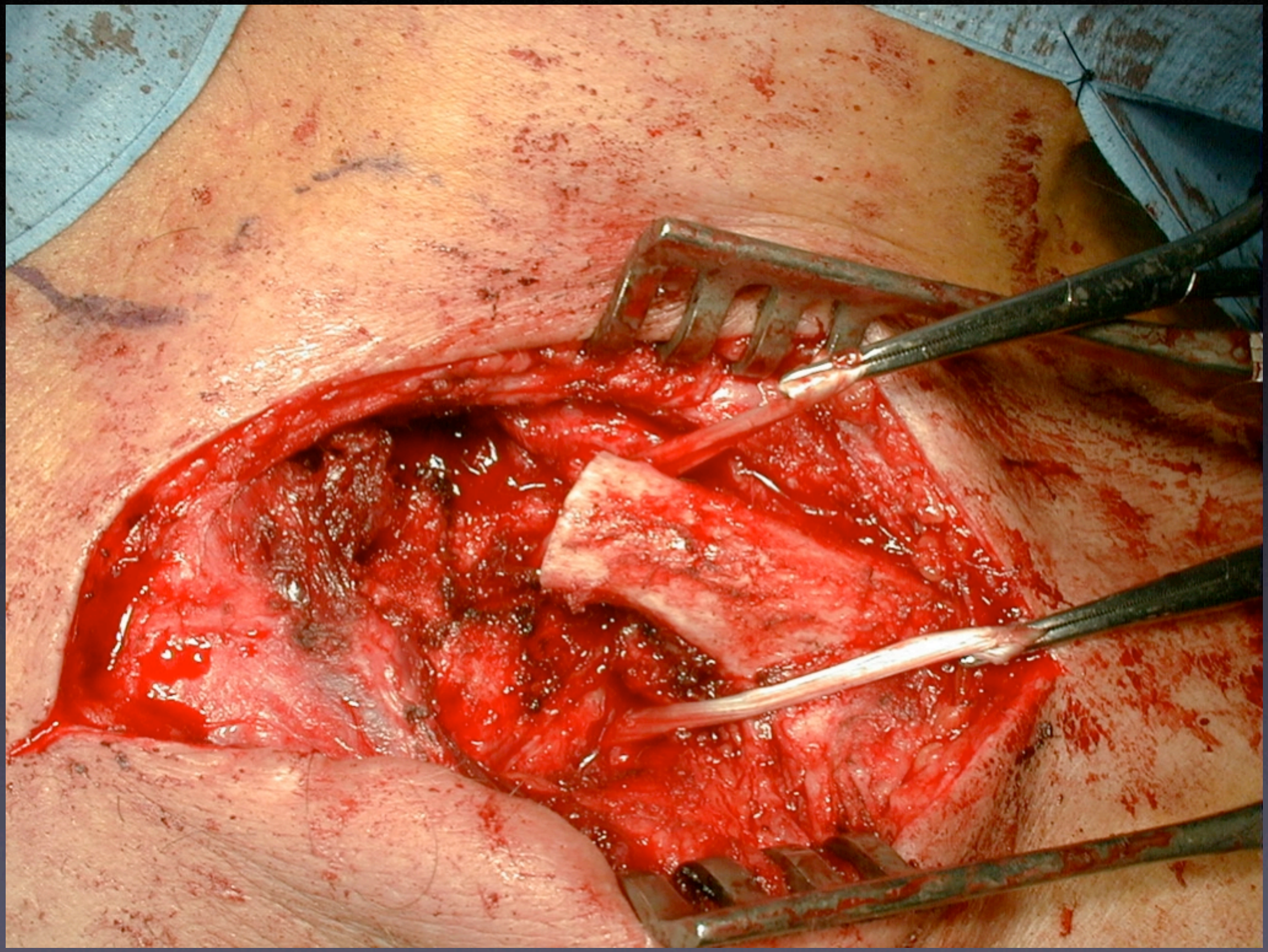

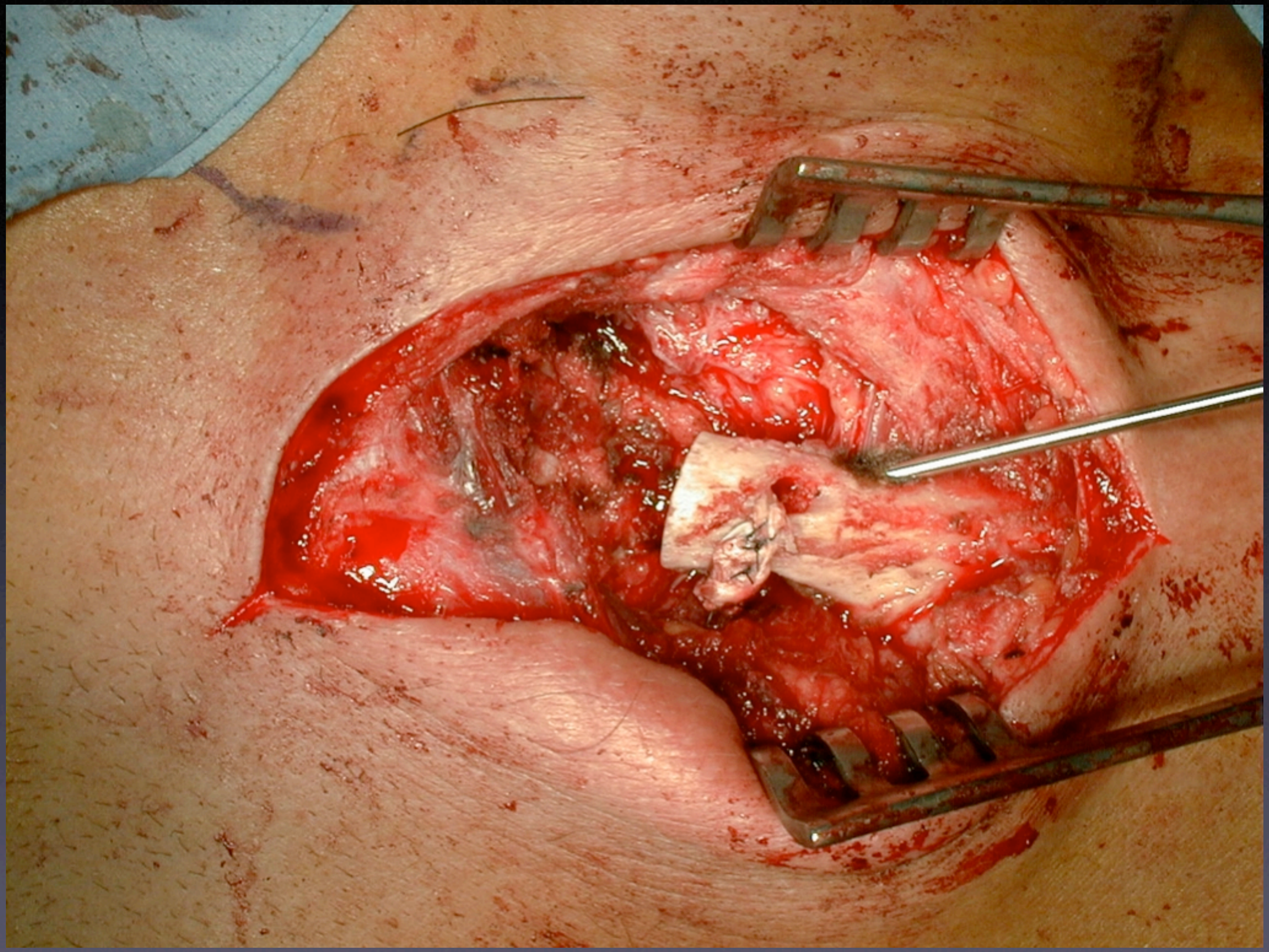

Conclusion

- Pathologie rare (moins que les luxations postérieures d'épaule)
- Principes chirurgicaux simples
- Ne pas les méconnaître !